

Short-coupled premature ventricular contractions triggering malignant arrhythmias

Margarita Dorantes Sánchez[✉], MD; Elio Ponce Paredes, MD; and Roylán Falcón Rodríguez, MD

Department of Arrhythmia and Cardiac Pacing. Instituto de Cardiología y Cirugía Cardiovascular. Havana, Cuba.

Este artículo también está disponible en español

ARTICLE INFORMATION

Received: August 11, 2016
Accepted: September 6, 2016

Competing interests

The authors declare no competing interests

Acronyms

AD: antiarrhythmic drugs
ICD: Implantable cardioverter-defibrillator
IVF: idiopathic ventricular fibrillation
MVA: malignant ventricular arrhythmias
PVC: Premature ventricular contractions
SC-PVC: Short-coupled premature ventricular contractions
SD: sudden death
VF: ventricular fibrillation

On-Line Versions:
Spanish - English

✉ M Dorantes Sánchez
Servicio de Arritmias y Estimulación Cardíaca. Instituto de Cardiología y Cirugía Cardiovascular.
17 N° 702, Vedado, CP 10400. Plaza de la Revolución. La Habana, Cuba.
E-mail address:
dorantes@infomed.sld.cu

ABSTRACT

Introduction: Some malignant ventricular arrhythmias are triggered by short-coupled ventricular premature contractions.

Objective: To characterize patients with syncopal events or sudden death due to malignant ventricular arrhythmias triggered by this type of premature complexes.

Method: There were studied 29 subjects, 16 women and 13 men, with an average age of 38, with and without structural heart disease, whether they received or not antiarrhythmic drugs, with events of sudden or syncopal death from malignant arrhythmias triggered by short-coupled ventricular premature contractions. Clinical history, electrical sequences, echocardiogram, telemetry, ergometry, coronary angiography, pharmacological tests, and programmed electrical stimulation were evaluated, if necessary.

Results: The most common presentation of sudden death was of 89.6%. Ventricular fibrillation was the most frequent arrhythmia (20 events), followed by helical ventricular tachycardia and others. The coupling was ultra-short in 59.4% and short in 40.6%. In 61.5%, sudden death events were triggered by ultra-short premature ventricular complexes, after that, they are considered high risk. The treatments were the cardioverter-defibrillator, antiarrhythmic drugs or their suppression, and others. There were two deaths, both without cardioverter.

Conclusions: Short-coupled ventricular premature contractions are premonitory electrical markers and trigger of malignant ventricular arrhythmias and sudden death in patients with and without structural heart disease. The lower the degree of coupling, the greater the frequency of malignant arrhythmias and sudden death. This is an important factor for the risk stratification of premature ventricular complexes, but it is not the only one.

Key words: Premature ventricular complexes, Short-coupled ventricular premature contractions, Malignant ventricular arrhythmia, Ventricular fibrillation, Cardiac sudden death, Electrocardiographic risk markers

Extrasístoles ventriculares con intervalo corto de acoplamiento como detonantes de arritmias malignas

RESUMEN

Introducción: Algunas arritmias ventriculares malignas son desencadenadas por extrasístoles ventriculares con intervalo corto de acoplamiento.

Objetivo: Caracterizar los pacientes con eventos de muerte súbita o sincopales por arritmias ventriculares malignas desencadenadas por este tipo de extrasístoles.

Método: Se estudiaron 29 sujetos, 16 mujeres y 13 hombres, edad promedio 38 años, con y sin cardiopatía estructural, recibieran o no fármacos antiarrítmicos, con eventos de muerte súbita o sincopales por arritmias malignas desencadenadas por extrasístoles ventriculares con intervalo corto de acoplamiento. Se evaluaron, según necesidad, historia clínica, secuencias eléctricas, ecocardiograma, telemetría, prueba de esfuerzo, coronariografía, pruebas farmacológicas, y estimulación eléctrica programada.

Resultados: La presentación más frecuente fue la muerte súbita (89,6%). La fibrilación ventricular fue la arritmia más frecuente (20 eventos), seguida por la taquicardia helicoidal y otras. El acoplamiento fue ultracorto en el 59,4% y corto en el 40,6%. En el 61,5%, los eventos de muerte súbita fueron desencadenados por extrasístoles ultracortas, luego se consideran de alto riesgo. Los tratamientos fueron el cardioversor-desfibrilador, los fármacos antiarrítmicos o su supresión y otros. Hubo dos fallecidos, ambos sin cardioversor.

Conclusiones: Las extrasístoles ventriculares con intervalo corto de acoplamiento son marcadores eléctricos premonitorios y desencadenantes de arritmias ventriculares malignas y de muerte súbita, en pacientes con y sin cardiopatía estructural. A menor grado de acoplamiento, mayor frecuencia de arritmias malignas y de muerte súbita; este es un factor importante para la estratificación de riesgo de las extrasístoles, pero no es el único.

Palabras clave: Complejos ventriculares prematuros, Extrasístole ventricular con intervalo corto de acoplamiento, Arritmia ventricular maligna, Fibrilación ventricular, Muerte súbita, Signos eléctricos premonitorios

INTRODUCTION

Premature ventricular contractions (PVC) are very frequent events in both healthy and diseased population, ranging from benignity to malignity (in the latter case, triggers for malignant ventricular arrhythmias [MVA]). They are frequent and important electrical premonitory signs of MVA, and arrhythmic sudden death (SD) events; the conflict is about differentiating benign from arrhythmogenic ones and knowing which ones should be treated or not, there is no absolute response. There have been attempts to establish PVC value according to their coupling interval, and determine if the degree of precocity has a role in these patients prognosis¹⁻⁴.

The objectives of this research are: to characterize patients with MVA triggered by short-coupled premature ventricular contractions (SC-PVC), to identify their clinical presentation and type of MVA, to determine the precocity of SC-PVC triggering these arrhythmias, and to establish the evolution after the patients' intervention.

METHOD

Research setting

This work was developed in the Arrhythmia and Cardiac Pacing Department from *Instituto de Cardio-*

logía y Cirugía Cardiovascular, Havana, Cuba, a national referral center for the diagnosis and treatment of patients who have presented MVA episodes and those resuscitated from SD events.

Patients

A sample of 29 patients (16 women and 13 men, 38 years average age, minimum age 9 and maximum 67), with MVA triggered by SC-PVC, was taken during a 12-month period.

Inclusion criteria

All subjects with and without demonstrable structural heart disease by conventional methods were included, with and without the use of antiarrhythmic drugs (AD), who presented one or more MVA episodes or SD events triggered by SC-PVC during the period in question.

Evaluation and follow-up

Patients were assessed, as necessary, by clinical history (anamnesis and physical examination), electrical sequences, echocardiogram, telemetry, ergometry, coronary angiography, flecainide, ajmaline or propafenone pharmacological test, and programmed electrical stimulation with standardized department protocols.

MVA episodes or SD events triggered by SC-PVC

were documented and analyzed. Diagnoses and clinical presentation forms (recovered/unrecovered SD, and syncope) were specified. The degree of precocity was determined according to T-wave portion, in which the PVC was recorded (ascending branch, top or descending branch).

T-wave analysis

The descending branch of the T wave was equally divided into three subsegments (initial third, from the top of the T to the beginning of the middle third; middle third, from the end of the initial third to the beginning of the final third; and final third, from the end of the middle third to the end of the descending branch in the isoelectric line).

Treatment and post-intervention follow-up

Appropriate therapeutic measures were taken (implantable cardioverter-defibrillator (ICD), AD, pacemaker, combination of them). Patients' clinical follow-up was carried out by external consultation, according to need.

Ethics

Informed consent was obtained from all patients.

RESULTS

From 29 subjects with MVA triggered by SC-PVC, the diagnosis was of idiopathic ventricular fibrillation (IVF) in 10; long QT syndrome in 6; Brugada syndrome, ventricular flutter, idiopathic ventricular tachycardia and AD proarrhythmia, 2 in each entity; and variant of short-coupled helical ventricular tachycardia, sinoatrial dysfunction, left bundle branch block and myocardial infarction, 1 in each entity. A patient without structural heart disease had no other diagnosis (**Figure 1**).

Twenty eight patients had a healthy heart and 1 had ischemic heart disease (myocardial infarction and apical left ventricular aneurysm). SD was the most frequent form of clinical presentation (26 events, 25 recovered and 1 non-aborted). There were 6 syncopal events (3 patients had more than one clinical presentation, SD and syncope); one patient had 2 SD episodes, one aborted and the other caused death.

Ventricular fibrillation (VF) was the most frequent arrhythmia (20 events), followed by helical (12) and ventricular (5) tachycardia, and ventricular flutter (2). Repetitive ventricular responses were

documented in 3 patients. Some patients had more than one arrhythmia (n=39) (**Figure 2**).

SC-PVCs were enrolled in some portion of the preceding T wave as triggers for MVA episodes (except in 1 case where there were only repetitive ventricular responses). The most frequent location of SC-PVC registration was the top of the T wave in 10 tracings, ascending branch in 9, initial third of descending branch in 8, average third in 4, and final third in 1. There was more than one inscription location of SC-PVC in 3 patients (n=32) (**Figure 3**).

ICD implantation was the most frequent treatment

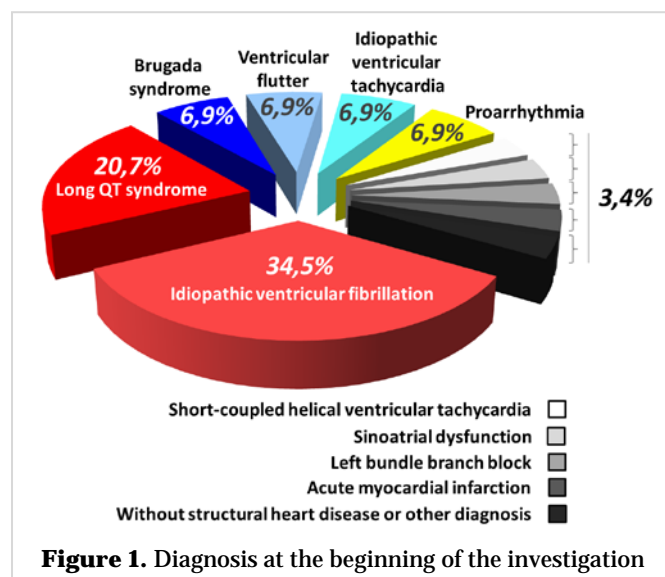


Figure 1. Diagnosis at the beginning of the investigation

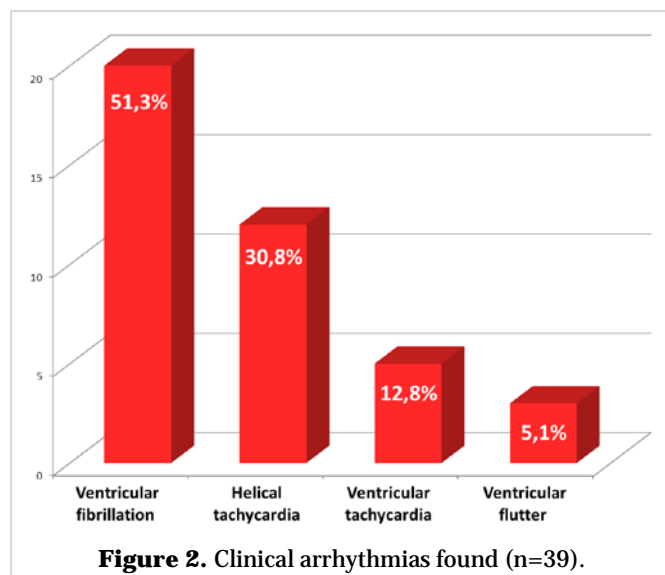
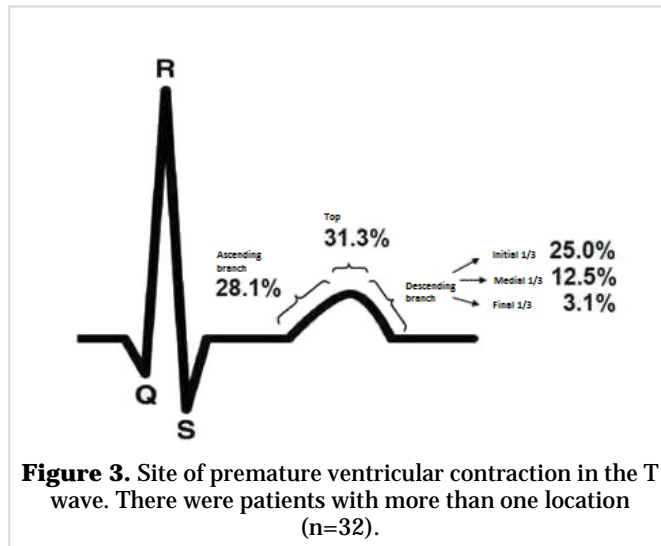


Figure 2. Clinical arrhythmias found (n=39).

(18 patients), use of AD (7), permanent pacemaker associated with beta-blockers (4) and AD cessation (2). There were patients with more than one therapy (n=31). During follow-up two patients died due to VF and non-resuscitated cardiac arrest, both without ICD.



DISCUSSION

Frequent PVCs have been associated with structural heart disease and increased sudden/total mortality. In the second half of the twentieth century, PVCs^{1,2} were recognized as the onset for MVA, which are considered a premonitory electrical sign for MVA and SD. As they can trigger these arrhythmias, it was thought that by decreasing their number (using AD at that time), SD^{3,4} risk would also decrease. Then came the CAST⁵ study that revolutionized all previous ideas (mortality increased in the subgroup with AD) and reached these drugs worst times (because of its proarrhythmic capacity, rising of life-saving ICD and a very successful curative procedure, such as the ablation of arrhythmogenic substrates)⁶⁻⁸. Lindsay⁹ stated that the frequency and complexity of ventricular ectopy are related to MVA risk, but this is not a reliable predictor for sustained MVA in individual patients.

Many PVC are innocent (most will not require treatment), while others can trigger MVA and will

have to be avoided. Therefore there cannot be a conclusive overall response. See the PVC, ¿how many possibilities? Many PVC triggering MVA or not; isolated, causing ventricular arrhythmia or not, and MVA not caused by PVC. It is necessary to have an overall vision at this dilemma: benignity or malignity and need for treatment or not.

The Arrhythmia and Cardiac Pacing Department from *Instituto de Cardiología y Cirugía Cardiovascular*, Havana, Cuba, is the national referral center for patients resuscitated from arrhythmic SD, for their diagnosis, treatment and follow-up and within it: the National Registry of SD in subjects without demonstrable structural heart disease by conventional methods.

Recording VF events and seeing how they start is a great conflict for various reasons: no rescuing from cardiac arrest, non-witnessed out-of-hospital events, self-limiting episodes, urgency allows no place for recording the electrical chart and immediate patient recovery, disregard for opportunities to record what is happening. However, at the Department we have had the opportunity to record these arrhythmogenic events and it has been possible to analyze different and variable VF- electrocardiographic models, as well as its triggering element.

Conflict starts from the very beginning, what is a short-coupling interval? Nogami¹⁰ points out the figure 245±28 ms, Chinushi *et al.*¹¹, 280-300 ms and Cal-lans³, 300 ms. Laurent¹² describes it in another entity and Viskin *et al.*¹³ define a variant with an ultra-short coupling interval (peak of the T) in IVF, Brugada syndrome, and myocardial infarction; and relatively short when located on the descending branch of the T wave.

The place PVC had, regarding ventricular repolarization, was considered in this study (top, or ascending or descending branches of the T), in order to avoid measurement instability in the presence of heart rate changes and other factors. So are classified by Viskin *et al.*¹³.

From the 29 patients in this series (MVA's trigger was SC-PVC in all cases, except for one where there were no MVA but repetitive ventricular responses, in some cases there was more than one location in the preceding T wave (n=32): 10 at its apex, 9 at ascending branch, and 13 at descending branch.

In 16 from the 26 SD cases occurred ultra-short SC-PVC (61.5%), which enables to state that the lower coupling interval, the worse prognosis.

It is necessary to have an overall vision when evaluating PVC threat and whether to treat them or

not. Many, associated with structural heart disease, are related to higher SD and total death incidence; they are related to MVA risks, but are not a reliable predictor for the presentation of these arrhythmias. Coupling interval is not the only factor in itself, there are others: patient type, age, hemodynamic repercussion, structural or non-structural heart disease, ejection fraction, electrolyte or metabolic transient causes, other organ diseases, previous heart rate, PVC's origin location, density in 24 hours, uniform/non-uniform morphology, width, triggering events, QT interval, T amplitude, disease evolution, channelopathy, and AD use^{9,14,15}.

As mentioned, the importance of ventricular ectopy and its causal relationship to MVA induction has been recognized for a long time, but PVC frequency and complexity are related to risk without being a reliable predictor of sustained ventricular arrhythmia for individual patients.

The truth is that PVC can precede VF without triggering it, but may also cause it and lead to isolated episodes or electrical storms: PVC may or not trigger MVA.

SC-PVC can trigger MVA (helical tachycardia and

VF) in several clinical situations: structural heart disease, IVF, catecholamine polymorphic ventricular tachycardia, variant of short-coupled helical tachycardia, J wave, long QT, short QT, and Brugada syndromes^{12,16,17}.

Subjects with no demonstrable structural heart disease (long QT and Brugada syndromes, IVF, and others) predominated in this study, which is not considered significant because it depends on our sample (mainly patients from the National Registry of SD in subjects without demonstrable structural heart disease by conventional methods) and, therefore, inapplicable to other series. There was a patient with a healthy heart, who presented frequent recurrent syncope and SC-PVC causing repetitive ventricular arrhythmias. No MVA were documented or triggered in programmed electrical stimulation.

The predominant arrhythmia was VF, followed by helical tachycardia, ventricular tachycardia, ventricular flutter and repetitive ventricular responses, there were also patients with more than one arrhythmia. All MVA were triggered by SC-PVC. SD was the most frequent clinical presentation in 26 patients (25 recovered, 1 unrecovered, one patient was resusci-

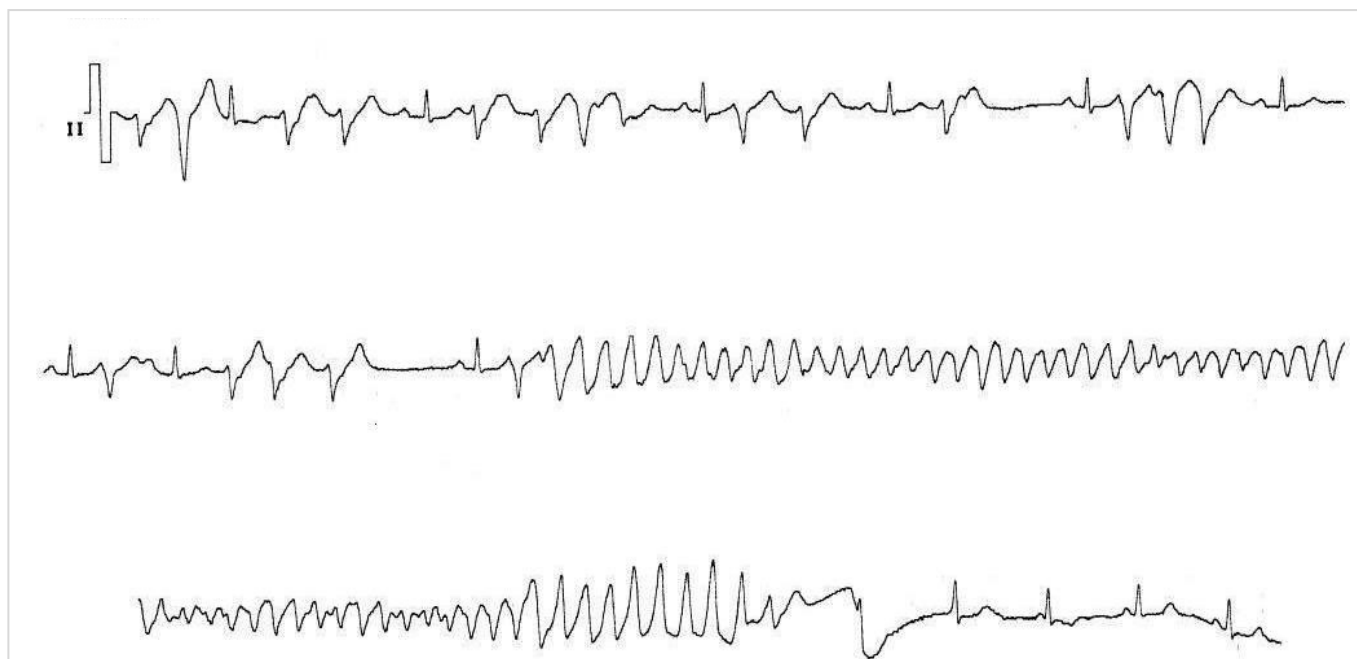

Figure 4. Patient without demonstrable structural heart disease by conventional methods, normal basal electrocardiogram, and family history of several sudden deaths. Short-coupled premature ventricular contractions with various precocity degrees are observed. Repetitive ventricular responses and episode of ventricular fibrillation are triggered. She was resuscitated and a cardioverter defibrillator was implanted.

tated from her first episode, not so the second). Some had syncope and SD episodes at different times in their evolution.

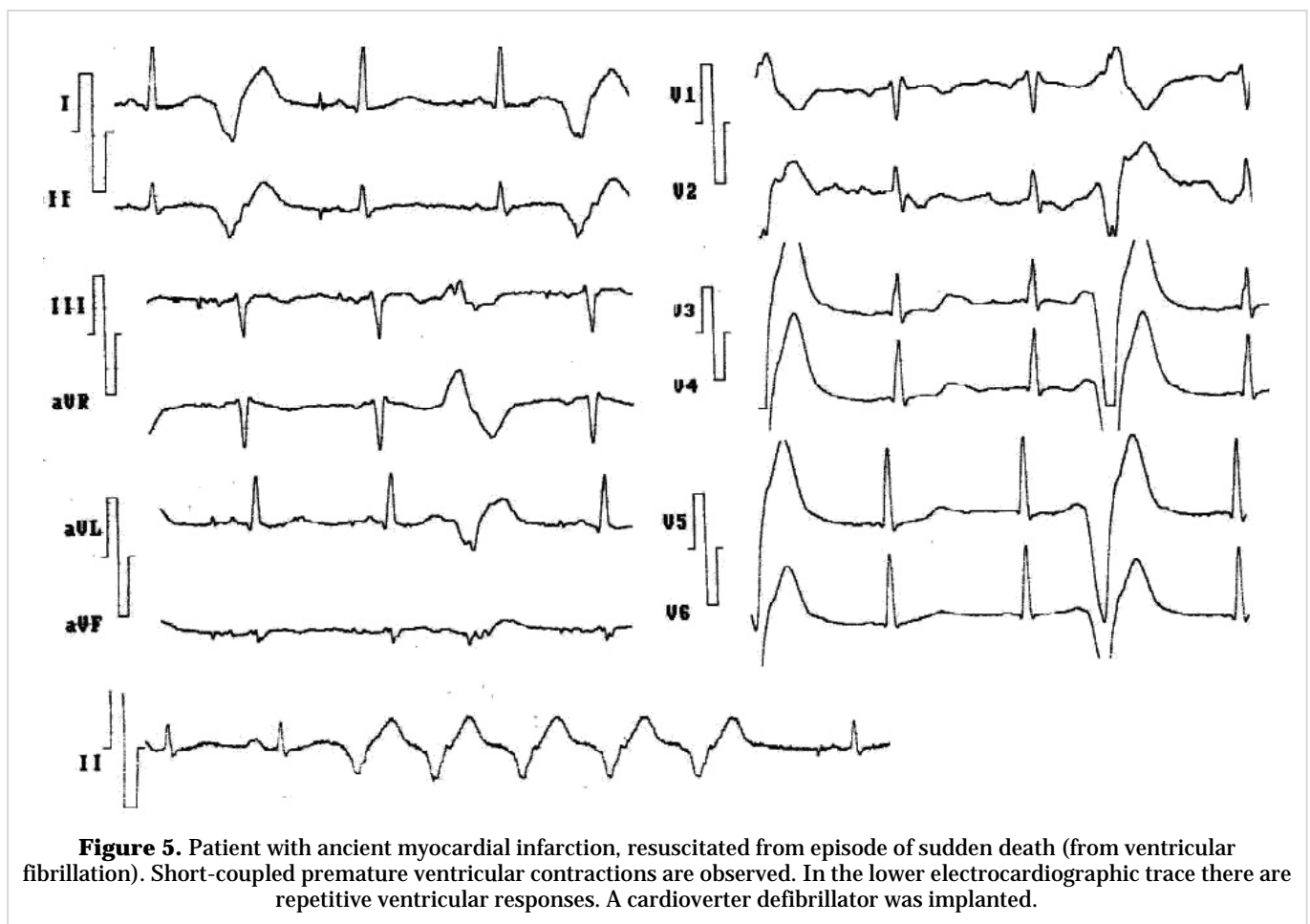
Of course, the most frequently used treatment was ICD, associated or not with AD. Helicoidal tachycardia was more frequent in patients with long QT syndrome (5), followed by other diseases such as familial IVF and IVF (2 in each), and left bundle branch block, proarrhythmia, and short-coupled variant of torsade de pointes (1 in each entity).

Some cases in this series were of particular interest, due to their rarity and electrical sequences, and the onset mode of MVA by SC-PVC (**Figures 4, 5 y 6**).

There were two deaths, one with helical tachycardia and VF recorded in a Holter study, with left bundle branch block as a premonitory sign, who had no time for treatment indication. The other case was the mother of the patient with familial IVF, after a first episode of recovered cardiac arrest, she was not

implanted an ICD but a pacemaker associated with beta-blockers, she survived two years and then presented an unrecovered SD. Her son, with similarities regarding the first event, SC-PVC and type of MVA (helical tachycardia and VF), was recovered from the SD episode and was implanted an ICD, with good evolution, has had recurrences resolved by the device. This is a very rare disease and the similarities between the two patients are striking. There was one patient recovered from SD (helical tachycardia and IVF), with prominent J wave after an external electrical shock, which diminished until disappearing. In the IVF subgroup J wave was observed in 3 cases, in two of them associated with short QT interval. Two cases with SC-PVC triggering MVA because of AD use were striking, because this occurred with amiodarone, the less-proarrhythmogenic antiarrhythmic¹⁸.

In another patient, it was about the specific short-coupled variant of torsade de pointes, triggered by



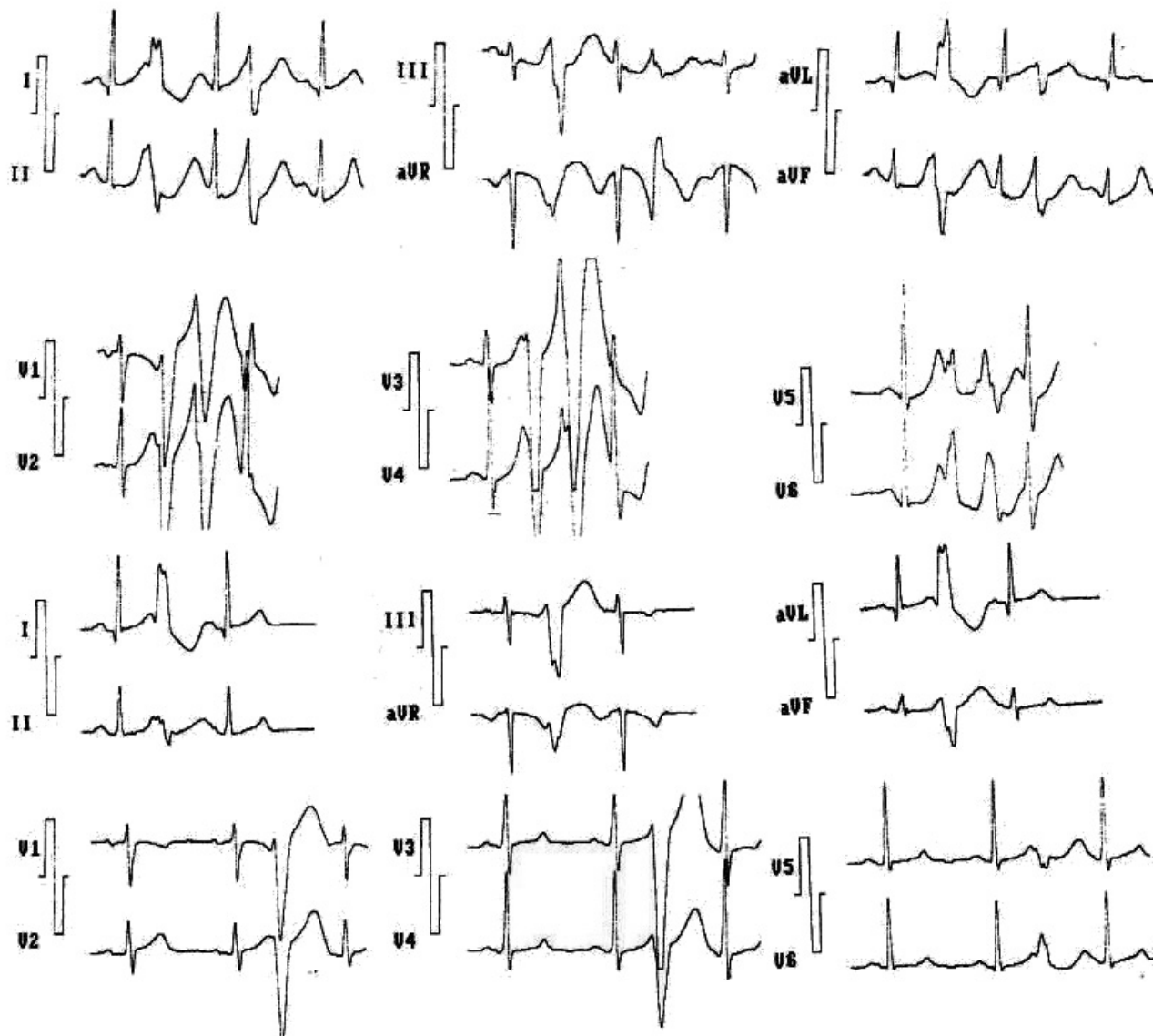


Figure 6. The patient, without structural heart disease, was resuscitated from an episode of sudden death. Short-coupled (ultra-short) premature ventricular contractions triggering repetitive ventricular response are observed in the electrocardiogram. She had also had ventricular fibrillation. Automatic cardio-defibrillator was implanted.

Purkinje's SC-PVC (narrow and precocious)¹⁹⁻²².

The same SC-PVC that triggered MVA are often seen, without doing so at other times or giving rise only to repetitive ventricular responses.

In an IVF study of our service²³ (n=33), 69.7% of the patients had premonitory electrical signs of risk; the most frequent: PVC (27.3%) and T wave alterations.

Both PVC and SC-PVC can trigger MVA or not, which gives an idea of the transcendent variable of this predictor. One limitation of this series is that

there is no control group, that is, patients with SC-PVC that caused not MVA; it would be difficult to achieve because they are subjects who scarcely go to the doctor.

Regarding treatment, ICD was preferred in our cases because almost all of them were recovered from SD events. There are two other therapeutic options: quinidine (used in some of our cases associated to ICD), effective in several situations in subjects with heart considered structurally healthy (Brugada, short QT, and early repolarization syn-

dromes), in IVF, and in multifocal ectopic Purkinje premature contractions (MEPPC), which normalizes the short ventricular refractory period, prevents VF, decreases PVC, and blocks the transient potassium output; and SC-PVC ablation, which is not practiced in our cases²⁴⁻³¹.

With the ablation of the PVC as possible VF triggers, a similar reasoning should be followed to its elimination with AD in the past (in case they do not trigger MVA), because the method is not risk-free nor is it applicable to all VF; on the other hand, there may be recurrences or new PVC outbreaks¹⁴.

CONCLUSIONS

Short-coupled premature ventricular contractions are premonitory electrical signs and triggers for malignant ventricular arrhythmias, and sudden death events in patients with/without structural heart disease. The clinical presentation is sudden death, followed by syncopal episodes. The most frequent ventricular arrhythmias are ventricular fibrillation and helical tachycardia. The lower degree of coupling of the premature contractions (ultra-short, ascending branch and top of the T wave), the greater risk of causing ventricular arrhythmias and sudden death. Although it is not the only one, the short-coupled interval of premature ventricular contractions is one of the key factors for the risk stratification of such extrasystoles. Therapeutic strategies are the implantable cardioverter-defibrillator (if malignant arrhythmias are triggered), antiarrhythmic drugs use/suppression, and others.

REFERENCES

1. Katritsis DG, Josephson ME. Sudden cardiac death and implantable cardioverter defibrillators: two modern epidemics? *Europace*. 2012;14:787-94.
2. Callans DJ, Josephson ME. Management of ventricular arrhythmias: an historical perspective. En: *Contemporary Cardiology: Management of cardiac arrhythmias*. 2011. p. 3-16.
3. Callans DJ, Epstein AE. Reflections on the lowly PVC. *Heart Rhythm*. 2015;12:714-5.
4. Lee YH, Zhong L, Roger VL, Asirvatham SJ, Shen WK, Slusser JP, *et al*. Frequency, origin, and outcome of ventricular premature complexes in patients with or without heart diseases. *Am J Cardiol*. 2014;114:1373-8.
5. Cardiac Arrhythmia Suppression Trial (CAST) Investigators. Preliminary report: Effect of encainide and flecainide on mortality in a randomized trial of arrhythmia suppression after myocardial infarction. *N Engl J Med*. 1989;321:406-12.
6. Haïssaguerre M, Shoda M, Jais P, Nogami A, Shah DC, Kautzner J, *et al*. Mapping and ablation of idiopathic ventricular fibrillation. *Circulation*. 2002;106:962-7.
7. Marai I, Gepstein L, Boulos M, Suleiman M. Ablation of idiopathic ventricular fibrillation triggered by ventricular premature beat originating from myocardium of right ventricle: Case report. *J Cardiol Cases*. 2014;9:109-12.
8. Hayama Y, Kaitani K, Onishi N, Tamaki Y, Miyake M, Kondo H, *et al*. Ablation of idiopathic ventricular fibrillation targeting short coupled ventricular premature contractions originating from a right ventricular papillary muscle. *J Cardiol Cases*. 2014;9:113-6.
9. Lindsay BD. Eliminating triggers of ventricular fibrillation: the past, present, and future. *J Am Coll Cardiol*. 2009;54:529-30.
10. Nogami A. Purkinje-related arrhythmias Part II: Polymorphic ventricular tachycardia and ventricular fibrillation. *Pacing Clin Electrophysiol*. 2011; 34:1034-49.
11. Chinushi M, Iijima K, Sato A, Furushima H. Short-coupling premature ventricular complexes from the left ventricle triggered isoproterenol-resistant electrical storm in a patient with Brugada syndrome. *Heart Rhythm*. 2013;10:916-20.
12. Laurent G, Saal S, Amarouch MY, Béziau DM, Marsman RF, Faivre L, *et al*. Multifocal ectopic Purkinje-related premature contractions. A new SCN5A-related cardiac channelopathy. *J Am Coll Cardiol*. 2012;60:144-56.
13. Viskin S, Rosso R, Rogowski O, Belhassen B. The "short-coupled" variant of right ventricular outflow ventricular tachycardia: a not-so-benign form of benign ventricular tachycardia. *J Cardiovasc Electrophysiol*. 2005;16:912-6.
14. Sullivan RM, Olshansky B. Treatment of PVCs post-myocardial infarction: will we get fooled again. *Heart Rhythm*. 2009;6:1550-1.
15. Sánchez Muñoz JJ, García-Alberola A, Martínez-Sánchez J, Peñafiel-Verdú P, Caro-Martínez C, Manzano-Fernández S, *et al*. Extrasistolia ventricular desencadenante de la fibrilación ventricular. *Rev Esp Cardiol*. 2010;63:798-801.

16. Viskin S. Idiopathic ventricular fibrillation “Le syndrome d’Haïssaguerre” and the fear of J waves. *J Am Coll Cardiol*. 2009;53:620-2.
17. Kondo H, Shinohara T, Takahashi N. A case of short-coupled premature ventricular beat-induced ventricular fibrillation with early repolarization in the inferolateral leads. *J Arrhythmia*. 2015;31:60-3.
18. Dorantes M. Algo de historia. Proarritmia. *Rev Cubana Cardiol Cir Cardiovasc* [Internet]. 2012 [Accessed Jul 14, 2016];18:228-31. Available at: <http://www.revcardiologia.sld.cu/index.php/revcardiologia/article/view/326/316>
19. Scheinman MM. Role of the His-Purkinje system in the genesis of cardiac arrhythmia. *Heart Rhythm*. 2009;6:1050-8.
20. Ideker RE, Kong W, Pogwizd S. Purkinje fibers and arrhythmias. *Pacing Clin Electrophysiol*. 2009;32:283-5.
21. Baher AA, Uy M, Xie F, Garfinkel A, Qu Z, Weiss JN. Bidirectional ventricular tachycardia: ping pong in the His-Purkinje system. *Heart Rhythm*. 2011;8:599-605.
22. Rosenheck S. Arrhythmogenicity of the Purkinje system: a new step toward understanding ventricular fibrillation. *Heart Rhythm*. 2009;6:1790-1.
23. López Delgado A, Dorantes Sánchez M. Fibrilación ventricular idiopática. *Rev Cubana Cardiol Cir Cardiovasc* [Internet]. 2013 [Accessed Jul 4, 2016];19:5-12. Available at: <http://www.revcardiologia.sld.cu/index.php/revcardiologia/article/view/310/526>
24. Dorantes M. Apunte histórico sobre la quinidina. *CorSalud* [Internet]. 2013 [Accessed Jul 20, 2016]; 5: 361-5. Available at: http://www.sld.cu/galerias/pdf/sitios/cardiologia/corsalud_quinidina.pdf
25. Belhassen B. Is quinidine the ideal drug for Brugada syndrome? *Heart Rhythm*. 2012;9:2001-2.
26. Vardas PE, Kanoupakis EM. Old drugs never die; they just fade away. *Heart Rhythm*. 2010;7:864.
27. Viskin S, Antzelevitch C, Márquez MF, Belhassen B. Quinidine: a valuable medication joins the list of ‘endangered species’. *Europace*. 2007;9:1105-6.
28. Viskin S, Wilde AA, Tan HL, Antzelevitch C, Shimizu W, Belhassen B. Empiric quinidine therapy for asymptomatic Brugada syndrome: time for a prospective registry. *Heart Rhythm*. 2009;6:401-4.
29. Viskin S, Belhassen B, Wilde AA. Irreplaceable antiarrhythmic medications are disappearing: the case of quinidine. *Heart Rhythm*. 2010;7:863.
30. Márquez MF, Bonny A, Hernández-Castillo E, De Sisti A, Gómez-Flores J, Nava S, *et al*. Long-term efficacy of low doses of quinidine on malignant arrhythmias in Brugada syndrome with an implantable cardioverter-defibrillator: a case series and literature review. *Heart Rhythm*. 2012;9:1995-2000.
31. Yang F, Hanon S, Lam P, Schweitzer P. Quinidine revisited. *Am J Med*. 2009;122:317-21.