


## A case of Kounis syndrome in Sagua la Grande

Yamir Santos Monzón , MD; Jesús A. Pérez González, MD; Antonio Mata Cuevas, MD; Yonielis Rivero Nóbrega, MD; and Jesús J. Roque Corzo, MD

Hospital "Mártires del 9 de Abril". Sagua la Grande, Villa Clara, Cuba.

*Este artículo también está disponible en español*

### ARTICLE INFORMATION

Received: November 6, 2013  
Accepted: December 12, 2013


### Competing interests

The authors declare no competing interests

### Acronyms

AMI: acute myocardial infarction

On-Line Versions:  
[Spanish - English](#)

 Y Santos Monzón  
Colón N° 172  
Sagua la Grande, CP 52310  
Villa Clara, Cuba.  
E-mail address:  
[yamir@hospisag.vcl.sld.cu](mailto:yamir@hospisag.vcl.sld.cu)

### ABSTRACT

Allergic acute coronary syndrome, also known as Kounis syndrome, is currently under-diagnosed as a result of its low disclosure. The case of a 29-year-old man is reported. He was stung by a wasp and developed an acute coronary syndrome with ST segment elevation related to the allergic process. After an appropriate treatment, the patient improved. The case is reported with the aim of raising awareness about a recently described disease that should be considered as a differential diagnosis in the presence of an acute coronary syndrome.

**Key words:** Kounis syndrome; Acute coronary syndrome; Acute myocardial infarction; Treatment

### *Un caso de Síndrome de Kounis en Sagua la Grande*

### RESUMEN

El síndrome coronario agudo alérgico, también conocido como síndrome de Kounis, se encuentra en la actualidad infradiagnosticado por su poca divulgación. Se presenta el caso de un varón de 29 años de edad que fue picado por una avispa y desarrolló un síndrome coronario agudo con supradesnivel del ST en relación al proceso alérgico. Después del tratamiento adecuado el paciente evolucionó favorablemente. Se presenta el caso con el objetivo de dar a conocer una enfermedad de reciente descripción y que consideramos debe valorarse como un diagnóstico diferencial ante la presencia de un síndrome coronario agudo.

**Palabras clave:** Síndrome de Kounis; Síndrome coronario agudo; Infarto agudo de miocardio; Tratamiento

### INTRODUCTION

In 1991, Kounis and Zavras<sup>1</sup> described the acute coronary syndrome in the context of allergic reactions, also called Kounis syndrome. Therefore, in recent years, the number of reports of this disease has increased in the literature.

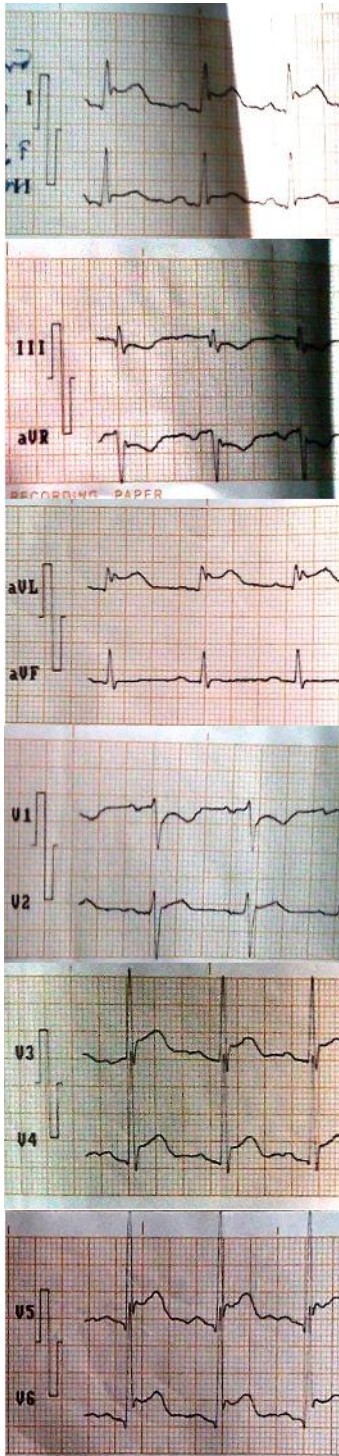
The syndrome was described as an allergic angina by the Greek Professor Nicholas G. Kounis. It may progress to cause an acute myocardial infarction (AMI), of allergic origin<sup>2</sup>. The release of inflammatory mediators during mast cell degranulation is the root cause of this disease, although it has also been

reported that these mediators are increased in non-allergic coronary syndromes.

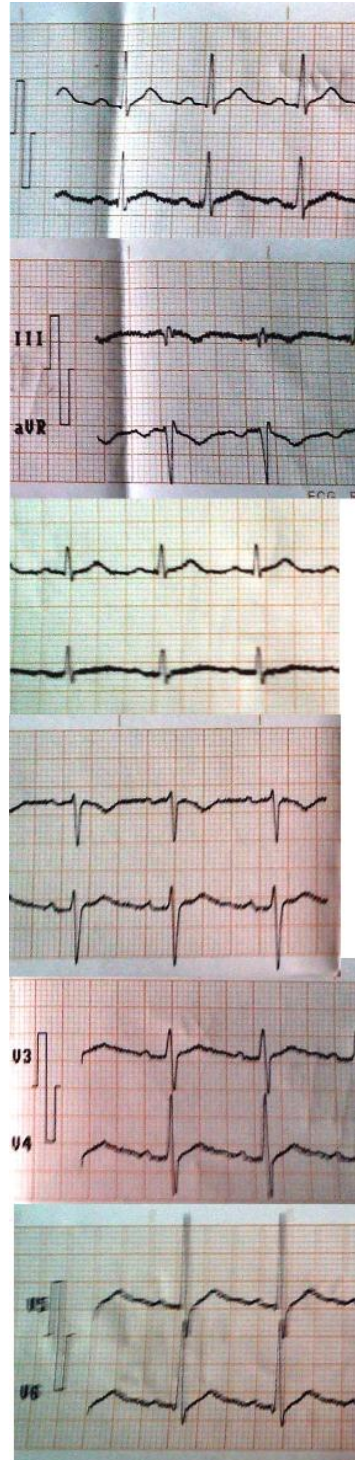
The potential triggers of this disease include Hymenoptera stings, drugs, adverse environmental exposures, food, among other causes of anaphylaxis. Three varieties of the syndrome have been described; type 1, in which the coronary arteries of the subject with the syndrome are normal, a type 2, in which there is a pre-existing coronary heart disease; and type 3, which is still not accepted by all authors but is gaining strength, where there is a coronary thrombosis that may occur intra-stent<sup>3, 4</sup>.

### CASE REPORT

A 29-year-old male with a history of good health was stung by a wasp, which caused a major allergic reaction in the affected area. He soon presented with an oppressive, retrosternal and intense chest pain that forced him to go to the nearest doctor's office. After performing an electrocardiogram, it was decided to transfer him to the hospital with a presumptive diagnosis of AMI, taking into account the manifestations of pain and the interpretation of the electrocardiogram, which showed ST segment elevation in the leads DI, aVL and from V<sub>2</sub> to V<sub>6</sub> (Figure 1). Sublingual nitroglycerin was administered three times, and diphenhydramine and intravenous hydrocortisone was administered for the facial edema caused by the insect bite. The patient had normal blood pressure levels and was transferred to the Intensive Care Unit of the Mártires del 9 de Abril Hospital with a diagnosis of AMI with ST segment elevation in order to consider thrombolytic therapy. However, the apparent improvement in the patient, from



**Figure 1.** A 12-lead electrocardiogram performed on admission. There is ST elevation in DI, aVL, V2-V<sub>6</sub> leads



**Figure 2.** A 12-lead electrocardiogram performed prior to discharge, which shows the normalization of the ST segment.

the clinical point of view (pain relief), and the electrical improvement (gradual regression of electrocardiographic changes), together with the absence of enzyme elevation led us to decide not to perform thrombolysis. A calcium antagonist was administered (diltiazem 120 mg), as well as aspirin 125 mg and clopidogrel (loading dose of 150 mg and maintenance, 75 mg/day). The steroid therapy was kept for 5 days. The patient improved and was discharged 7 days later with a normal electrocardiogram (**Figure 2**) and without symptoms.

Before discharge, an echocardiogram was performed, and no regional motility disorders were found. The systolic function was preserved, there was no chamber dilation, no sign of hypertrophy, and the valve apparatus was competent. In an exercise test, performed 14 days after the onset of symptoms, the patient reached the maximum heart rate without electrocardiographic, hemodynamic or clinical changes. Afterwards, a coronary angiography was performed and it showed normal coronary arteries.

The patient continues with diltiazem (120 mg/day) and aspirin (125 mg/day), plus an occasional symptomatic treatment due to his history of atopy. There have not been similar episodes during follow-up.

## COMMENT

Kounis syndrome or allergic acute coronary syndrome, usually has a good prognosis, although two cases of cardiogenic shock have been described<sup>5,6</sup>. A subsequent decrease in myocardial function has also been described; and, although it usually recovers later, it may compromise patient outcomes. This unfavorable course is most often associated with Kounis syndrome type 2<sup>7</sup>.

The functional and metabolic changes occurring in this syndrome are caused mainly by histamine and other metabolites, including the arachidonic acid cascade, which causes severe allergic damage to the heart<sup>1,8</sup>. The existence of mast cells in cardiac tissue has been explicitly related to the presence of tachycardia, coronary vasoconstriction, ventricular dysfunction and atrioventricular block. These anomalies are attributed to the release of mediators such as histamine, thromboxane, prostaglandins, leukotrienes and platelet activating factor. Recently, it has also been described that the release of renin during an anaphylaxis episode contributes to ventricular dysfunction<sup>9</sup>. On the other hand, there have been reports

of angina or AMI after the administration of the epinephrine used to treat an anaphylactic shock<sup>10</sup>, as a result of the effect of this drug in QT prolongation, arrhythmia induction and coronary vasospasm.

Currently, no medical guide or consensus has been published for the treatment of these patients. Although most authors agree to use steroids, antihistamines and antithrombotic therapy, it is also common the use of calcium antagonists<sup>11</sup>, which seems to be very useful due to their vasodilator effect and the vasospastic component involved in this disease. It may also be beneficial to keep calcium antagonist therapy as adjuvant treatment in order to prevent future vasospasms, which may still occur after an episode as the one described above, even in a case of Kounis syndrome type 1, that is, without coronary disease. The administration of epinephrine is debatable, for the reason stated above; and although some authors have used it, we believe it should only be administered in cases of severe hypotension or cardiac arrest, due to the controversial and dangerous nature of its use in acute coronary syndrome, regardless of its etiology.

In view of the not very extensive literature on the subject and the paucity of published cases, we thought Kounis syndrome might be an underdiagnosed condition in cardiology services. Therefore, it is emphasized the need to include this syndrome as a probable cause of acute coronary syndrome.

## REFERENCIAS BIBLIOGRÁFICAS

1. Kounis NG, Zavras GM. Histamine-induced coronary artery spasm: the concept of allergic angina. *Br J Clin Pract.* 1991;45(2):121-8.
2. Kounis NG, Zavras GM. Allergic angina and allergic myocardial infarction. *Circulation.* 1996;94(7):1789.
3. Rich MW. Is vasospastic angina an inflammatory disease? *Am J Cardiol.* 2005;96(11):1612.
4. Waller BF. Nonatherosclerotic coronary heart disease. En: Fuster V, O'Rourke RA, Walsh RA, Poole-Wilson P, eds. *Hurst's The Heart.* 12ma Ed. New York: McGraw Hill, 2008; p. 1277-1310.
5. Tanboga IH, Karabay CY, Can MM, Akgün T, Güler A, Turkyılmaz E, et al. Kounis syndrome presenting with cardiogenic shock. *J Cardiovasc Med (Hagerstown).* 2011;12(11):833-6.
6. Garcipérez de Vargas FJ, Mendoza J, Sanchez-Calderón P, Ortiz C, Porro R, Mogollón-Jiménez MV. *Shock* cardiogénico secundario a síndrome de Kounis tipo II inducido por metamizol. *Rev Esp Cardiol.*

- 2012;65(12):1138-9.
7. Gázquez V, Dalmau G, Gaig P, Gómez C, Navarro S, Mercé J. Kounis Syndrome: Report of 5 Cases. *J Investig Allergol Clin Immunol*. 2010;20(2):162-5.
  8. Bani D, Nistri S, Mannaioni PF, Masini E. Cardiac anaphylaxis: pathophysiology and therapeutic perspectives. *Curr Allergy Asthma Rep*. 2006;6(1):14-9.
  9. Reid A, Silver RB, Levi R. Renin: at the heart of the mast cell. *Immunol Rev*. 2007;217:123-40.
  10. Mueller UR. Cardiovascular disease and anaphylaxis. *Curr Opin Allergy Clin Immunol*. 2007;7(4):337-41.
  11. Cevik C, Nugent K, Shome GP, Kounis NG. Treatment of Kounis syndrome. *Int J Cardiol*. 2010;143(3):223-6.