

Sudden death with non-structural heart disease: apropos of a case

María Á. Hernández Sosa¹✉, MD, MSc; and Yleana Vizcaíno Dimé², MD, MSc

¹Facultad de Ciencias Médicas General Calixto García. Havana, Cuba.

²Instituto de Medicina Legal. Havana, Cuba.

Este artículo también está disponible en español

ARTICLE INFORMATION

Received: April 18, 2017

Accepted: May 18, 2017

Competing interests

The authors declare no competing interests

Acronyms

SD: sudden death

SCD: sudden cardiac death

On-Line English & Spanish
versions

✉ MA Hernández Sosa
FCM General Calixto García
Calle G s/n entre 25 y 27. Plaza de la
Revolución 10400. La Habana, Cuba.
E-mail address:
mhsosa@infomed.sld.cu

ABSTRACT

Sudden death of cardiac origin is considered a typical example of suspected crime death in the medical-legal field since its rapid and unexpected presentation, with no apparent cause of death, does not allow ruling out its violent origin. This makes it more difficult when necropsy and complementary studies are negative. The so-called functional sudden deaths are included in this group. A case presented in Havana, in 2014 which required necropsy, led to an updated review of sudden cardiac death with non-structural heart disease and its repercussion from the medico-legal point of view.

Key words: Sudden death, Non-structural heart disease, Suspected crime death

Muerte súbita con cardiopatía no estructural: a propósito de un caso

RESUMEN

La muerte súbita de origen cardiovascular es considerada un ejemplo característico de muerte sospechosa de criminalidad en el ámbito medicolegal, pues por su presentación rápida e inesperada, sin causa de muerte aparente, no permite descartar su origen violento. Esto se complejiza cuando la necropsia y los estudios complementarios son negativos. En este grupo se encuentran las denominadas muertes súbitas funcionales. A partir de la presentación de un caso que fue motivo de necropsia en La Habana, en el año 2014, se realizó una revisión actualizada sobre la muerte súbita cardiovascular con cardiopatía no estructural y su repercusión desde el punto de vista medicolegal.

Palabras clave: Muerte súbita, Cardiopatía no estructural, Muerte sospechosa de criminalidad

INTRODUCTION

Although there is no universal agreement on the definition of sudden death (SD), it is generally accepted that its cause is natural, that its installation is unexpected and elapses rapidly from the onset of symptoms, if these appear. However, due to its nature, it has been considered in the medical-legal field the characteristic example of suspected crime death^{1,2}, which is confirmed or rejected with a thorough autopsy and the result of the anatomo-

mopathological and toxicological studies³⁻⁵.

At the conclusion of these studies, a high percentage of SD are explained, mostly, due to a cardiovascular cause; but sometimes the autopsy's findings are unspecific and it is the case of a functional SD, whose cause of death is unprovable in the medical-legal practice^{2,3}.

For authors like Fellner and Navari¹, the sudden cardiac death (SCD), where there is a structurally intact heart, is a real forensic challenge, and its most frequent causes are the heart rhythm disorders. Nevertheless, they consider that actually, most of these patients do not really have normal hearts, but the current diagnostic elements are not enough for stating a diagnose of the structural or functional responsible alterations¹.

Epidemiological aspects

Although the incidence of SCD worldwide is difficult to estimate, most authors agree that it is between 10 and 30% of all natural deaths^{1,2}. In Cuba, there are no official records for the SCD; however, it has been estimated that the incidence may be between 11.7 and 13.0% of natural deaths (one episode every 48 minutes)^{6,7}.

The main cause of SCD is the ischemic heart disease, with greater prevalence in the male sex, in ages between 60 and 74^{2,6}.

Nonetheless, when it comes to young adults, the cause has a different behavior. A study published in the Journal of the American College of Cardiology states that before 35 years, the leading cause of SD is "the sudden death without identifiable structural heart abnormality, presumably arrhythmic"⁸. The male sex predominated throughout this research, as well as in studies developed in Cuba⁶.

Risk factors

The adult population is more likely to suffer an episode of SCD, when there are associated predisposing factors for atherosclerosis such as: high blood pressure, obesity, diabetes mellitus, history of ischemic heart disease, smoking and thickening of the left ventricle⁷.

In young adults, stratifying and modifying the risks associated with SCD is not an easy task, since predicting who will present a malignant episode from premonitory signs is very difficult and often, impossible⁹. It should be remembered that, moreover, they are often individuals who appear to be absolutely healthy.

Nevertheless, there are authors who expose that

half of young patients that suffer a SCD with a structurally healthy heart has a history of syncope, palpitations or chest pain and in a high percentage, some identifiable condition associated with the SD (family history, preexcitation syndrome or evidence of drug use associated with the SD)¹.

CASE REPORT

The following is the case of an 18-year-old teenager, who was in a student camp. The day he died was festive and after dinner, where no alcoholic drinks were found, he went out to make the route he was supposed to do around the camp; two hours later, as he did not come back to make the change with the person who would do the new route, people went to look for him and found him on the ground, prone position, «without consciousness». He was immediately moved to a nearby health facility where he arrived without vital signs; however, he is performed resuscitation maneuvers and twenty minutes after he is declared deceased.

The police investigation did not provide any element of importance on the scene where he was found deceased. In the interrogation to the parents, it was possible to know that he had a health history of practicing exercises and swimming, and that the week before his death he presented a flu condition that disappeared with symptomatic treatment.

As family medical history was known that his parents suffered from high blood pressure; the mother was obese; the maternal grandfather died at 62 years of age due to an acute myocardial infarction; the maternal grandmother had a diagnosis of ischemic heart disease and passed away suddenly at the age 59, and the maternal uncle, of 48 years old, «suffered from the heart», without a precise diagnosis.

Results of the necropsy

- Examination of the body's exterior: An evident cyanosis on facial and upper extremity and subungual was confirmed, as well as pinpoint excoriations in both knees.
- Examination of the body's interior: There was observed a marked generalized visceral congestion, subpleural and subepicardial petechiae (Tardieu ecchymoses) (**Figure**), no cardiac malformations or in other organs. Food in early stage of digestion (corresponding to what was declared at dinner).

- Complementary tests:
 - Toxicological: The tests of orientation for different types of drugs, alcohol in blood and general toxicological march, as well as the study of the candy paper found near corpse, and the stomach content, all were negative.
 - Anatomopathological: A marked widespread visceral congestion and signs of slight pulmonary edema were observed. The special techniques for studying the heart and for viruses and bacteria resulted negative.
- Cause of death: Sudden cardiac death.

COMMENT

The SCD is the first and only manifestation of cardiovascular disease in the 20-40% of cases⁷. Its cause varies with age and it is considered that before the age of 35 is related, in a high percent, with heart rhythm disorders without identifiable structural heart abnormality⁸.

The most characteristic examples of this are the arrhythmogenic diseases, like channelopathies, constituted a new discipline in 1995 and included within primary genetic heart diseases in 2006⁹.

The channelopathies have as base, a dysfunction in the traffic of cardiac ion channels with an abnormal myocyte (mutations with gain or loss of function) in different locations (epicardium, endocardium, right or left ventricular system, expert conduction system)⁹. This group includes the long QT, short QT and Brugada syndromes as well as the catecholaminergic polymorphic ventricular tachycardia, Lev-Lenegre disease and the nocturnal inexplicable sudden death syndrome⁹.

Any of these channelopathies appears frequently in young individuals, males, in the form of SD and the autopsy is negative⁹. Nowadays, molecular genetics has revealed the changes at the level of the molecular membrane⁹ and people already talk about a molecular necropsy¹. Its diagnosis is made by exclusion, by ruling out cardiac structural alterations, electrolyte or metabolic disorders, and other electrical causes, as well as the use of antiarrhythmic drugs⁹.

A study by Ochoa Montes⁶ highlights that 4% of non-recovered cardiac arrests take place between 15 and 44 years, what shows that the immense efforts developed at the present time to reverse this reality

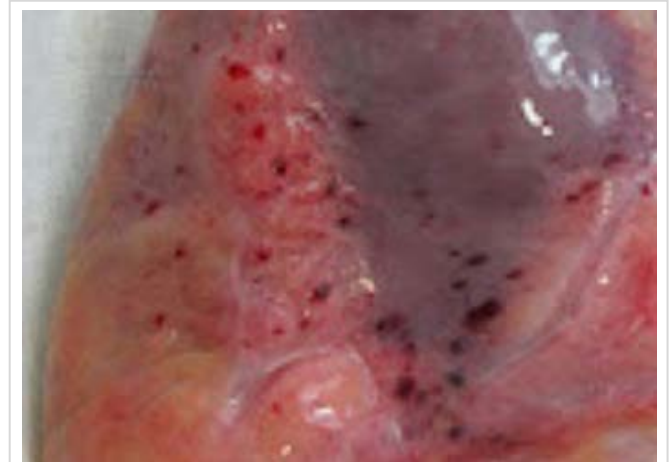


Figure. Tardieu ecchymoses. Archive image (modified from goo.gl/yRH5WK).

are not only justified by their high incidence, but also for the drama with which this occurs, because it affects apparently healthy young people⁶.

The SCD is one of the most important causes of years of life potentially lost in the different age groups. Causing serious losses in the family, economic and social frameworks at the unexpected death of an apparently healthy individual, not infrequently prematurely, at a young age, because of a cardiac disorder, which gives it a dramatic character to the episode⁷.

When confronted with sudden death, it is important to collect records of the victim (statements of relatives, medical history, among other things), since in many cases, it may be the only element that allows us to arrive at a diagnosis of death, because it is well known that a high percentage occurs at the residence or during transportation to a health facility⁶.

In the case presented, a thorough analysis of all available elements was made, no personal medical history was found, but in the family. Finally, it was possible to conclude that the death was in relation to a SCD with non-structural heart disease. This diagnosis was stated by exclusion, once the presence of a violent death (or traumatic) and explanatory causes of natural origin were ruled out.

REFERENCES

1. Fellner JP, Navari CA. Investigación médico legal de la muerte súbita no violenta. Cuad Med Fo

- rense (Argentina) [Internet]. 2003 [citado 30 Nov 2016];2(2):7. Disponible en:
[http://www.csjn.gov.ar/cmfc/files/pdf/_Tomo-2\(2003\)/Numero-2/CMF2-2-7.doc](http://www.csjn.gov.ar/cmfc/files/pdf/_Tomo-2(2003)/Numero-2/CMF2-2-7.doc)
2. Castellá García J, Medallo Muñoz J, Marrón Moya T. Aspectos medicolegales de la muerte súbita cardiaca. *Rev Esp Cardiol*. 2013;13(Supl. A):30-7.
 3. Pérez Álvarez H, Ferrer Marrero D. Aspectos médico-legales de la muerte súbita cardiovascular. *CorSalud* [Internet]. 2014 [citado 30 Nov 2016];6(Supl. 1):65-70 Disponible en:
<http://www.corsalud.sld.cu/suplementos/2014/v6s1a14/legal.html>
 4. Gisbert Calabuig, JA. *Medicina Legal y Toxicología*. 6^{ta} Ed. Barcelona: Masson, SA; 2005.
 5. Vargas Alvarado E. *Medicina Forense y Deontología Médica*. México: Trillas; 2005.
 6. Ochoa Montes LA, González Lugo M, Tamayo Vicente ND, Gómez de Haz HJ, Correa Azahares DP, Miguélez Nodarse R, *et al*. Epidemiología de la muerte súbita cardíaca. *Rev Cubana Hig Epidemiol* [Internet]. 2012 [citado 30 Nov 2016];50(1):14-24. Disponible en:
http://scielo.sld.cu/scielo.php?script=sci_arttext&pid=S1561-30032012000100003&lng=es&nrm=iso&tlng=es
 7. Ochoa Montes LA, Tamayo Vicente ND, González Lugo M, Vilches Izquierdo E, Quispe Santos JF, Pernas Sánchez Y, *et al*. Resultados del Grupo de Investigación en Muerte Súbita, 20 años después de su creación. *Rev Cubana Salud Pública* [Internet]. 2015 [citado 30 Nov 2016];41(2):298-323. Disponible en:
<http://scielo.sld.cu/pdf/rcsp/v41n2/spu10215.pdf>
 8. Eckart RE, Shry EA, Burke AP, McNear JA, Appel DA, Castillo-Rojas LM, *et al*. Sudden death in young adults: an autopsy-based series of a population undergoing active surveillance. *J Am Coll Cardiol*. 2011;58(12):1254-61.
 9. Dorantes Sánchez M. Canalopatías iónicas: generalidades y panorámica actual. *Rev Cubana Invest Bioméd* [Internet]. 2012 [citado 30 Nov 2016];31(1):1-15. Disponible en:
<http://scielo.sld.cu/pdf/ibi/v31n1/ibi01112.pdf>
 10. Cruz Cardentey M. Síndrome de QT corto. *Rev Cubana Invest Bioméd* [Internet]. 2012 [citado 30 Nov 2016];31(2):145-56. Disponible en:
<http://scielo.sld.cu/pdf/ibi/v31n2/ibi02212.pdf>
 11. Romero García A, Fernández Chelala FI, Domínguez Pérez RJ, Padrosa Santos D, Santos Hernández AM. Síndrome de Brugada. Reporte de caso. *CCM* [Internet]. 2014 [citado 30 Nov 2016];18(2):363-71. Disponible en:
<http://scielo.sld.cu/pdf/ccm/v18n2/ccm22214.pdf>
 12. Rodríguez Font E, Viñolas Prat X. Causas de muerte súbita. Problemas a la hora de establecer y clasificar los tipos de muerte. *Rev Esp Cardiol*. 1999;52(11):1004-14.