

Very late thrombosis of bare-metal stent: Apropos of a case

Ricardo A. García Hernández¹✉, MD, MSc; Lianet Rivero Seriel², MD; and Rogelio L. Romero Millares¹, MD, MSc

¹Department of Cardiology, Centro Nacional de Rehabilitación Julio Díaz González. Havana, Cuba.

²Department of Cardiology, Hospital Clínico-Quirúrgico Hermanos Ameijeiras. Havana, Cuba.

Este artículo también está disponible en español

ARTICLE INFORMATION

Received: August 17, 2017

Accepted: September 28, 2017

Competing interests

The authors declare no competing interests

Acronyms

BMS: bare metal stent

DES: drug-eluting stent

ABSTRACT

The very late thrombosis of a conventional stent is an uncommon event, although its consequences can be catastrophic for the patient, being associated with an increase in the long-term mortality rate. Here is exposed the case of a 60-year-old man who presented an acute inferior myocardial infarction due to definitive thrombosis of the conventional stent, after 24 months of implantation.

Key words: Bare metal stent, Thrombosis, Acute myocardial infarction, Percutaneous coronary intervention

Trombosis muy tardía de stent convencional. A propósito de un caso

RESUMEN

La trombosis muy tardía de un stent convencional es un evento poco frecuente, aunque sus consecuencias pueden ser catastróficas para el paciente y asociarse a un incremento en la tasa de mortalidad a largo plazo. Se presenta el caso de un hombre de 60 años de edad que presentó un infarto agudo de miocardio de cara inferior por trombosis definitiva del stent convencional tras 24 meses de implantado.

Palabras clave: Stent convencional, Trombosis, Infarto agudo de miocardio, Intervencionismo coronario percutáneo

On-Line English & Spanish versions

INTRODUCTION

With the introduction of coronary stents in the therapeutic arsenal for percutaneous coronary intervention there was a significant reduction in the occurrence of acute occlusions (associated with coronary dissection, intracoronary thrombus and elastic recoil), and the incidence of restenosis (associated with negative arterial remodeling and neointimal hyperplasia), characteristically associated with the use of balloons.

However, despite coronary stents have substantial advantages over the use of balloon angioplasty, stent thrombosis is a serious problem that may manifest as myocardial infarction and sudden death¹.

✉ RA García Hernández.
Ave. 243 N° 19815, Fontanar. La Habana, Cuba. E-mail address: ramador@infomed.sld.cu

The arrival of drug-eluting stents (DES) was thought to wipe out this complication but only 5 years after the first study² supporting the use of these devices and their spectacular results, several meta-analyses seemed to indicate an increase in long-term mortality. The culprit?... very late stent thrombosis, which until then, had been underemphasized in case reports. Hence, stent thrombosis would become the great threat after DES implantation³. But this phenomenon is not exclusive to DES since, although very rare, late stent thrombosis has also been described in conventional bare metal stents (BMS).

We present the case of a patient with very late thrombosis 24 months after BMS placement.

CASE REPORT

A 60-year-old man with a history of essential hypertension had a BMS Apolo Small 3.0 x 18 mm stent for

severely occluded proximal right coronary artery in the context of acute inferior myocardial infarction in January 2015. He was on dual antiplatelet therapy for a month and continued taking oral aspirin.

After percutaneous coronary intervention, the patient was enrolled in a cardiac rehabilitation program until reentering the workforce. He remained asymptomatic until January 2017 when he was admitted in his health area due to an oppressive, stabbing chest pain of more than 30 minutes with irradiation to the neck, jaw and left arm, associated with profuse sweating and nausea. A 12-lead electrocardiogram on presentation showed ST segment elevation ≥ 2 mm in D_{II}, D_{III}, aVF, and V₃ to V₆, with ST segment depression in D_I and aVL (Figure 1), consistent with acute inferior wall myocardial infarction. He was urgently commenced on fibrinolytic treatment with recombinant streptokinase with the recommended dose, but either alleviation of symptoms was achieved, nor regression to normal electrocardiographic pattern. So we managed his transfer for

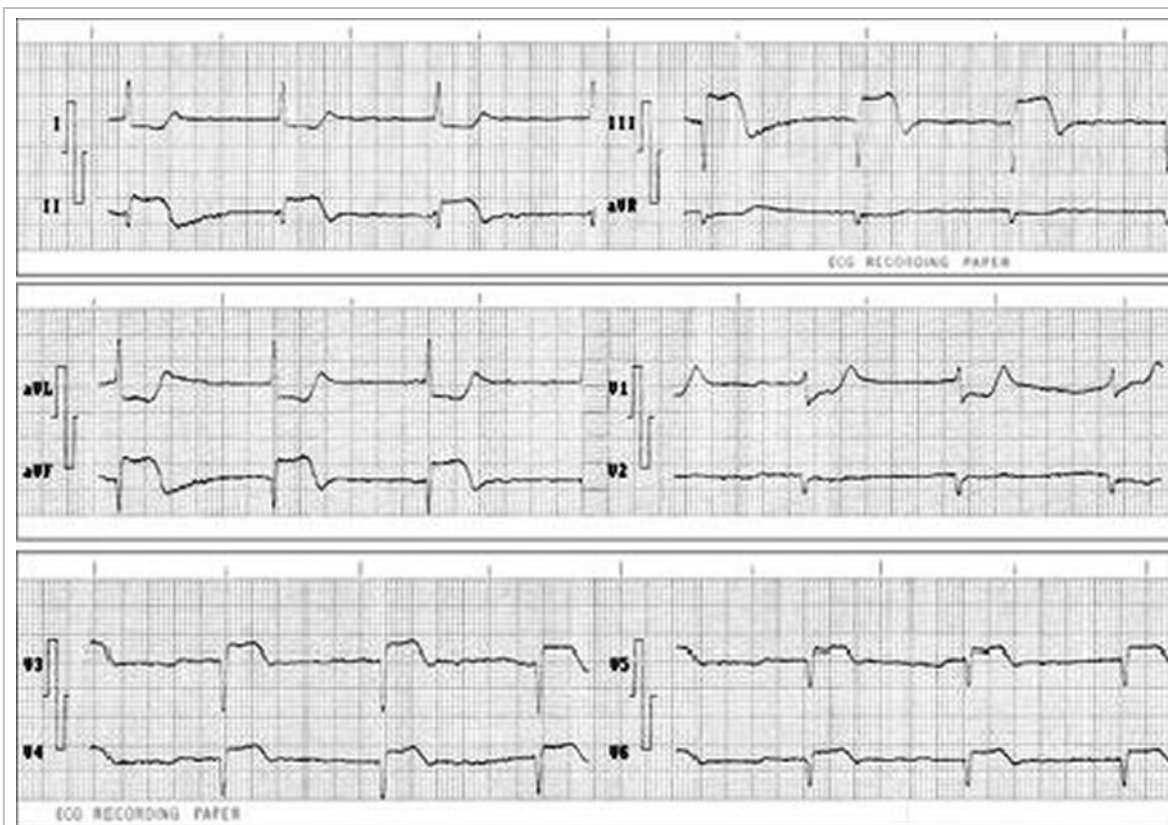


Figure 1. 12-lead electrocardiogram at admission, showing ST-segment elevation in D_{II}, D_{III}, aVF, V₃-V₆.

urgent coronary angiography, demonstrating acute occlusion of the right coronary artery with evidence of a thrombus at the site of stenting (**Figure 2A**). Percutaneous coronary intervention was performed and another 3.0 × 23 mm bare metal stent was implanted and good angiographic result was achieved (**Figure 2 B y C**).

The patient made an uneventful recovery and was discharged without any symptoms. Thereafter, he has remained asymptomatic.

COMMENT

Stent thrombosis is unusual (<1%), but with high morbidity and mortality (20-40%)⁴. With BMS, most thromboses usually occur in the first days after implantation. It is an exceptional complication after the first month. Hence, dual antiplatelet therapy is prescribed during this period⁵.

However, the identification of new late thrombotic events (beyond the traditional 30 days) and the potential risk of increased frequency of this complication over time, turned this phenomenon –which until then received scarce attention in case reports– into a latent threat³, raising great concern and controversy in the cardiological community.

Since the beginning, stent thrombosis was classified according to angiographic, clinical and time parameters. Although these classifications were extensive and did not fully encompass the expectations to detect the true dimension of the problem. Therefore, new standardised definitions of stent thrombosis were obtained, which included the con-

cepts of definite, probable and possible thrombosis. Similarly, the temporal classification was modified to adjust to the new thrombosis tendency, and the «very late» definition was suggested when it occurred after one year of stent implantation^{1,3,6}.

Its mechanisms are little understood, but several factors are known to stimulate it (**Box**). Moreover, it has been suggested that stent thrombogenicity depends largely on the electropositive charge of its metallic coating, which seems to be modified by its composition, configuration and size, and consequently the protective «defense» response of the vessel; in addition to the presence of late-onset atheromatous plaques in the stent (neoatherosclerosis)⁷⁻⁹.

On this point, we should comment that, although DES, compared to BMS have notable advantages in relation to the appearance of thrombosis, are equally susceptible to the multifactorial cause. However, the association of new related factors is possible, considering the complexity of these devices: metallic platform (material, geometry, strut thickness), polymer (composition, disposal, thickness, biocompatibility, thrombogenicity, pro-inflammatory potential, biodegradability or lack of polymers) and anti-proliferative drug (molecular composition, biologic actions, doses, releasing kinetics)^{1,3}.

The treatment of this major adverse coronary event consists of immediate restoration of artery blood flow after the occurrence of the event. Most of the time it is successfully treated with mechanical thrombectomy, balloon angioplasty or implantation of another stent (BMS or DES). Coronary artery bypass grafting should be considered when patients do

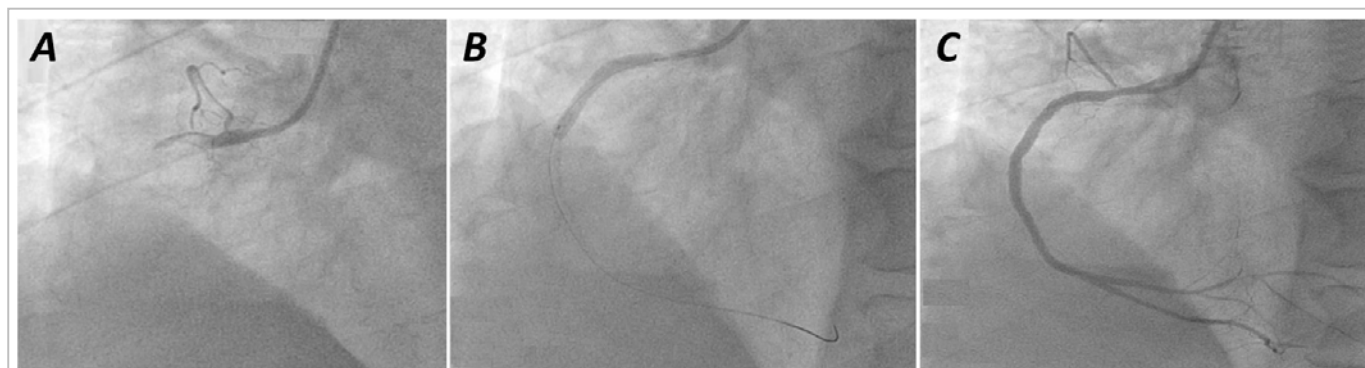


Figure 2. A. 30° left anterior oblique angiographic view showing total occlusion of proximal right coronary artery. B. Stent implantation. C. Angiographic result.

Box. Predisposing factors to stent thrombosis.

Related to patient
- Diabetes mellitus
- Kidney disease
- Severe left ventricular dysfunction
- Poor adherence and resistance to antiplatelet therapy
- Heparin-induced thrombocytopenia
Related to procedure
- Implantation of multiple stents
- Persistent dissections
- Residual thrombi
- Stent malapposition
- Long lesions and long stents
- Small vessels
- Complex lesions
- Slow coronary flow pattern
Related to stent and intimal endothelium
- Incomplete endothelization
- Delayed hypersensitivity
- Physical properties of the stent
- Endothelial dysfunction

not benefit from the previous options^{1,3,10}.

Very late stent thrombosis is extremely rare. Hence, it requires a closer interaction with the patient so that the risk of occurrence can be identified and stratified individually.

REFERENCES

1. Muñoz JS, Linares G, Peña IA. Trombosis del stent. Antes y después de los stents farmacológicos. En: Sousa A GMR, Abizaid A, Martínez Ríos M, Berrocal D, Sousa JE, eds. Intervenciones cardiovasculares SOLACI. 2ªed. Colombia; 2009. p. 453-67.
2. Morice MC, Serruys PW, Sousa JE, Fajadet J, BanHayashi E, Perin M, *et al.* A randomized comparison of a sirolimus-eluting stent with a standard stent for coronary revascularization. *N Engl J Med.* 2002;346(23):1773-80.
3. de la Torre Hernández JM, Windecker S. Trombosis muy tardía con nuevos stentsfarmacoactivos, ¿ha dejado de ser un asunto relevante? *Rev Esp Cardiol.* 2012;65(7):595-8.
4. Holmes DR, Kereiakes DJ, Garg S, Serruys PW, Dehmer GJ, Ellis SG, *et al.* Stent thrombosis. *J Am Coll Cardiol.* 2010;56(17):1357-65.
5. García Tejada J, Albarrán González-Trevilla A. Stents y trombosis. *Med Clin.* 2008;130(5):175-6.
6. Laskey WK, Yancy CW, Maisel WH. Thrombosis in coronary drug-eluting stent. Report From the Meeting of the Circulatory System Medical Devices Advisory Panel of the Food and Drug Administration Center for Devices and Radiologic Health, December 7-8, 2006. *Circulation.* 2007; 115(17):2352-7.
7. Takano M, Yamamoto M, Mizuno K. Two cases of coronary stent thrombosis very late after bare-metal stenting. *JACC Cardiovasc Interv.* 2009; 2(12):1286-7.

8. Soto G, Sepúlveda P, Donoso H, Puentes A, Bellet A, Albisa G, *et al.* Trombosis “extremadamente” tardía de stent. *Rev Chil Cardiol.* 2012;31(3):263-6.
9. Cuesta J, Rivero F, Bastante T, Benedicto A, Alfonso F. Ruptured "non-culprit" in-stent neoatherosclerosis during ST-segment elevation acute myocardial infarction. *EuroIntervention.* 2016; 12(10):1222.
10. Filgueiras Frías CE, Bestard Bicet R, Laria Menchaca S, López Ferrero L, Pérez del Todo JM, Villanueva Ponte LH. Trombosis muy tardía de stent convencional. Una sorpresa desagradable. *Rev Cubana Cardiol Cir Cardiovasc.* 2011;17(2): 180-5.