

## Incidence of the allergic acute coronary syndrome at the Hospital Mártires del 9 de Abril of Sagua La Grande in 2015

Yamir Santos Monzón<sup>1</sup>✉, MD; Álvaro T. González Marín<sup>2</sup>, MD, MSc; Yaritza Allouis Morales<sup>3</sup>, MD; and Sady H. Gutiérrez Fernández<sup>3</sup>, MD

<sup>1</sup> Department of Cardiology. Hospital Mártires del 9 de Abril. Sagua La Grande, Villa Clara, Cuba.

<sup>2</sup> Department of Allergy. Hospital Pediátrico de Sancti Spíritus. Sancti Spíritus, Cuba.

<sup>3</sup> Policlínico Comunitario Mario A. Pérez. Sagua La Grande, Villa Clara, Cuba.

*Este artículo también está disponible en español*

### ARTICLE INFORMATION

Received: November 10, 2017

Accepted: January 11, 2018

### Competing interests

The authors declare no competing interests

### Acronyms

ACS: acute coronary syndrome

AMI: acute myocardial infarction

ECG: electrocardiogram

### ABSTRACT

**Introduction:** The allergic angina, also known as Kounis syndrome, is a rarely diagnosed disease, although its accurate identification improves the prognosis of patients who suffer from it.

**Objective:** To characterize the profile of the disease in the environment of a municipal hospital.

**Method:** A descriptive and longitudinal study was conducted with 166 patients discharged with a diagnosis of acute coronary syndrome, at the Hospital Mártires del 9 de Abril of Sagua la Grande, Villa Clara, Cuba, between January 1<sup>st</sup> and December 31<sup>st</sup> of 2015. The variables evaluated were: age, sex, form of presentation, causes, complications, evolution and mortality of these patients.

**Results:** The 42.8% of patients had acute myocardial infarction and the remaining 57.2%, unstable angina. The male sex (54.2%) predominated and only 2 of a total of 166 patients (1.2%) were diagnosed with Kounis syndrome, both with unstable angina. These 2 patients experienced elevated eosinophils and immunoglobulin E, no complications, the regional motility disorders of the left ventricular returned before a month and no coronary lesions were found.

**Conclusions:** The Kounis syndrome, despite its low prevalence (1.2% in this research), is a condition that requires an accurate diagnosis and a specific treatment to improve the prognosis of these patients.

**Key words:** Kounis syndrome, Allergic reaction, Acute coronary syndrome, Diagnosis

### *Incidencia del síndrome coronario agudo alérgico en el Hospital Mártires del 9 de Abril de Sagua La Grande en 2015*

### RESUMEN

**Introducción:** La angina alérgica, conocida también como síndrome de Kounis, es una enfermedad raramente diagnosticada, aunque su identificación certera mejora mucho el pronóstico de los pacientes que la padecen.

**Objetivo:** Caracterizar el perfil de la enfermedad en el entorno de un hospital municipal.

**Método:** Se realizó un estudio descriptivo y longitudinal con los 166 pacientes egresados con el diagnóstico de síndrome coronario agudo, en el Hospital Mártires

✉ Y Santos Monzón  
Colón N° 172, Sagua la Grande  
CP 52310. Villa Clara, Cuba.  
E-mail address:  
yamirms@infomed.sld.cu

del 9 de Abril de Sagua La Grande, Villa Clara, Cuba, entre el 1 de enero y el 31 de diciembre de 2015. Se evaluaron las variables edad, sexo, forma de presentación, causas, complicaciones, evolución y mortalidad de dichos pacientes.

**Resultados:** El 42,8% de los pacientes tuvieron infarto agudo de miocardio y el 57,2% restante, angina inestable. Predominó el sexo masculino (54,2%) y solo 2 de un total de 166 pacientes (1,2%) fueron diagnosticados de síndrome de Kounis, ambos con angina inestable. Estos 2 enfermos experimentaron elevación de eosinófilos e inmunoglobulina E, no presentaron complicaciones, los trastornos de la motilidad regional del ventrículo izquierdo regresaron antes del mes y no se constataron lesiones coronarias.

**Conclusiones:** El síndrome de Kounis, a pesar de su baja prevalencia (1,2% en esta investigación), es una enfermedad que precisa de un diagnóstico certero y un tratamiento específico para mejorar el pronóstico de estos pacientes.

**Palabras clave:** Síndrome de Kounis, Reacción alérgica, Síndrome coronario agudo, Diagnóstico

## INTRODUCTION

Allergic angina was described in 1991 in a paper published by Kuonis and Zavras where they called attention to a vasospasm caused by the release of histamine and allergic mediators, which was associated with manifestations of angina and could even reach acute myocardial infarction (AMI)<sup>1,2</sup>. There was a precedent in this regard, when in 1950 Pfister *et al*<sup>3</sup> published, in the American Heart Journal, the case of a patient with AMI caused by or associated with an allergic reaction to penicillin.

Although it is known that the release of inflammatory mediators during mast cell degranulation is the root cause of this disease; they are also released –to a lesser extent– in non-allergic coronary syndromes.

There are many potential triggers for Kounis syndrome. The most frequent described in recent literature are: hymenoptera stings, drugs, adverse environmental exposures and food, without

ruling out other less common causes of anaphylaxis. Current scientific literature describes three subtypes: type I, without coronary disease; type II, with coronary disease; and type III, in patients suffering from drug-eluting stent thrombosis<sup>4</sup>.

## METHOD

A descriptive and longitudinal study was carried out with the 166 patients diagnosed with acute coronary syndrome (ACS) discharged from the *Hospital Mártires del 9 de Abril* in Sagua La Grande, Villa Clara,

Cuba, between January 1 and December 31, 2015.

The variables age, sex, presenting symptoms, causes, complications, outcome and mortality were assessed.

Only two cases were diagnosed as having an allergic cause during the study period, both with the diagnosis of unstable angina. During admission, absolute eosinophil count, immunoglobulin E, cardiac enzymes, electrocardiogram (ECG) and echocardiogram were performed to corroborate the diagnosis.

The cases diagnosed with Kounis syndrome were followed in the Department of Cardiology and stress test was performed at discharge (10-14 days) at three and six months after admission; a 24-day Holter ECG, and coronary angiography with a 128-slice Siemens Computed Tomography in the first three months. The patients were also followed-up and treated by Allergy specialists.

## RESULTS

In 2015, a total of 166 patients with ACS diagnosis were admitted to this hospital, 71 (42.8%) received a diagnosis of AMI –13 of whom died– and 95 (57.2%) of unstable angina (**Table 1**). Male sex predominated (54.2%) and only 2 cases were diagnosed with Kounis syndrome or allergic angina, which represents 1.2% of the cases studied.

In this study, a thorough etiological search was carried out that included the presence of a demonstrated allergen prior to the event, eosinophil increase in the early stage, increased immunoglobulin E (**Table**

**Table 1.** Hospital admissions due to ischemic heart disease and deaths in the year studied.

Type	Admissions		Total	Deceased		Total
	Male	Female		Male	Female	
AMI	48 (67.6)	23 (32.4)	71 (42.8)	8 (61.5)	5 (38.5)	13 (100)
Unstable angina	42 (44.2)	53 (55.8)	95 (57.2)	0 (0)	0 (0)	0 (0)
<b>Total</b>	90 (54.2)	76 (45.8)	166 (100)	8 (61.5)	5 (38.5)	13 (100)

Source: Medical Records from the Hospital Mártires del 9 de Abril. Sagua La Grande, Villa Clara, Cuba.  
Data express n (%)  
AMI, acute myocardial infarction.

**Table 2.** Cases of allergic angina and its main types on admission.

Cases	Age	Sex	Topography	Eosinophil count	Ig E	CPK-MB	Complications
Nº 1	38	Female	Anterior	↑ ↑ ↑	↑ ↑	↑	No
Nº 2	47	Male	High lateral	↑	↑ ↑	–	No

Source: Medical Records of patients with Kounis syndrome. Department of Cardiology, Hospital Mártires del 9 de Abril. Sagua La Grande, Villa Clara, Cuba.  
CPK-MB, creatine phosphokinase-MB fracción; Ig E, immunoglobulin E.

**Table 3.** Echocardiographic evolution of affected patients.

Echocardiogram	Admission	Discharge (10 days)	Discharge (30 days)
Case Nº 1	Important medial septal dyskinesia	Slight septomedial hypokinesia	No wall motion abnormalities
Case Nº 2	Light septal basal hypokinesia	No wall motion abnormalities	No wall motion abnormalities

Source: Medical Records of patients with Kounis syndrome. Department of Cardiology, Hospital Mártires del 9 de Abril. Sagua La Grande, Villa Clara, Cuba.

2), the search for acute allergy manifestations and the performance of echocardiograms on admission, discharge and monthly follow-up consultation (Table 3).

### Patient 1

Of the two cases associated with allergic ACS, the first was a 38-year-old woman from the municipality of Rancho Veloz, with a history of atopy, who started with marked chest tightness, hypotension, diaphoresis, pruritus and the presence of wheals scattered all over the chest, abdomen and extremities after receiving a diclofenac sodium injection. Once in the

Emergency Department of the clinic, she was administered intravenous diphenhydramine (20mg) and hydrocortisone (100mg), and significant anterior wall ST segment elevation was found (Figure 1), so sublingual nitroglycerin was added (three tablets of 0.5 mg). As pain and some of the accompanying symptoms persisted she was referred to our center where she was admitted to the Intensive Care Unit and ECG normalization was achieved 4 hours later (Figure 2). A history of allergy to another non-steroidal anti-inflammatory drug (metamizole sodium [dipyrone]) was recorded, which caused her angina when ingested, which is why she stopped using it. Eosinophil counts in the peripheral blood were very high at that time, in addition to the general manifestations

of acute atopy previously described.

She was given intravenous infusion of nitrates, which resulted in relief of symptoms and improvement of angina, and H<sub>1</sub> and H<sub>2</sub> antihistamines were associated, which contributed to rapidly improve the remaining symptoms.

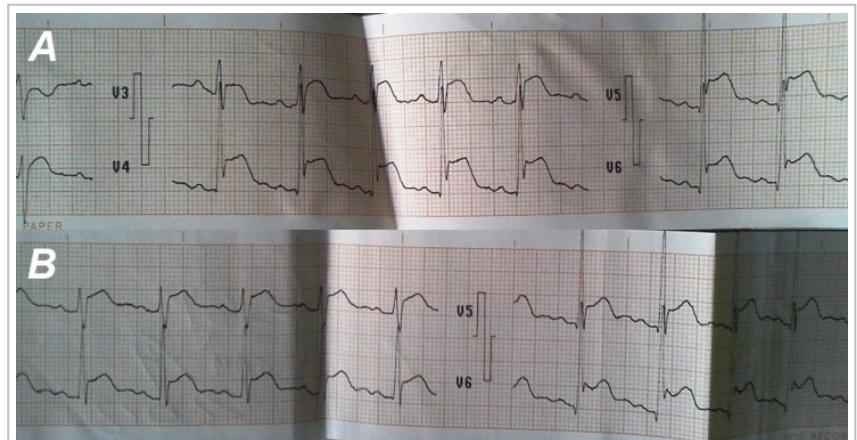
The patient remained in hospital for 7 days and then, given the improvement, it was decided to discharge her and include her in the protocol of patients with Kounis syndrome. A stress test was performed with negative results 14 days after the event; and later, a coronary angiography was coordinated, using a multislice computed tomography (Siemens, 128-slice) that showed normal coronary arteries. The 24-hour ECG was also negative. The patient was reevaluated at month three and six, remaining asymptomatic.

She was prescribed a verapamil 240 mg/day and clopidogrel 75 mg/day treatment to prevent vasospasm associated with a probable future cross-reaction. Follow-up was started by the Allergy Department, with environmental control measures, antihistamines and mast cell stabilizers.

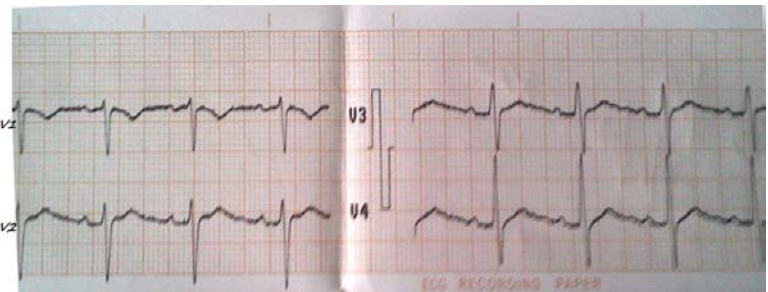
It was concluded that she suffered a type I allergic angina.

## Patient 2

The second case was a 47-year-old man (nursing graduate) from the Quemado de Güines municipality who started with a classic anginal pain after inhalation of gases from painting with a spray gun, accompanied by rash, itching, intense prickling and palpebral edema, which prompted him to present to the district clinic. He was administered nitroglycerin infusion which relieved the angina and decreased the ST alteration observed in the initial ECG (**Figure 3**), and also intravenously hydrocortisone (500 mg) and diphenhydramine (20 mg) which reduced the



**Figure 1.** Case 1. Electrocardiographic imaging showing significant anterior wall ST elevation. **A.** First medical assistance, in the clinic. **B.** At hospital admission.



**Figure 2.** Case 1. Normalization of the electrocardiogram 4 hours after admission to the Intensive Care Unit.

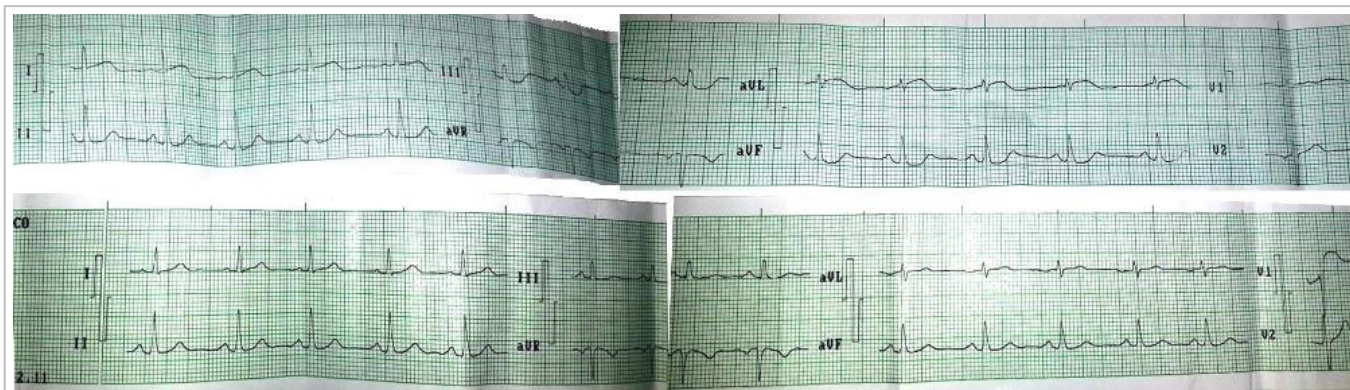
symptoms. He was immediately transferred to our center.

The formal follow-up for cases with probable diagnosis of Kounis syndrome was carried out. As his cardiovascular symptoms were of shorter duration, he underwent a stress test at discharge, Holter and coronary angiography with the same computed tomography of the first patient (Siemens, 128-slice). The absence of coronary artery disease was demonstrated, so the patient was also diagnosed as a type I Kounis syndrome.

The Department of Allergy was consulted, and H<sub>1</sub> antihistamines and mast cell stabilizers were associated with verapamil 240 mg/day and clopidogrel 75 mg/day prescribed on admission to the hospital.

In controls carried out in the outpatient setting at three, six and twelve months, both patients reported no symptoms and normal tests results (**Table 4**).





**Figure 3.** Case 2. Electrocardiographic imaging showing ST alterations (upper panel) and its normalization 2 hours later (lower panel).

**Table 4.** Seguimiento de la angina alérgica al egreso.

Cases	Stress test	Holter	Coronary CT	Symptoms	
				3 months	6 months
Caso Nº 1	Negative	Negative	Normal	Asymptomatic	Asymptomatic
Caso Nº 2	Negative	Negative	Normal	Asymptomatic	Asymptomatic

Source: Medical Records of patients with Kounis syndrome. Department of Cardiology, Hospital Mártires del 9 de Abril. Sagua La Grande, Villa Clara, Cuba.

## DISCUSSION

There is a lack of specific records of Kounis syndrome despite more and more frequent cases reported in the literature. Hence, we decided to conduct an exhaustive causal investigation of every ACS admitted in this center as we know the presence of this syndrome in our region.

The fact that there are no treatment guidelines for this condition, perhaps due to its recent approval as a specific nosological entity, motivated us to thoroughly follow-up patients in order to share our experiences.

One of the main issues in any disease is accurate diagnosis, which is difficult in this specific case as it is not frequent to unjustifiably associate the allergic cause to ACS. Most authors give greater importance to the typical clinical picture of pain. Although others describe atypical pain associated with allergic manifestations that may include urticaria, rash and bronchospasm, which can produce severe hypotension and altered alertness<sup>6</sup>. The most frequent electrocardiographic changes coincide with those found

in our small series: anterior wall ST segment elevation (less frequent in the posterior wall), although ST segment depression, nonspecific changes in repolarization, arrhythmias and even absence of electrocardiographic alterations have also been reported<sup>6,7</sup>.

Other important aspects to consider for diagnosis are the routine ACS tests, as well as others aimed at confirming its allergic cause: eosinophil count, immunoglobulin E and count of serum tryptase and histamine levels.

The echocardiogram is an important tool to support the diagnosis since the complete resolution of regional alterations in contractility found in the course of days or weeks is a highly valuable sign<sup>8,9</sup>.

Although the Kounis syndrome is gaining relevance in the medical literature, there is still no bibliography about its epidemiology; however, the FDA (Food and Drug Administration) has reported 262 cases of hypersensitivity to drug-eluting stent implantation. Seventeen of them have been Kounis syndromes and four of them died<sup>10</sup>.

At this time, we have not found any case in our province with the characteristics of the so-called

type III syndrome.

Helbling *et al*<sup>11</sup>, found an incidence of 0.02% in a Swiss regional population of 940 thousand inhabitants in 3 years, higher than the 0.001% of our research that involves an estimated population of 140000 inhabitants from three towns of the northern region in the province of Villa Clara (Cuba).

Only 2 from 166 patients (1.2%) were diagnosed with Kounis syndrome in our investigation. This reinforces the probable existence –described by other authors<sup>4,6,12</sup>– of a sub-registry of this disease in the medical statistics usually performed by the Emergency and Cardiology Departments. The ARIAM study<sup>12</sup>, although did not entirely define admissions as Kounis syndrome, found a group of causes among which was the aforementioned condition, which represented 4.6% of the sample studied<sup>12</sup>.

As there are no treatment guidelines for these patients, we followed the experts' advice and the expertise of the staff who assisted the patient. Mostly based on published experiences in isolated cases and small series. Most agree that, besides the usual treatment for ACS, strategies must be added to suppress the allergic reaction. This implies an additional risk because there are daily-use drugs for these purposes, such as adrenaline, which are contraindicated in uncomplicated ACS, because they may aggravate ischemia and induce vasospasm and arrhythmias<sup>12-14</sup>. We did not use it in our investigation since none of the two patients presented anaphylactic shock. However, when present, experts think it is necessary to take risks as it is the treatment of choice for anaphylaxis<sup>13,14</sup>.

Most authors consider the use of H<sub>1</sub> antihistamines as a second-line therapy. Lately, it is preferred to combine it with H<sub>2</sub> as it is more effective to eliminate allergic symptoms. In the first case of this investigation, anti H<sub>1</sub> and H<sub>2</sub> were used, due to the severity of symptoms. The patient responded favorably and the clinical picture improved. It has been suggested that their combination produces an increase in symptomatic control and constitutes the second-line treatment after adrenaline<sup>13,15</sup>. Moreover, their joint administration has proved to be more effective than the isolated use of H<sub>1</sub><sup>14</sup>.

Steroids have also been implemented. Although it was decided not to do it constantly in our case due to the risk of ventricular wall thinning and probable rupture, and cardiac aneurysms; despite the fact that many authors consider these claims to be inconclusive<sup>14</sup>. It is known that in cases of anaphylaxis oc-

curs a volume displacement to the interstitium, so fluid replacement is required. It must always be done carefully to prevent acute ventricular dysfunction and pulmonary edema as a result of such processes<sup>15</sup>.

In our experience, mast cell stabilizers have proved to be effective in preventing relapses of allergic symptoms in these patients, despite the limited evidence of their effectiveness in the review of the literature<sup>16-18</sup>.

Regarding pain relief, nitrates orally or intravenously have been shown to be effective in the acute phase<sup>19</sup>, although to avoid relapses and improve the ischemic profile of patients, it has been preferred to use calcium channel blockers. A procedure that some authors agree with, because this way the coronary vasospasm, which is the pathophysiological basis of the allergic angina, can be treated<sup>20,21</sup>. For this same reason beta-blockers have not been used in the cases of our research, since they can favor spasm by leaving vasoconstriction mediated by alpha activity unopposed by the absence of vasodilation mediated by beta activity. Besides, these drugs hinder the action of adrenaline in cases of anaphylaxis<sup>22</sup>.

On the other hand, the use of aspirin in these patients has also been limited in our center, since its association with allergic reactions has been described. Aspirin, due to its mechanism of action, may even aggravate a pre-existing anaphylaxis<sup>20</sup>. Instead, clopidogrel has been chosen, which is safe and effective in these patients<sup>14,23,24</sup>.

The patients have remained asymptomatic and with no recurrence with the established medical treatment after one-year follow-up, with a favorable outcome. Furthermore, they have been instructed to prevent exposure to the causative allergen, although –according to the literature consulted– recurrence of events is infrequent and with favorable outcome. Hence, serious complications and death are rare.

## CONCLUSIONS

Although recently described, the Kounis syndrome is being increasingly diagnosed, so the possibility of a sub-registration should be considered. That is why it is important to delve into the trigger of acute coronary syndromes to identify the allergic causes. De

spite its still low prevalence, Kounis syndrome requires an accurate diagnosis and a specific treatment to improve the prognosis of these patients.

## REFERENCES

1. Kounis NG, Zavras GM. Histamine-induced coronary artery spasm: The concept of allergic angina. *Br J Clin Pract.* 1991;45(2):121-8.
2. Kounis NG, Zavras GM. Allergic angina and allergic myocardial infarction. *Circulation.* 1996;94(7):1789.
3. Pfister CW, Plice SG. Acute myocardial infarction during a prolonged allergic reaction to penicillin. *Am Heart J.* 1950;40(6):945-7.
4. Pampín F, Rial Prado MJ, Vázquez Vigo R, González Guzmán LA. Síndrome coronario agudo por hipersensibilidad: Síndrome de Kounis. *Galicia Clin.* 2014;75(1):31-2.
5. Kounis NG, Soufras GD. Coronary stent thrombosis: Beware of an allergic reaction and of Kounis syndrome. *Indian Heart J.* 2014;66(2):153-5.
6. Bastante T, Rivero F, Cuesta J, Benedicto A, Restrepo J, Alfonso F. Nonatherosclerotic causes of acute coronary syndrome: Recognition and management. *Curr Cardiol Rep.* 2014;16(11):543.
7. Çeliker M, Tuncer M, Şekeralmaz A. A case with repeated recurrent acute coronary syndrome due to pseudoephedrine use: Kounis syndrome. *Case Rep Med [Internet].* 2014 [citado 31 Oct 2017]; 2014:742905. Disponible en: <https://www.ncbi.nlm.nih.gov/pmc/articles/PMC4243469/pdf/CRIM2014-742905.pdf>
8. Biteker M. Current understanding of Kounis syndrome. *Expert Rev Clin Immunol.* 2010;6(5):777-88.
9. Cha YS, Kim H, Bang MH, Kim OH, Kim HI, Cha K, *et al.* Evaluation of myocardial injury through serum troponin I and echocardiography in anaphylaxis. *Am J Emerg Med.* 2016;34(2):140-4.
10. Nebeker JR, Virmani R, Bennett CL, Hoffman JM, Samore MH, Alvarez J, *et al.* Hypersensitivity cases associated with drug-eluting coronary stents: A review of available cases from the Research on Adverse Drug Event and Reports (RADAR) Project. *J Am Coll Cardiol.* 2006;47(1):175-81.
11. Helbling A, Hurni T, Mueller UR, Pichler WJ. In-  
cidence of anaphylaxis with circulatory symptoms: A study over a 3-year period comprising 940.000 inhabitants of the Swiss Canton Bern. *Clin Exp Allergy.* 2004;34(2):285-90.
12. Latour-Pérez J, Cabello JB. Significado clínico del síndrome coronario agudo con elevación transitoria del segmento ST. *Med Intensiva.* 2011;35(5):267-9.
13. Cevik C, Nugent K, Shome GP, Kounis NG. Treatment of Kounis syndrome. *Int J Cardiol.* 2010;143(3):223-6.
14. Gómez Canosa MS, Castro Orjales MJ, Rodríguez Fariñas FJ, García Jiménez A, Gutiérrez Cortés JM. Tratamiento del síndrome de Kounis. *Med Intensiva.* 2011;35(8):519-20.
15. Cardona Dahl V, Cabañes Higuero N, Fernández Rivas MM, Freijó Martín C, Guardia Martínez P, de la Hoz Caballer B, *et al.* Guía de actuación en anafilaxia. *Med Clin (Barc).* 2011;136(8):349-55.
16. Doğan V, Mert GÖ, Biteker FS, Mert KU, Biteker M. Treatment of Kounis syndrome. *Int J Cardiol.* 2015;181:133-4.
17. Domínguez Franco AJ, Gómez Doblas JJ, García Pinilla JM, Hernández García JM, Jiménez Navarro M, Alonso Briales JH, *et al.* Treatment of refractory vasoospastic angina with corticosteroids. A case report. *Int J Cardiol.* 2007;118(2):e51-3.
18. Takagi S, Goto Y, Hirose E, Terashima M, Sakuragi S, Suzuki S, *et al.* Successful treatment of refractory vasospastic angina with corticosteroids: Coronary arterial hyperactivity caused by local inflammation? *Circ J.* 2004;68(1):17-22.
19. Lieberman P, Nicklas RA, Oppenheimer J, Kemp SF, Lang DM, Bernstein DI, *et al.* The diagnosis and management of anaphylaxis practice parameter: 2010 update. *J Allergy Clin Immunol.* 2010;126(3):477-80.e1-42.
20. Villamil-Munévar PA, Sánchez-Solanilla LF. Síndrome de Kounis o angina alérgica. *Rev Colomb Cardiol.* 2017;24(4):382-7.
21. Santos Monzón Y, Pérez González JA, Mata Cuevas A, Rivero Nóbrega Y, Roque Corzo JJ. Un caso de síndrome de Kounis en Sagua La Grande. *CorSalud [Internet].* 2014 [citado 31 Oct 2017]; 6(2):201-4. Disponible en: <http://www.revcorsalud.sld.cu/index.php/cors/article/view/170/391>
22. Roffi M, Patrono C, Collet JP, Mueller C, Valgimigli M, Andreotti F, *et al.* Guía ESC 2015 sobre el tratamiento de los síndromes coronarios agudos en pacientes sin elevación persistente del segmento

- ST. Rev Esp Cardiol. 2015;68(12):1125.e1-e64.
23. Felices-Abad F, Latour-Pérez J, Fuset-Cabanes MP, Ruano-Marco M, Cuñat-de la Hoz J, del Nogal-Sáez F, *et al.* Indicadores de calidad en el síndrome coronario agudo para el análisis del proceso asistencial pre e intrahospitalario. Med Intensiva. 2010;34(6):397-417.
24. Kushner FG, Hand M, Smith SC, King SB, Anderson JL, Antman EM, *et al.* 2009 Focused Updates: ACC/AHA Guidelines for the Management of Patients With ST-Elevation Myocardial Infarction (updating the 2004 Guideline and 2007 Focused Update) and ACC/AHA/SCAI Guidelines on Percutaneous Coronary Intervention (updating the 2005 Guideline and 2007 Focused Update): a report of the American College of Cardiology Foundation/American Heart Association Task Force on Practice Guidelines. Circulation. 2009;120(22):2271-306.