


Importance of atrioventricular synchrony for cardiac output in a patient with heart failure and reduced ejection fraction

Marcelo V. Puga Bravo , MD; and Yisel Gallardo Medina, MD

Department of Cardiology, Instituto de Cardiología y Cirugía Cardiovascular. La Habana, Cuba.

Este artículo también está disponible en español

ARTICLE INFORMATION

Received: October 18, 2018
Accepted: November 1, 2018

Competing interests

The authors declare no competing interests

Acronyms

AV: Atrioventricular
MBP: Mean blood pressure

ABSTRACT

An 80-year-old male patient is presented, with previous dilated cardiomyopathy of ischemic etiology, with systo-diastolic left ventricular dysfunction, who initially presented atrial flutter and hemodynamic instability, thus, an electrical cardioversion was performed. After this procedure, a blocked atrial fibrillation was observed. Thus, an external pacemaker was placed. During the evolution, a 12 lead electrocardiogram was performed, showing permanent ventricular stimulation with retrograde conduction (ventriculo-atrial). The pacing rate was diminished for prioritizing the patient's spontaneous rhythm resulting in an improvement of the blood pressure curve.


Keywords: Heart conduction system, Retrograde conduction, Atrial function, Artificial cardiac pacing, Pacemaker syndrome

Importancia de la sincronía aurículo-ventricular para el gasto cardíaco en un paciente con insuficiencia cardíaca y fracción de eyección reducida

RESUMEN

Hombre de 80 años de edad, con antecedentes de miocardiopatía dilatada de origen isquémico, con disfunción sisto-diastólica del ventrículo izquierdo, que inicialmente presentó flutter auricular con inestabilidad hemodinámica y se realizó cardioversión eléctrica, luego de la cual se obtuvo un ritmo no precedido de onda P a 40 latidos por minuto, que fue interpretado como fibrilación auricular bloqueada; razón por la que se le colocó un marcapasos externo. Durante su evolución se realizó electrocardiograma de 12 derivaciones, donde se evidenció estimulación ventricular permanente con conducción retrógrada (ventrículo-auricular). Se disminuyó la frecuencia de estimulación para priorizar el ritmo espontáneo del paciente y se obtuvo marcada mejoría de la curva de presión arterial.

Palabras clave: Sistema de conducción cardíaco, Conducción retrógrada, Función atrial, Estimulación cardíaca artificial, Síndrome de marcapasos

 M Puga Bravo
Instituto de Cardiología y Cirugía
Cardiovascular. Calle 17 N° 702.
Vedado, CP 10400. La Habana, Cuba.
Correo electrónico:
marcelopuga@hotmail.es

INTRODUCTION

During the cardiac cycle, at the end of the diastole and immediately before the systole is triggered, the atrium contracts, which drives a quantity of blood towards the ventricle that significantly increases the volume of ven-

tricular ejection. In order to achieve the maximum contribution, it is necessary that the moment of electrical activation of the atrium is in perfect synchrony with the moment when the ventricular contraction begins. The coordination between the electrical activation of the atrium and ventricle, and mechanical contraction is called atrioventricular (AV)¹ synchrony. The existence of an optimal AV synchrony can increase the cardiac output between 25 and 30%. Patients with diastolic or systolic functioning abnormalities are especially dependent on this atrial contribution¹.

CASE REPORT

The case of an 80-year-old man is presented, who went to the emergency department with palpitations, severe dyspnea and marked decay. The patient's history revealed previous non-reperfused myocardial infarctions of anterior and inferior walls since 1 and 19 years ago, respectively; besides high blood pressure and controlled dilated cardiomyopathy of ischemic origin, with left ventricle ejection fraction (LVEF) slightly reduced (42%). It was interpreted as a case of acute heart failure (AHF) and hypotension (80/50 mmHg) and an 12-lead electrocardiogram was carried out, where a tachycardia with wide QRS was observed, regular, 150 beats per minute (bpm), F wave, whereby a flutter atrial plus a right bundle branch block (basal pattern) with hemodynamic instability was diagnosed; a reason for performing the synchronous cardioversion, after which was observed a regular rhythm of 40 bpm, right bundle branch block, and absence of P waves, which was interpreted as blocked atrial fibrillation, for which an external pacemaker VVI mode was placed, at 80 bpm heart rate.

With the patient still in low cardiac output and important respiratory failure, the invasive mechanical ventilation and infusion of inotropic (dopamine) and vasopressors (norepinephrine) was started, hence that ac-

ceptable pressure values (90/50 mmHg) and a mean blood pressure (MBP) of 63 mmHg were obtained. In subsequent blood gases, a metabolic acidosis and hyperkalemia of difficult control were observed, to which marked oliguria was added. Due to the hemodynamic and respiratory instability, and frank picture of low cardiac output he was transferred to the intensive care unit, where –at his arrival– one issue called the attention during the physical examination, among other things, the presence of regular cannon A waves. An electrocardiogram (**Figure 1**) was carried out, where a permanent pacemaker stimulation was observed at 80 bpm, with retrograde conduction (P wave following each QRS complex).

Finding this atrioventricular conduction, causing cannon A waves, the current diagnosis of blocked atrial fibrillation was discarded, thus, the pacing rate of the pacemaker was decreased to 40 bpm and he obtained a regular sinus rhythm at 70 bpm, with right bundle branch block. Immediately, the described A waves, disappeared, and a significant increase in blood pressure of 100/59 mmHg (MBP 72 mmHg) to 137/65 mmHg (MBP 89 mmHg) was evidenced. Concomitantly, with the use of diuretics, inotropics, vasopressors, modification of ventilatory parameters and corrections of the internal environ-

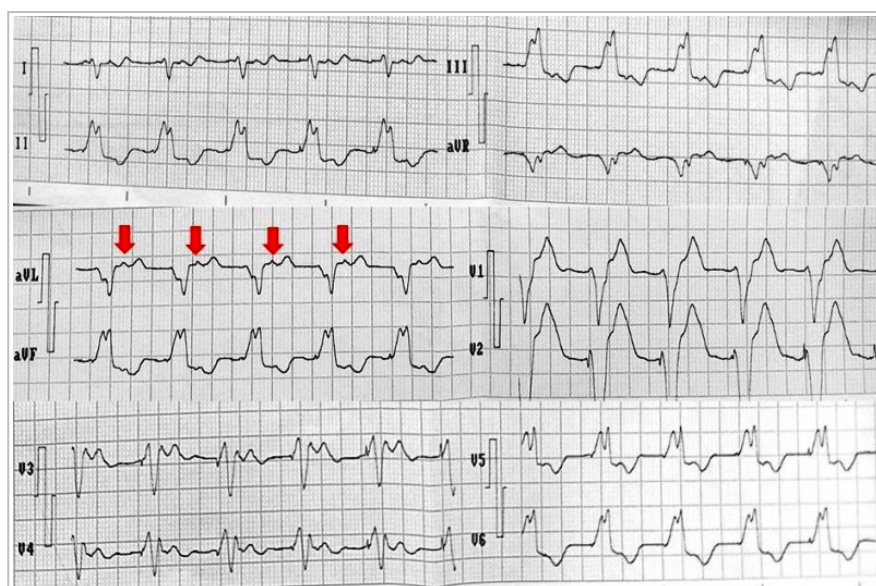


Figure 1. Electrocardiogram showing ventricular pacing using an external pacemaker. Note the electrocardiographic tracing with spikes preceding wide QRS complexes with morphology of left bundle branch block, typical of the right ventricular pacing, and the presence of P waves following the QRS complex (atrioventricular retrograde conduction), easily visible in the aVL lead (arrows).

ment, in the following three hours, the diuresis improved from 0.09 to 2.3 ml/kg/h, the pH increased from 7.30-7.40 and the potassium decreased from 8 to 4.5 mEq/L.

In the **figure 2** if shown the variation in the monitoring parameters of this patient with and without ventricular pacing using a pacemaker. Subsequently, a transthoracic echocardiogram showed necrosis in the anterior and inferior walls, a left ventricular ejection fraction of 37% and a 10 mm tricuspid annular plane systolic excursion (TAPSE); in addition to a grade II diastolic dysfunction with elevated pressure in the left atrium.

COMMENTS

During the cardiac cycle, the atria have two main functions, one of transport and the other of reservoir. Like the ventricles, the atria respond to an increase in the length of the fiber with an increase in the force of contraction and, at rest, atrial contraction contributes in a 25-30% to ventricular filling^{1,2}.

Two of the main mechanisms responsible for the loss of the contribution of atrial contraction to cardiac output coincidentally took place in this case. The first is the loss of the atrial systole secondary to supraventricular arrhythmias, including the atrial flutter. The second mechanism is due to the so-called pacemaker syndrome that can present with AV dissociation or AV 1:1 association that results in an adverse ventricular and atrial contraction sequence. The relationship between the AV activation times that most affect hemodynamics takes place during ventricular stimulation with retrograde conduction (atrioventricular), which produces a reverse synchrony (VA) with atrial contraction, while the mitral and tricuspid valves are closed, which causes a venous regurgitation (cannon A waves), with alteration in the ventricular filling and atrial distention³, as happened in this case.

Although it has been demonstrat-

ed that the AV synchrony is important to maintain a normal cardiac physiology in all types of patients, it is even more significant in those with systolic and diastolic ventricular dysfunction. Several studies have shown that, in patients with decreased diastolic compliance of the left ventricle of any cause, synchronous atrial systole increases the end-diastolic volume, end-diastolic pressure and systolic volume by 15, 30 and 35%^{4,5}. These hemodynamic changes increase the systolic blood pressure up to 50 mmHg, in this case the systolic blood pressure increased 37 mmHg.

The importance of the AV synchrony in the ventricular filling in a patient with heart failure and a decreased ejection fraction is thus noticed, which developed an important hemodynamic deterioration when losing the contribution of the atrial contraction to cardiac output, in the first place, due to the presence of an atrial flutter and subsequently, by developing a pacemaker syndrome with retrograde conduction.

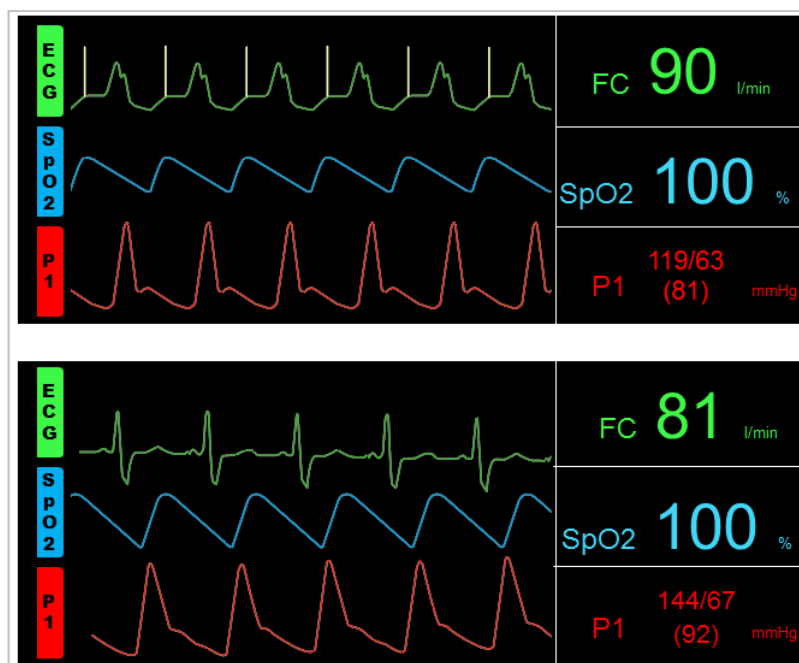


Figure 2. Variation curve of invasive blood pressure with and without using external pacemaker in a patient with heart failure and reduced ejection fraction.

Upper panel: Monitoring with fixed stimulation of the pacemaker at 90 bpm. Lower panel: Monitoring of the same patient when turning off the external pacemaker, and a sinus rhythm is obtained at 81 bpm. Note an arterial curve that increases in width and raises the diastolic notch; in addition, there is an increase in the systolic and mean blood pressure of 35 and 11 mmHg, respectively.

REFERENCES

1. Swerdlow CD, Wang PJ, Zipes DP. Marcapasos y desfibriladores automáticos implantables. En: Mann DL, Zipes DP, Libby P, Bonow RO, eds. Braunwald. Tratado de Cardiología. Texto de Medicina Cardiovascular. Philadelphia: Elsevier; 2016. p. 721-47.
2. Wiggers CJ, Katz LN. The contour of the ventricular volume curves under different conditions. *Am J Physiol.* 1922;58:439-75.
3. Erlebacher JA, Danner RL, Stelzer PE. Hypotension with ventricular pacing: an atria vasodepressor reflex in human beings. *J Am Coll Cardiol.* 1984;4(3):550-5.
4. Rene A, Génereux P, Ezekowitz M, Kirtane D, Xu K, Mehran R, *et al.* Impact of atrial fibrillation in patients with ST-elevation myocardial infarction treated with percutaneous coronary intervention (from the HORIZONS-AMI [Harmonizing Outcomes With Revascularization and Stents in Acute Myocardial Infarction] trial). *Am J Cardiol.* 2014;113(2):236-42.
5. Romero JD, Lezáun R, Maraví C, Ruiz V, García J, de los Arcos E. Relación entre la sincronía auriculoventricular y la presión sistémica. *Rev Esp Cardiol.* 2001;54(2):234-5.