

## Cor triatriatum sinister. Apropos of a case

Luis M. de la Torre Fonseca<sup>1</sup>✉, MD; Anabel Pérez Fernández<sup>1</sup>, MD; Sheila Hechevarría Pouymino<sup>2</sup>, MD; and Std. María K. Hidalgo Sablón<sup>3</sup>

<sup>1</sup> Coronary Intensive Care Unit, Hospital Clínico Quirúrgico Manuel Fajardo. Havana, Cuba.

<sup>2</sup> Department of Echocardiography, Instituto de Cardiología y Cirugía Cardiovascular. Havana, Cuba.

<sup>3</sup> Universidad de Ciencia Médicas de la Habana, Facultad Manuel Fajardo. Havana, Cuba.

*Este artículo también está disponible en español*

### ARTICLE INFORMATION

Recibido: July 11, 2018  
Accepted: August 17, 2018

### Competing interests

The authors declare no competing interests

### Acronyms

CT: *cor triatriatum*

HR: heart rate

### ABSTRACT

*Cor triatriatum* is a rare congenital defect, (estimated incidence of 0.1% of all patients with congenital heart diseases). The atrium is divided into two compartments by a fibromuscular membrane; a proximal and a distal chamber that communicate with each other through two or more perforations with varying degrees of obstruction. It is more commonly found in the left atrium (*cor triatriatum sinister*) and usually diagnosed in childhood or during adulthood, often incidentally by a routine echocardiogram. Clinical symptoms in this rare disease depend on the severity of obstruction of the membrane in the atrium, as well as the associated congenital heart diseases.

**Keywords:** *Cor triatriatum*, Left atrium, Junctional rhythm

### *Cor triatriatum sinister. A propósito de un caso*

### RESUMEN

*El cor triatriatum es una anomalía congénita rara. Su prevalencia es de un 0,1% entre todos los pacientes con cardiopatías congénitas. La aurícula queda dividida en dos partes por una membrana fibromuscular; una cámara proximal y otra distal que se comunican entre sí por dos o más orificios con distintos grados de obstrucción. Es más frecuente encontrarlo en la aurícula izquierda (cor triatriatum sinister). Se diagnostica generalmente en la infancia o durante la edad adulta, muchas veces de manera fortuita mediante un ecocardiograma de rutina. Las manifestaciones clínicas en esta rara enfermedad dependerán del grado de obstrucción de la membrana en la aurícula, así como de las cardiopatías congénitas asociadas.*

**Palabras clave:** Corazón triatrial, Aurícula izquierda, Ritmo de la unión

### INTRODUCTION

Cor triatriatum (CT) literally means heart with three atria. It was first described by Church in 1868 and years later, in 1905, Boch made a more detailed description of this malformation. Since its discovery and to date, it has been considered a rare congenital anomaly, with a prevalence of 0.1% among all patients with congenital heart disease<sup>1,2</sup>.

✉ LM de la Torre Fonseca  
Hospital Manuel Fajardo. Servicio de  
Cuidados Coronarios Intensivos.  
Calle D esq. a Zapata. Plaza de la  
Revolución CP 10400. La Habana,  
Cuba. E-mail address:  
marianotorre@infomed.sld.cu

In CT the atrium is divided into two parts by a fibromuscular membrane; a proximal chamber and a distal chamber that communicate with each other through two or more holes with different degrees of obstruction<sup>3</sup>. It is more commonly found in the left atrium (*cor triatriatum sinister*) and generally associated with other congenital cardiac defects, such as atrial septal defect, tetralogy of Fallot, atrio-ventricular canal, coarctation of the aorta and partial anomalous pulmonary venous connection<sup>4</sup>.

*Cor triatriatum dexter* (right atrium) is less frequent, with an incidence of 0.025% of congenital heart diseases, and its presentation as a single disease is uncommon<sup>5</sup>.

Several hypotheses have been proposed to explain the morphogenesis of this infrequent anomaly. The first one refers to a supposed abnormal septation within the atrium from an anomalous development of the interatrial septum. Meanwhile, the second and most accepted at present is based on the theory that the responsible for this defect is a wrong incorporation of the common pulmonary vein inside the atrium<sup>6</sup>, resulting from an incomplete absorption during the embryogenic period of the mentioned vein<sup>7</sup>.

It is usually diagnosed in childhood or during adulthood, often by chance using a routine echocardiogram. The clinical manifestations in this rare disease will depend on the degree of obstruction of the

membrane in the atrium, as well as associated congenital heart diseases<sup>8,9</sup>.

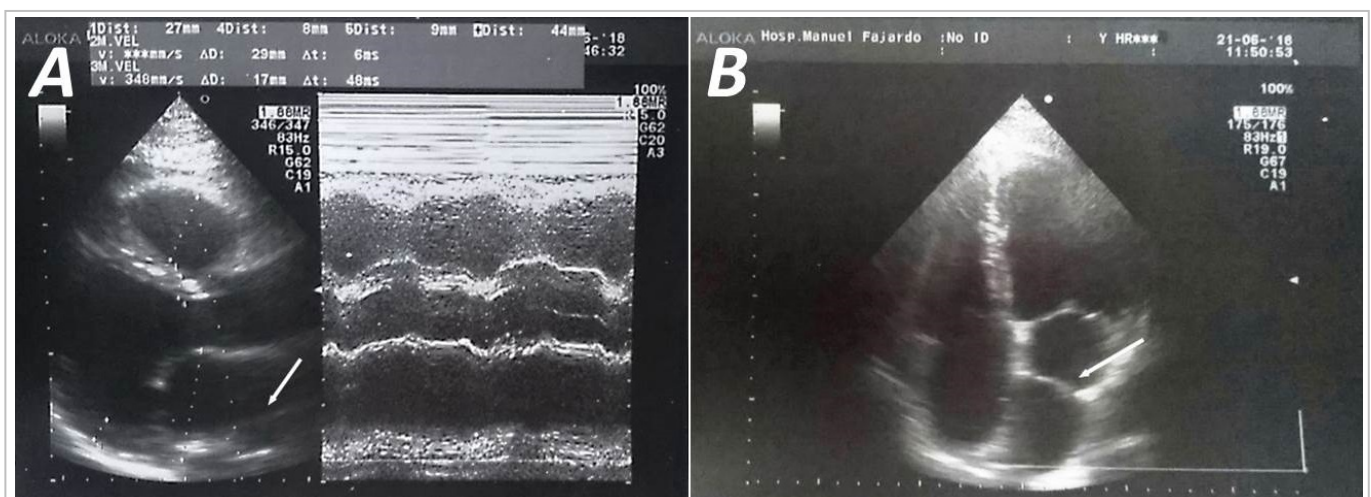
## CASE REPORT

A 45-year-old man apparently with no past medical history of note presented to the consultation with palpitations started more than 72 hours ago. Physical examination revealed a tachycardic and arrhythmic heart rhythm; there were no cardiac murmurs on auscultation. A 12-lead electrocardiogram (ECG) was performed and showed absence of P waves, with irregular RR, normal electrical axis and heart rate (HR) of 145 beats per minute, consistent with atrial fibrillation with rapid ventricular response.

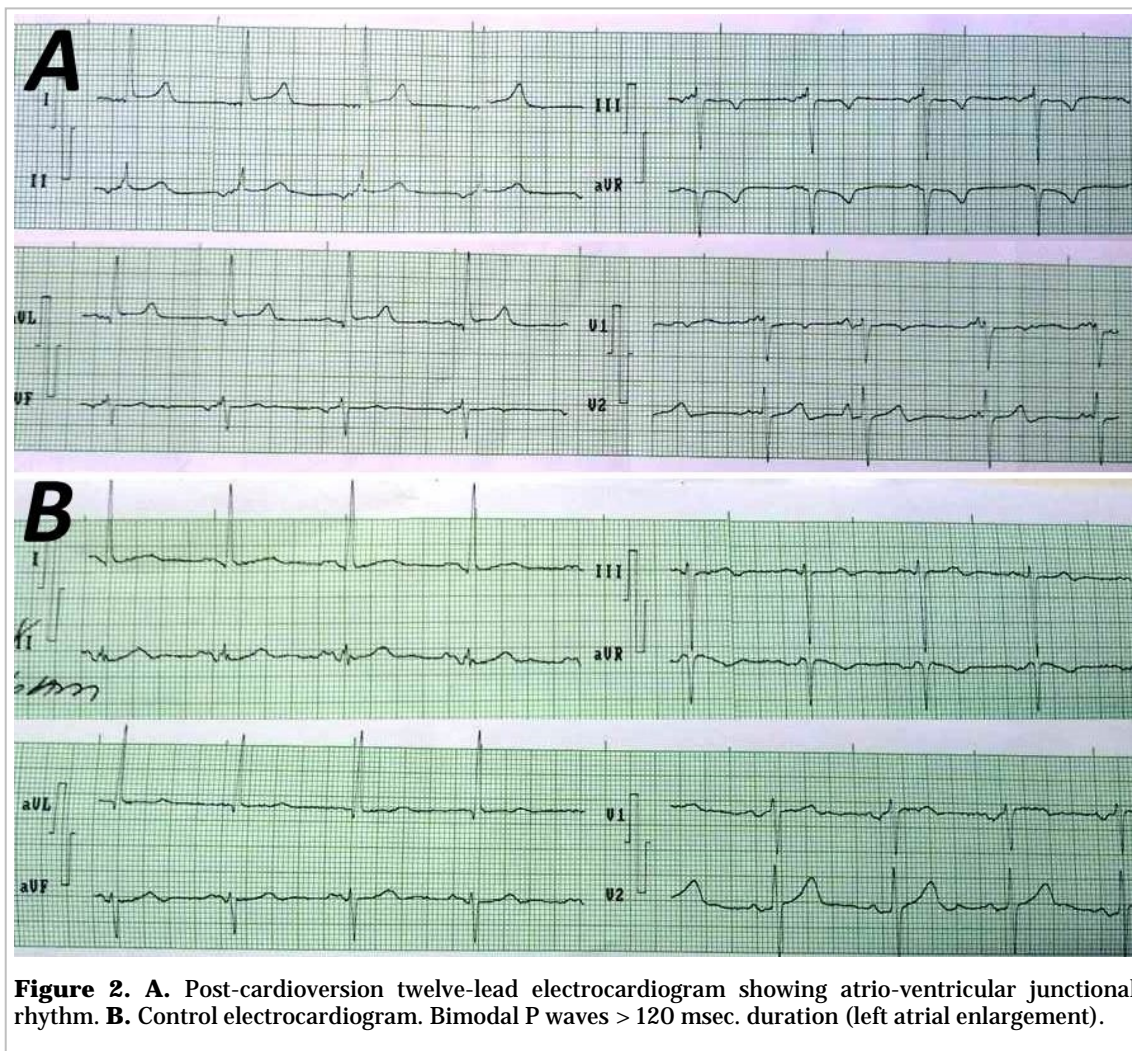
Once in the Emergency Department, he was administered intravenous verapamil (5 mg) and his HR was controlled; he was started on the same drug (80 mg every 8 hours), oral anticoagulation with warfarin (5 mg. mg/day) and subsequently discharged.

Following transthoracic echocardiogram confirmed the presence of a membrane dividing the left atrium into two sections; one proximal and another distal to the mitral valve (**Figure 1**) and an opening connecting both cavities.

After three weeks of INR of 2.5 anticoagulation therapy and verapamil to control HR, electrical car-



**Figure 1.** Transthoracic echocardiogram showing the *cor triatriatum sinister*. **A.** parasternal long-axis view. **B.** Apical four-chamber view. Image shows the membrane dividing the left atrium (arrows). Right ventricular end-diastolic diameter: 27 mm, Aorta: 29 mm, aortic valve opening: 17 mm, left atrium: 44 mm, left ventricular diastolic/systolic diameter: 54/36 mm, ejection fraction: 61%, area of the left atrium: 26 cm<sup>2</sup>, volume: 76 ml.



**Figure 2. A.** Post-cardioversion twelve-lead electrocardiogram showing atrio-ventricular junctional rhythm. **B.** Control electrocardiogram. Bimodal P waves > 120 msec. duration (left atrial enlargement).

dioversion was performed after sedation with propofol. A discharge of 150 joules was applied and junctional rhythm occurred (**Figura 2A**) without complications. After 30 minutes of recovery in the Coronary Intensive Care Unit at Hospital Manuel Fajardo, he was finally discharged.

On monthly follow-up, patient was asymptomatic and denied episodes of palpitations or dyspnea. The presence of bimodal P waves of 200 msec was observed on a control electrocardiogram (**Figura 2B**) compatible with left atrial growth, very common in patients with CT.

The patient was started on (200 mg/day) amiodarone for rhythm control, after impregnation, and oral anticoagulation with warfarin was maintained.

## COMMENT

Cor triatriatum is an infrequent anomaly and it is rare for patients to exceed 40 years without surgical correction. The left atrium is divided by a fibromuscular membrane into two compartments.

The classic form describes the existence of a postero-superior location chamber, where the pulmonary veins drain (upper cavity or pulmonary vein cavity); while the antero-inferior chamber remains in contact with the atrio-ventricular valve (atrial or true cavity)<sup>10</sup>.

For CT diagnosis, it is essential to take into account that the atrial cavity must present the left atrial appendage and the true interatrial septum<sup>7</sup>. Echocardiographic signs of atrial growth, as well as disor-



ders of normal sinus rhythm tend to appear during its natural evolution, a consequence of the physiological and cellular alterations of atrial tissue.

Among the multiple classifications proposed, one of the most used and simplest is that of Loeffler<sup>11</sup>. This author divides CT into three types, according to the degree of obstruction caused by the defect:

- Type I: no opening in the accessory membrane.
- Type II: one or more small restrictive openings (fenestrations)
- Type III: nonrestrictive opening in the membrane (only broad fenestration that communicates both cavities).

It is important to highlight that 75% of patients are diagnosed in neonatal age, mainly due to its relationship with other congenital anomalies. The natural history of CT in patients diagnosed in adulthood is unknown<sup>12</sup>. They are usually asymptomatic until the onset of signs or symptoms of heart failure, such as dyspnea or episodes of palpitations.

In the same way that atrial fibrillation was found in our patient, supraventricular tachycardias are the most frequent in CT. This tachycardia is thought to be related to atrial malformations that occur in this disease, which affects the production and propagation of the electrical impulse from the atrial tissue. By the beginning of the 1990s, only about 250 cases had been diagnosed worldwide. However, with the improvement of imaging techniques and the frequent use of echocardiography, diagnosis is more frequent<sup>13</sup>.

Transthoracic or transesophageal echocardiography, and the recent use of three-dimensional echocardiography, constitute the cornerstone in the diagnosis, follow-up and stratification of patients with CT<sup>14</sup>. However, other imaging techniques such as computed tomography, magnetic resonance imaging and cardiac catheterization, useful for diagnosis and follow-up in this group of patients, can be used.

## CONCLUSIONS

As usual among cases with CT that reach adulthood, our patient remained asymptomatic and the diagnosis was incidental when the presence of a type II CT according to the Loeffler classification with a perforated membrane without hemodynamic repercussion was confirmed. Outcome in patients with un-

corrected cor triatriatum is unknown to date. At present, control of the main symptoms and complications, such as supraventricular tachycardias, seems to be the most viable alternative.

## REFERENCES

1. Varma PK, Warriar G, Ramachandran P, Neema PK, Manohar SR, Titus T, *et al.* Partial atrioventricular canal defect with cor triatriatum sinister: report of three cases. *J Thorac Cardiovasc Surg.* 2004;127:572-3.
2. Thakrar A, Shapiro MD, Jassal DS, Neilan TG, King ME, Abbara S. Cor triatriatum: the utility of cardiovascular imaging. *Can J Cardiol.* 2007;23(2):143-5.
3. Barbaglia FG, Casanova MJ, Araujo RA, Tazar JI. Cor triatriatum sinister. A propósito de un caso. *Insuf Card.* 2010;5(1):42-7.
4. Marín-García J, Tandon R, Lucas RV, Edwards JE. Cor triatriatum: study of 20 cases. *Am J Cardiol.* 1975;35(1):59-66.
5. Sánchez-Brotons JA, López-Pardo FJ, Rodríguez-Puras MJ, López-Haldó JE. Cor triatriatum dexter en la edad adulta. *Rev Esp Cardiol.* 2010;63(8):998-9.
6. Edwin F, Gyan B, Tettey M, Aniteye E. Divided left atrium (cor triatriatum) in the setting of common atrium. *Ann Thorac Surg.* 2012;94(2):e49-50.
7. Van Praagh R, Corsini I. Cor triatriatum: pathologic anatomy and a consideration of morphogenesis based on 13 postmortem cases and a study of normal development of the pulmonary vein and atrial septum in 83 human embryos. *Am Heart J.* 1969;78(3):379-405.
8. Saxena P, Burkhart HM, Schaff HV, Daly R, Joyce LD, Dearani JA. Surgical repair of cor triatriatum sinister: the Mayo Clinic 50-year experience. *Ann Thorac Surg.* 2014;97(5):1659-63.
9. Zepeda IA, Morcos P, Castellanos LR. Cor triatriatum sinister identified after new onset atrial fibrillation in an elderly man. *Case Rep Med [Internet].* 2014 [citado 30 Jun 2018];2014:674018. Disponible en: <https://www.ncbi.nlm.nih.gov/pmc/articles/PMC4295417/pdf/CRIM2014-674018.pdf>
10. Webb GD, Smallhorn JF, Therrien J, Redington AN. Cardiopatías congénitas. En: Bonow RO, Mann DL, Zipes DP, Libby P, Braunwald E, Eds.

Braunwald Tratado de Cardiología: Texto de medicina cardiovascular. 9ª ed. Barcelona: Elsevier España; 2013. p. 1429-87.

11. Loeffler E. Unusual malformation of the left atrium; pulmonary sinus. Arch Pathol (Chic). 1949; 48(5):371-6.
12. Slight RD, Nzewi OC, Buell R, Mankad PS. Cor triatriatum sinister presenting in the adult as mitral stenosis: an analysis of factors which may be relevant in late presentation. Heart Lung Circ. 2005;14(1):8-12.
13. Einav E, Perk G, Kronzon I. Three-dimensional transthoracic echocardiographic evaluation of cor triatriatum. Eur J Echocardiogr. 2008;9(1):110-2.