

“De Winter” electrocardiographic pattern as equivalent to ST-segment elevation myocardial infarction

Patrón electrocardiográfico de «de Winter» como equivalente a síndrome coronario agudo con elevación del ST

Daniel Meseguer González[✉], MD; Jorge Melero Polo, MD; Sara Río Sánchez, MD; and Pablo Revilla Martí, MD

Department of Cardiology, Hospital Clínico Universitario Lozano Blesa. Zaragoza, España.

Este artículo también está disponible en español

Keywords: Electrocardiography, Acute coronary syndrome, Myocardial infarction, de Winter ECG pattern
Palabras Clave: Electrocardiograma, Síndrome coronario agudo, Infarto de miocardio, Patrón de «de Winter»

A 51-year-old man, without known allergies and no history of interest, came to his Health Center with non-irradiated, oppressive chest pain and vagal reaction, of 30 minutes' duration, which started while walking and persisted at rest. An electrocardiogram was performed (**Figure 1**) due to such findings, and he was referred to this hospital for emerging cardiac catheterization. The coronary angiography showed an acute thrombotic occlusion at the level of the proximal left anterior descending artery (**Figure 2A**, arrow) which was treated with thrombectomy and drug-eluting stent implantation (**Figure 2B**). The patient presented torpid evolution, he developed systolic dysfunction and apical aneurysm with thrombus inside, thus, he required -at discharge- dual antiplatelet therapy and anticoagulation. The electrocardiogram is the main diagnostic tool in order to decide what action to take in presence of an acute coronary syndrome at the emergency room,

because it allows to identify patients who benefit from urgent revascularization. Recent guidelines recommend emergent coronary angiography (less than 2 hours) in patients with anginal chest pain and persistent and significant ST-segment elevation in two or more contiguous leads. The electrocardiographic pattern of “de Winter”, described in 2008 by Robbert J. Winter *et al* (N Engl J Med. 2008;359:2071-3), is present in 2% of the acute anterior wall myocardial infarctions. It is characterized by the fact that, despite not having an ST-segment elevation, it is associated with an acute occlusion of the proximal left anterior descending artery. This pattern consists of a J point depression greater than one millimeter, followed by an ascending ST-segment that continues with high and symmetrical T waves in anterior leads. Although this T wave pattern is considered a sign of hyperacute ischemia that precedes the ST-segment elevation, the T waves of the “de Winter” pattern remain during the course of pain. It is very important to know and identify the electrocardiographic pattern given its prognostic implications, because it is associated with an injury involving a large percentage of myocardium territory at risk, which forces to consider it as if it was an ST-segment elevation myocardial infarction; therefore, a coronary angiography must be urgently performed.

✉ D Meseguer González
Servicio de Cardiología
Hospital Clínico Universitario “Lozano Blesa”.
Avda. San Juan Bosco, 15, 50009. Zaragoza, España.
E-mail address: dmesequer92@gmail.com

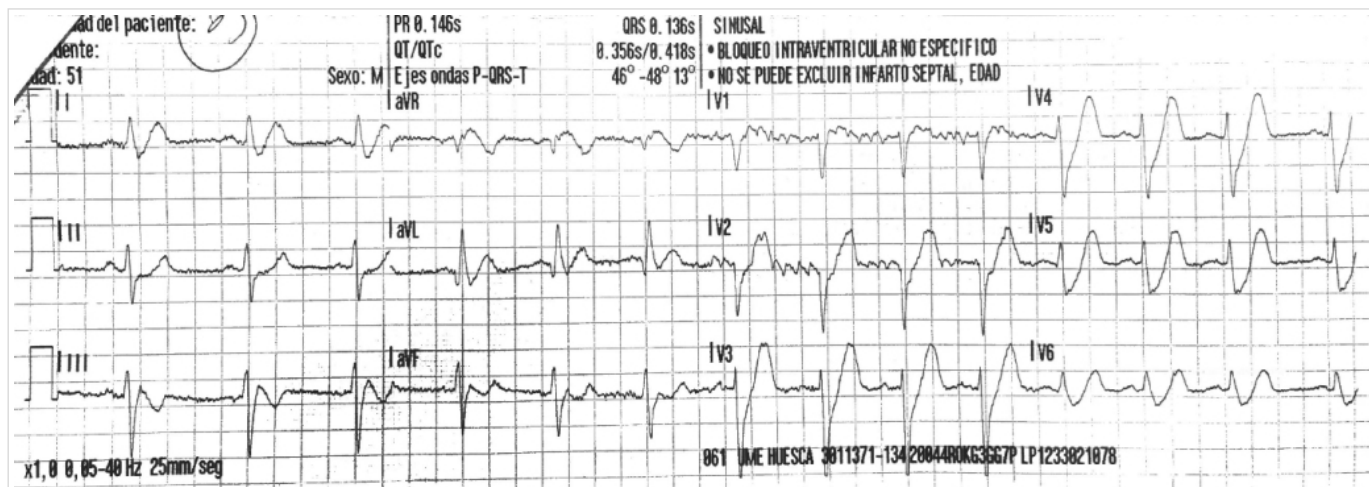


Figure 1.

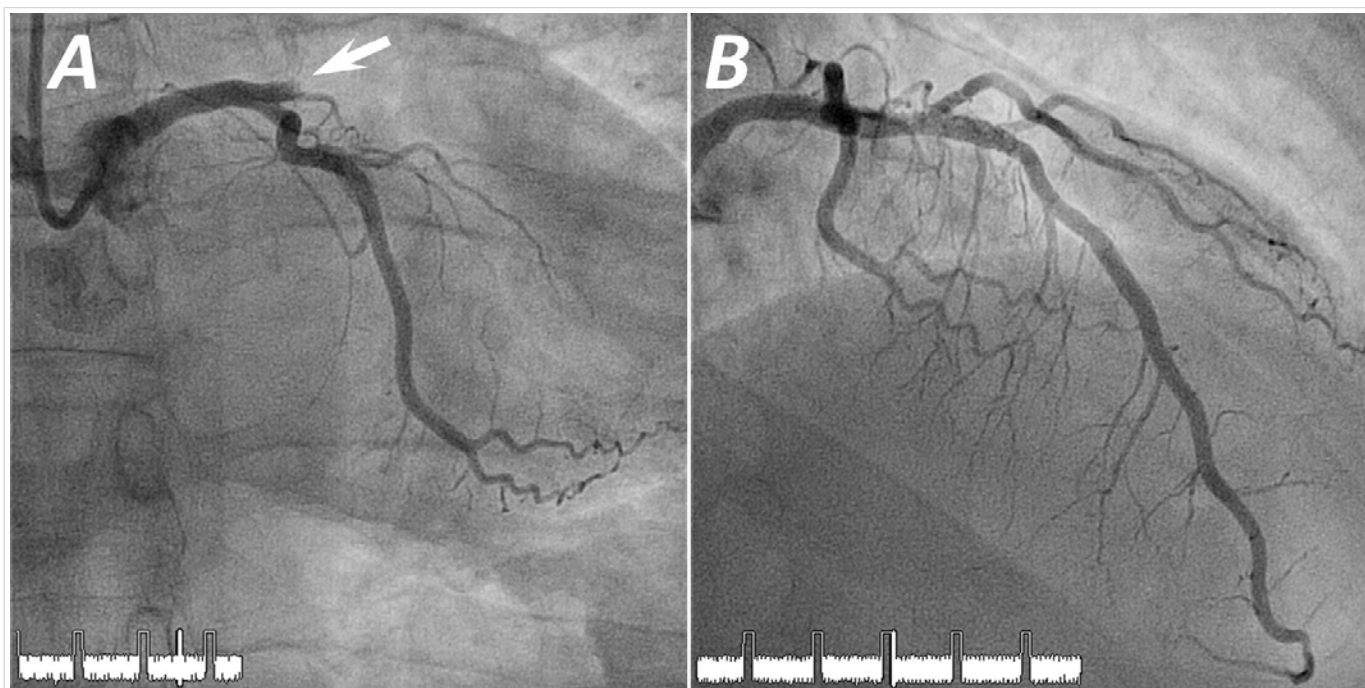


Figure 2.