

## Endocarditis due to corynebacterium after transcatheter aortic valve implantation: A case report

Alfredo Hernández-Caballero , MD; and Virginia Sotorrió-Simó , MD

Department of Internal Medicine, *Hospital General Santa Ana*. Motril, Granada, Spain.

*Este artículo también está disponible en español*

### ARTICLE INFORMATION

Received: May 27, 2019  
Accepted: June 24, 2019

### Competing interests

The authors declare no competing interests

### Figures

Images from complementary tests are shown with patient's consent.

### Abbreviations

**PET/CT:** Positron Emission Tomography/Computed Tomography  
**TAVI:** transcatheter aortic valve implantation  
**TEE:** transesophageal echocardiography

### ABSTRACT

We present a case of prosthetic valve endocarditis secondary to an infrequent organism (*Corynebacterium* sp.) after percutaneous aortic valve implantation. The lower sensitivity of transesophageal echocardiogram to detect signs of endocarditis in these patients may delay diagnosis. Implementing other ancillary imaging techniques such as positron emission tomography may be helpful. The increase in percutaneous prosthetic implants in recent years is associated with an upsurge in complications such as endocarditis.

**Keywords:** Endocarditis, *Corynebacterium*, Bioprosthesis, Transcatheter aortic valve replacement

### *Endocarditis secundaria a corynebacterium tras implante de válvula aórtica transcatóter: Informe de un caso*

### RESUMEN


*Se presenta un caso de endocarditis valvular protésica secundaria a un organismo infrecuente (*Corynebacterium* sp.) tras la implantación de una prótesis valvular aórtica percutánea. La menor sensibilidad del ecocardiograma transesofágico para detectar signos de endocarditis en éstos pacientes puede retrasar el diagnóstico. El uso de otras técnicas de imagen complementarias como la tomografía por emisión de positrones, puede ser de utilidad. El aumento de implantes de prótesis percutánea en los últimos años va asociado a un aumento de complicaciones como la endocarditis.*

**Palabras clave:** Endocarditis infecciosa, *Corynebacterium*, Bioprótesis, Reemplazo de la válvula aórtica transcatóter

### INTRODUCTION

Since its appearance in 2002, transcatheter aortic valve implantation (TAVI) has become an alternative for the treatment of severe symptomatic aortic stenosis in individuals at high risk of open-chest surgery<sup>1</sup>. The number of people treated with this technique has increased, but also the number of complications has been rising. The incidence of infective endocarditis in patients with transcatheter aortic valve prostheses is estimated at 0.5-2.1% in the different series<sup>2</sup>.

Prosthetic valve endocarditis due to *Corynebacterium* sp. has been described in the literature, but rarely associated with patients who have un-

 A Hernández-Caballero  
*Hospital General Santa Ana*  
Av. Enrique Martín Cuevas, s/n,  
18600 Motril. Granada, España.  
E-mail address:  
alfredohdezcaballero@gmail.com

dergone TAVI. The case of a male who developed infective endocarditis due to this bacillus one year after the aforementioned procedure is presented herein.

## CASE REPORT

### Medical history and physical examination

We report the case of an 81-year-old male who had a transfemoral TAVI one year ago due to severe symptomatic aortic stenosis. He was admitted with a two-week progressive fever of unknown origin, decreased alertness and abdominal pain.

Physical examination showed septic shock with blood pressure of 70/30 mmHg, temperature of 38° C, basal oxygen saturation of 94%, tachycardia of 110 beats per minute and oligoanuria, thus requiring vasoactive amines administration. The patient also presented generalized pallor, respiratory distress, obtundation, absence of jugular vein distention, aortic diastolic murmur, bilateral basal crackles, painful abdomen on deep palpation in right hypochondrium and slight malleolar edema in both lower limbs.

### Complementary tests

Tests revealed left-sided left-shift leukocytosis, normocytic anemia with hemoglobin of 10 g/dl and increased acute phase reactants.

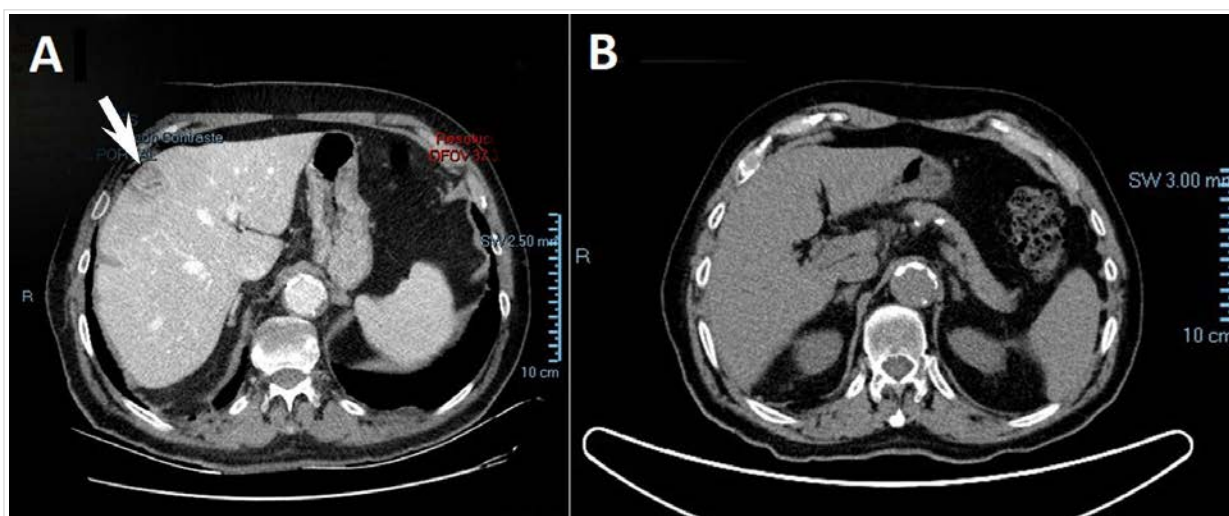
Among imaging studies, chest X-ray showed no evidence of condensation.

Transthoracic and transesophageal (TEE) echocardiograms were performed, detecting: well-positioned prosthesis, paravalvular dehiscence with moderate regurgitation and periannular thickening, with no vegetation imaging or conclusive study for endocarditis. A CT scan of the abdomen was also requested (**Figure 1A**), showing space-occupying liver lesions compatible with abscesses; *Corynebacterium sp.* species were isolated in two blood cultures taken in different sites. Hence, suspecting TAVI endocarditis complicated by septic embolism, antibiotic treatment was initiated with improvement of both, symptoms and lab tests. A positron emission tomography/computed tomography (PET/CT) with 18F-fluorodeoxyglucose (18F-FDG) was performed (**Figure 2**) evidencing paravalvular and hepatic hyperenhanced areas.

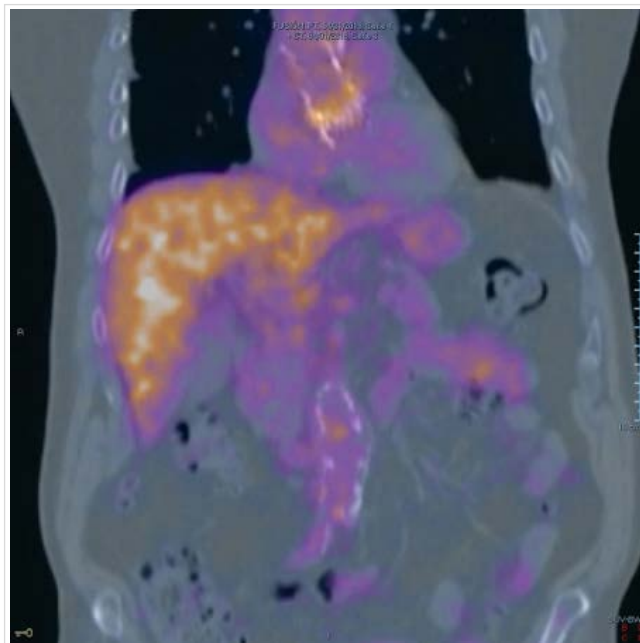
After four weeks of antibiotic treatment, a new follow-up abdominal CT scan was requested. Resolution of the space-occupying lesion visualized on the liver in the previous study was confirmed (**Figure 1B**).

## COMMENT

Prosthetic valve endocarditis is an uncommon, yet



**Figure 1.** Abdominal computed tomography (CT). **A.** First study showing a 3 cm subcapsular lesion, predominantly hypodense and well-defined with irregular captation sites inside and peripheral hypodense halo compatible with abscess (arrow) at the VIII hepatic segment. **B.** Follow-up computed tomography (CT) showing abscess resolution.



**Figure 2.** Positron emission tomography/computed tomography (PET/CT) with paravalvular and hepatic hyper-enhanced areas.

not rare complication with high mortality. In our case, although the initial echocardiogram was inconclusive for endocarditis, other imaging techniques such as PET/CT helped the diagnosis.

Although there are few cases of post-TAVI valve endocarditis due to *Corynebacterium sp.*, it is important to know about potential complications. Most transcatheter aortic valve implantations are performed in conventional cardiac catheterization rooms, where airflow and sterilization guidelines may not be as strict and followed as in operating rooms<sup>2</sup>. Moreover, patients receiving treatment are usually older, with higher comorbidity and lower immune response.

Aseptic techniques during the procedure and antibiotic prophylaxis adjusted to patients most at risk, may reduce the possibility of prosthetic valve endocarditis. A recent multicenter study demonstrated that orotracheal intubation and self-expandable CoreValve system implementation are risk factors for post-TAVI infective endocarditis ( $p=0.004$ ;  $p=0.007$ , respectively)<sup>3</sup>.

The pathophysiology of percutaneous prosthetic valve endocarditis differs from that of native valves by a lower incidence of vegetations and a higher incidence of paravalvular abscesses.

Given its higher sensitivity, TEE should be per-

formed in TAVI patients with clinical suspicion of endocarditis; however, this study's sensitivity in TAVIs continues to be lower than in native valves, probably due to the presence of intracardiac material which may hamper the identification of vegetations and abscesses<sup>4,5</sup>. Actually, in a study of 31 patients, Lengyel<sup>6</sup> showed that TEE could only find data on endocarditis in 50% of cases.

In a more recent screening of 180 TAVI patients, Puls *et al*<sup>7</sup> reported on the difficulty in making the correct diagnosis by TEE, due to devices and prosthetic reflection, with the consequent absence of robust echocardiographic criteria for the diagnosis of post-TAVI endocarditis.

Early suspicion and diagnosis are crucial to the later course of the disease.

### Puntos clave

- *Corynebacterium sp.* endocarditis is a rare disease, but early detection changes treatment and prognosis.
- The lower sensitivity of TEE for detecting signs of endocarditis in these patients may delay diagnosis.
- In our case, PET/CT –with greater sensitivity for endocarditis detection– allowed for the diagnosis.

### REFERENCES

1. Cribier A, Eltchaninoff H, Bash A, Borenstein N, Tron C, Bauer F, *et al.* Percutaneous transcatheter implantation of an aortic valve prosthesis for calcific aortic stenosis: first human case description. *Circulation*. 2002;106(24):3006-8.
2. Loh PH, Bundgaard H, S Ndergaard L. Infective endocarditis following transcatheter aortic valve replacement: diagnostic and management challenges. *Catheter Cardiovasc Interv*. 2013;81(4): 623-7.
3. Amat-Santos IJ, Messika-Zeitoun D, Eltchaninoff H, Kapadia S, Lerakis S, Cheema AN, *et al.* Infective endocarditis after transcatheter aortic valve implantation: results from a large multicenter registry. *Circulation*. 2015;131(18):1566-74.
4. Aranzulla TC, De Benedictis M, Asteggiano R. Follow-up management after transcatheter aortic valve implantation (TAVI). *E-J Cardiol Pract [Internet]*. 2016 [cited 26 May 2019];14(7). Available at: <https://www.escardio.org/Journals/E-Journal-of-Cardiology-Practice/Volume-14/Follow-up-management-after-transcatheter-aortic-valve>

implantation-TAVI

5. Pedersen WR, Walker M, Olson JD, Gobel F, Lange HW, Daniel JA, *et al.* Value of transesophageal echocardiography as an adjunct to transthoracic echocardiography in evaluation of native and prosthetic valve endocarditis. *Chest.* 1991; 100(2):351-6.
6. Lengyel M. The impact of transesophageal echocardiography on the management of prosthetic valve endocarditis: experience of 31 cases and review of the literature. *J Heart Valve Dis.* 1997; 6(2):204-11.
7. Puls M, Eiffert H, Hünlich M, Schöndube F, Hasenfuß G, Seipelt R, *et al.* Prosthetic valve endocarditis after transcatheter aortic valve implantation: the incidence in a single-centre cohort and reflections on clinical, echocardiographic and prognostic features. *EuroIntervention.* 2013;8(12): 1407-18.