





Cardiovascular manifestations of liver cirrhosis according to its severity evaluated through the Child-Pugh score

Aylen Pérez Barreda¹ , MD; Eliecer Hernández Alvarado², MD; Teresita Pérez González³, MD; Marcia Samada Suárez³, MD, PhD; Julio C. Hernández Perera³, MD, PhD; Miguel J. Puig Fernández³ , MD; Katia Ravelo Llanes³ , MD; and Oscar A. Alfonso Montero³ , MD

¹ Instituto de Cardiología y Cirugía Cardiovascular (ICCCV). Havana, Cuba.

² Hospital Abel Santamaría. Pinar del Río, Cuba.

³ Centro de Investigaciones Médico Quirúrgicas (CIMEQ). Havana, Cuba.

Este artículo también está disponible en español

ARTICLE INFORMATION

Received: May 5, 2019

Accepted: July 2, 2019

Competing interests

The authors declare no competing interests.

Abbreviations

HPS: Hepatopulmonary syndrome

LC: Liver cirrhosis

LT: Liver transplantation

LV: Left ventricle

PaO₂: partial pressure of oxygen in arterial blood

TAPSE: Tricuspid annular plane systolic excursion

ABSTRACT

Introduction: Cirrhotic cardiomyopathy is a cardiac dysfunction that is present in patients with liver cirrhosis, in the absence of other heart disease.

Objectives: To ascertain electrocardiographic and echocardiographic findings and arterial oxygenation state in patients with liver cirrhosis.

Methods: An observational, descriptive, cross-sectional study was conducted with 95 liver transplant recipients at the CIMEQ over the established period. The Child-Pugh severity classification was applied for this purpose.

Results: We screened 95 patients (53 women [55.7%]) who underwent electrocardiography, echocardiography, and determination of blood oxygen pressure and oxygen saturation by oximetry. The SPSS (20), with summary measures for qualitative (ratios and percentages) and quantitative (mean and standard deviation) variables was used. Our results reveal greater compromise of the variables studied in correlation with a greater severity of liver cirrhosis, as assessed by Child-Pugh, in relation to S' wave ($p=0.03$), A wave ($p=0.03$), pulmonary artery systolic pressure ($p=0.004$) and arterial oxygen partial pressure ($p=0.004$).

Conclusions: Taking into account the Child-Pugh score, study showed a progressive approach to pathological values of echocardiographic variables for the analysis of diastolic function and pulmonary pressures, as well as oxygen content of arterial blood (PaO₂), in the most advanced stages of liver cirrhosis.

Keywords: Liver cirrhosis, Cirrhotic cardiomyopathy, Cardiac function, Echocardiography

Manifestaciones cardiovasculares de la cirrosis hepática según su gravedad evaluada por la clasificación de Child-Pugh

RESUMEN

Introducción: La miocardiopatía cirrótica es una disfunción cardíaca que está presente en pacientes con cirrosis hepática, en ausencia de otra enfermedad cardíaca.

Objetivo: Describir los hallazgos electrocardiográficos, ecocardiográficos y el estado de la oxigenación arterial en pacientes con cirrosis hepática.

Método: Se realizó un estudio observacional, descriptivo, *transversal*, con 95 pacientes en protocolo de trasplante hepático en el CIMEQ, en el período establecido, para lo cual se tuvo en cuenta la clasificación de gravedad de Child-Pugh.

✉ A Pérez Barreda
Instituto de Cardiología y Cirugía
Cardiovascular. Calle 17 N° 702,
Vedado, CP 10400. La Habana, Cuba.
E-mail address:
aylen@infomed.sld.cu

Authors' Contribution

APB, EHA and TGP: Idea conception and design of the research, data collection and interpretation, and manuscript writing.

MSS: Design of the research and statistical analysis of raw data.

JCHP and MJPF: Data obtaining and interpretation, and helped to draft the manuscript.

KRL and OAAM: Research conception and obtaining of the raw data.

All authors critically reviewed the manuscript and approved the final report.

Resultados: Se investigaron 95 pacientes (53 mujeres [55,7%]), a los cuales se les realizó electrocardiograma, ecocardiograma, determinación de la presión arterial de oxígeno y su saturación por oximetría. Se usó el SPSS (20), con medidas de resumen para variables cualitativas (razones y porcentajes) y cuantitativas (media y desviación estándar). Los resultados muestran mayor compromiso de las variables estudiadas en relación con la mayor gravedad de la cirrosis hepática, evaluada por Child-Pugh, en relación con la onda S' ($p=0,03$), onda A ($p=0,03$), presión sistólica del tronco de la arteria pulmonar ($p=0,004$) y presión parcial de oxígeno arterial ($p=0,004$).

Conclusiones: Al tener en cuenta dicha clasificación, se evidenció acercamiento progresivo a valores anormales de las variables ecocardiográficas para el análisis de la función diastólica, presiones pulmonares y del estado de la oxigenación arterial expresado por la PaO_2 , en los estadios más avanzados de la cirrosis hepática.

Palabras clave: Cirrosis hepática, Miocardiopatía crónica, Función cardíaca, Ecocardiografía

INTRODUCTION

Cardiovascular diseases are the leading cause of death in most developed countries. These diseases have been the main cause of death in Cuba for more than four decades. Cardiovascular diseases are expected to remain the leading cause of death globally by 2030¹. Chronic liver disease shows a high incidence and prevalence worldwide; it is the ninth cause of death in our country and has gradually increased over the last years².

Liver cirrhosis (LC) is a progressive disease characterized by organ fibrosis due to chronic liver damage resulting in impaired liver function and structural changes leading to portal hypertension³.

The association between liver cirrhosis and the cardiovascular system was described more than 50 years ago by Kowalski and Abelmann⁴ in a group of cirrhotic alcoholics. Although this condition was initially thought to be secondary to alcoholic cardiomyopathy, later studies showed that cardiocirculatory changes also occurred in LC patients regardless of the cause⁵.

Since then, many publications have described a number of cardiac disorders resulting from the disease; although they have been more accurately described in recent years⁶.

Cirrhotic cardiomyopathy is a heart condition, newly recognized as a clinical disease that occurs in LC patients, in the absence of any other heart disease. It is characterized by diastolic function/left ventricular (LV) contractility disorders, structural changes in the heart chambers, electrophysiological disorders (QT prolongation) and serum cardiac stress markers shifting^{7,9}.

There is quite little information on the epidemiol-

ogy of cirrhotic cardiomyopathy as the cardiac function remains normal at rest making it difficult to diagnose. Most patients are diagnosed during the hepatic decompensation phase where the heart -diastolic and output- failure characteristics become more apparent^{5,10}.

There is a group of multifactorial pathogenic mechanisms for such cardiovascular changes. Neurohumoral and vascular regulation disorders stand out among them⁵. Decreased peripheral vascular resistance is the result of complex mechanisms related to arteriovenous communications, increased levels of circulating vasodilators -owing to their diminished degradation in the diseased liver- and their passing through portosystemic shunts, developed from the angiogenesis stimulation by vascular endothelial growth factor (VEGF). Some studies highlight the major role played by potent vasodilators in LC patients, such as: nitric oxide, endogenous cannabinoids, brain natriuretic peptide, calcitonin related-gene peptide and endothelin-3¹¹.

On the other hand, the plasma volume increases, but with an uneven disposition that determines a relative central hypovolemia due to its redistribution towards the splanchnic flow. This consequently causes -baroreceptor and vasoconstrictor systems- activation, such as the sympathetic nervous system and renin-angiotensin-aldosterone system, which favor greater fluid retention^{11,12}.

The clinical course of LC patients could be compromised by two low-prevalence but high-morbidity and-mortality disorders. These may cause right ventricular dysfunction and are accurately diagnosed by echocardiography: hepatopulmonary syndrome (HPS) and portopulmonary hypertension, both of which have recently gained special interest as ortho-

topic liver transplantation (LT) has proven successful¹³.

Many clinical tools for carrying out prognostic assessments in LC patients have been developed over the last fifty years; among them the Child-Pugh scale stands out as one of the best known and most widely used¹⁴. More than one-third of Child-Pugh's Class C patients (score ≥ 10), who are on the candidates wait-list, may die after one year; in contrast, Class B patients (score 7-9) have a 5-year survival probability of more than 80%, while Class A patients (score 5-6) have a 5-year survival of more than 90% without undergoing transplantation¹⁵.

Regarding the characteristics of cirrhotic cardiomyopathy, QT prolongation and diastolic dysfunction are found in most of Child-Pugh's class B or C LC patients (moderate to severe liver failure). The obvious relationship between the severity of liver disease and this scale has been described in multiple investigations^{5,11,13}.

Echocardiography at rest is considered the most appropriate imaging study for the diagnosis of cirrhotic cardiomyopathy^{16,17}. It is undoubtedly an excellent test, (95% safety) and especially useful for ruling out a possible portopulmonary hypertension with a negative predictive value of 100%^{12,17}; moreover, it allows any other possible cause of pulmonary hypertension to be excluded during the test, as well as evaluating cardiac function and estimating pulmonary artery systolic pressure^{5,18}.

Corrected QT interval prolongation (>440 msec) has been reported as a frequent finding in 30-60% of LC patients; QT dispersion and chronotropic incompetence have also been described as recurrent findings^{5,12,19}. Screening all patients with HPS, applying a diagnostic threshold of $\text{PaO}_2 < 70$ mmHg at rest with room-air pulse oximetry and performing echocardiography during LT evaluation, represents a reasonable goal for identifying transplantation-eligible patients²⁰.

A more complete understanding of the effect of liver disease on the cardiovascular system coupled with a diagnosis of the patient's comorbidities allows for proper stratification, prognosis, and decision-making in the case of LC patients; even more so in those with a fitting indication for liver transplantation, which would certainly enhance treatment, as well as decrease the incidence of serious cardiovascular complications during the postoperative period.

This research is intended to contribute to early therapeutic decision-making that will significantly modify both the course of liver and cardiovascular

disease and post-LT morbidity and mortality; considering that the *Centro de Investigaciones Médico-Quirúrgicas* (CIMEQ) is a national reference institution in the field of liver transplantation. A large number of patients are evaluated in Cardiology appointments while they prepare for the expected organ transplantation as the only life-saving option. A more thorough diagnosis of these impairments will undoubtedly imply better procedures to be followed not only while preparing for surgery but also during the post-operative period, generally achieving better results.

All of the above justifies the purpose of carrying out this study with the aim of identifying the cardiovascular manifestations in LC patients according to the etiology of the disease and thus, helping to make the most appropriate research and therapeutic decisions.

METHOD

A descriptive, cross-sectional, observational study in LT protocol LC patients who were being assisted at the CIMEQ was conducted in the period December 2013 to November 2015. The study population consisted of all LT protocol LC patients who regularly attended Gastroenterology and Cardiology appointments at CIMEQ.

Exclusion criteria

We excluded patients with:

- Ischemic heart disease.
- Previous diagnoses of other cardiomyopathies.
- Decompensated chronic diseases (diabetes mellitus, renal/heart failure, thyroid function disorders, chronic pulmonary disease).
- Patients with pulmonary hypertension prior to the diagnosis of liver disease.
- Neoplastic disease.

After taking into account the inclusion and exclusion criteria, the sample was made up of 95 patients, who were able to undergo the different studies indicated. Child-Pugh's classification was applied according to the recommendations of Wang *et al*²¹.

Echocardiogram protocol

The transthoracic study was performed using the iE33 (Phillips) sonograph. In the M-mode analysis, two-dimensional and Doppler standard echocardiographic views (long and short parasternal axes, 2-4

chamber apical views) were taken to assess the anatomy of the cardiac chambers and the global and segmental functions of both ventricles. By means of M-Mode imaging from the parasternal views, the LV end-diastolic and end-systolic diameters, septum and posterior wall thickness were measured. Left ventricular ejection fraction was calculated as a systolic function index by using the Simpson's method, described in the literature²². Diastolic function was studied by pulsed-Doppler with determination of the transmitral flow velocity profile; the sample volume was positioned at the distal end of the mitral cavity leaflets from the 4-chamber apical view. The different LV diastolic function variables previously treated were determined and each patient's relaxation

pattern was characterized. Doppler tissue imaging of the lateral mitral ring was used to support the diastolic LV function assessment^{23,24}. The pulmonary artery pressure was calculated by determining the transtricuspid gradient and right atrial pressure; the continuous Doppler, at the level of the tricuspid valve in two-dimensional apical 4-chamber/short parasternal axis view in large vessels was used to obtain this gradient. Right atrial pressure was measured by evaluating inspiratory movement of the inferior vena cava in two-dimensional or M-mode^{22, 24}. Mean pulmonary pressure was calculated by determining the pulmonary acceleration time by means of pulsed-Doppler, positioned on the pulmonary valve in the short parasternal axis at the level of the great

Table. Echocardiographic and electrocardiographic variables and arterial oxygenation state in patients with liver cirrhosis according to the Child-Pugh classification. December 2013 - November 2015.

| Variables | Child-Pugh classification | | | | | | p |
|-----------------------------------|---------------------------|------|----------|------|---------|------|---------------|
| | A (n=58) | | B (n=28) | | C (n=9) | | |
| | Mean | SD | Mean | SD | Mean | SD | |
| Systolic function | | | | | | | |
| IVSd | 10.7 | 0.9 | 11 | 0.7 | 10.3 | 1.4 | 0.16 |
| LVPWd | 10.3 | 1.4 | 10.3 | 1.1 | 10.3 | 2.2 | 0.99 |
| LVEDD | 47.9 | 4.1 | 47.3 | 4.5 | 45.6 | 9.1 | 0.4 |
| LVESD | 26.6 | 4.2 | 26.8 | 4.8 | 28.3 | 6.9 | 0.79 |
| S' wave | 7.8 | 0.8 | 7.6 | 0.8 | 7.1 | 0.3 | 0.03* |
| LVEF | 68.1 | 4.6 | 68.3 | 5.1 | 69 | 4.9 | 0.87 |
| TAPSE | 2.4 | 2.4 | 2.1 | 0.1 | 1.9 | 1.9 | 0.59 |
| Diastolic function | | | | | | | |
| E wave | 76.6 | 11.9 | 76.4 | 16.4 | 79.6 | 16.9 | 0.81 |
| A wave | 62.4 | 14.0 | 70.7 | 16.1 | 71.4 | 20.4 | 0.03* |
| E/A | 1.2 | 0.3 | 1.09 | 0.3 | 1.04 | 0.2 | 0.1 |
| e' wave | 10.0 | 1.9 | 9.9 | 2.3 | 8.5 | 0.8 | 0.13 |
| E/e' | 8.7 | 2.2 | 9.3 | 2.5 | 10.1 | 1.7 | 0.21 |
| Pulmonary pressures | | | | | | | |
| PASP | 22.9 | 4.76 | 26.5 | 6.8 | 28 | 6.14 | 0.004* |
| MPAP | 17.3 | 4.7 | 17.6 | 5.3 | 16.7 | 5.3 | 0.9 |
| Electrical | | | | | | | |
| QTc | 417.7 | 25.3 | 425.4 | 22.6 | 428.4 | 37.7 | 0.29 |
| Arterial oxygenation state | | | | | | | |
| Blood gases (PaO ₂) | 87.4 | 7.3 | 83.8 | 7.7 | 78.4 | 12.4 | 0.004* |
| Oximetry | 98.7 | 1.8 | 98.3 | 1.7 | 97.5 | 3.7 | 0.27 |

* p<0.05 (One-factor Anova test).

IVSd, interventricular septal end-diastolic diameter; LVEDD, left ventricular end-diastolic diameter; LVEF, left ventricular ejection fraction; LVESD, left ventricular end-systolic diameter; LVPWd, left ventricular posterior wall end-diastolic diameter; MPAP, mean pulmonary artery pressure; PaO₂, partial pressure of oxygen in arterial blood; PASP, pulmonary artery systolic pressure; SD, standard deviation; TAPSE, tricuspid annular plane systolic excursion.

vessels, as recommended by Feigenbaum *et al*²².

Statistical analysis

All required information was obtained from the medical records of the admitted patients. The data were recorded on a collection sheet previously drafted for this purpose.

The SPSS program (Statistical Package for the Social Sciences Version 20.0) was used as the statistical instrument. Qualitative variables were expressed with summary measures for this type of variables (frequency and percentage), and the mean \pm standard deviation was used for quantitative variables, according to their distribution.

The *Student's t-test* and one-factor Anova test were used to compare means between two or more groups of variables, respectively. Ninety-five percent was taken as the confidence interval, with a $p < 0.05$ for acceptance and interpretation of the results, represented in tables and graphs, which were analyzed and compared according to the national and foreign literature reviewed. This allowed us to draw conclusions and issue recommendations.

Bioethical considerations

All of the ethical standards for research on human subjects set forth in the World Medical Association Declaration of Helsinki, were respected throughout this study. All eligible participants, being fully aware that they would undergo non-invasive diagnostic

procedures, freely gave their written informed consent. The research project was approved by the CIMEQ Ethics Committee.

RESULTS

The study shows the results of the echocardiographic and electrocardiographic variables and arterial oxygenation state, according to the Child-Pugh classification. Of the echocardiographic variables, the S' waves show significant differences between the severity stages of liver cirrhosis ($p=0.03$) and A ($p=0.03$), and the pulmonary artery systolic pressure ($p=0.004$) (**Table** and **Figures 1-4**).

The variables related to the LV size, thickness and overall function did not show significant differences; however, the mean related to the regional contractility of the LV, expressed in the S' wave, shows a significant tendency to approach abnormal values as the severity of the disease increases, according to the Child-Pugh stage (**Table** and **Figure 1**). This same behavior is observed in the tricuspid annular plane systolic excursion (TAPSE) which reflects the state of the right ventricular systolic function, although with no significant differences ($p > 0.05$).

There were no significant differences regarding the variables related to diastolic function and except for the A wave, with a higher mean in stage C of the disease, the rest of the variables showed no relevant

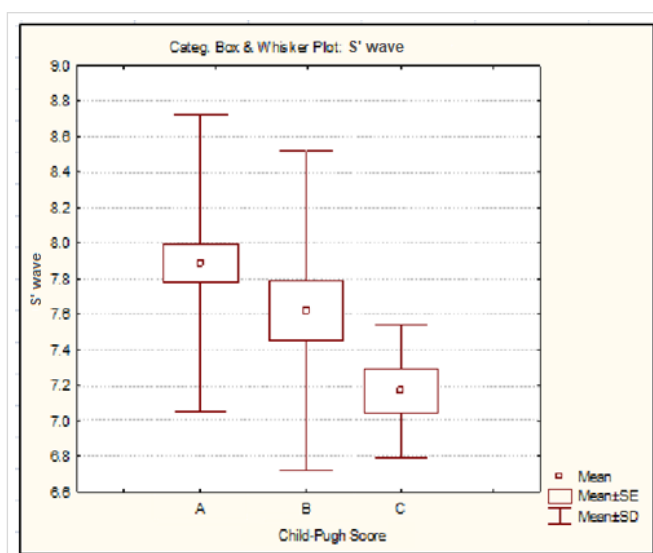


Figure 1. S' waves distribution according to the Child-Pugh classification. SD, standard deviation; SE, standard error.

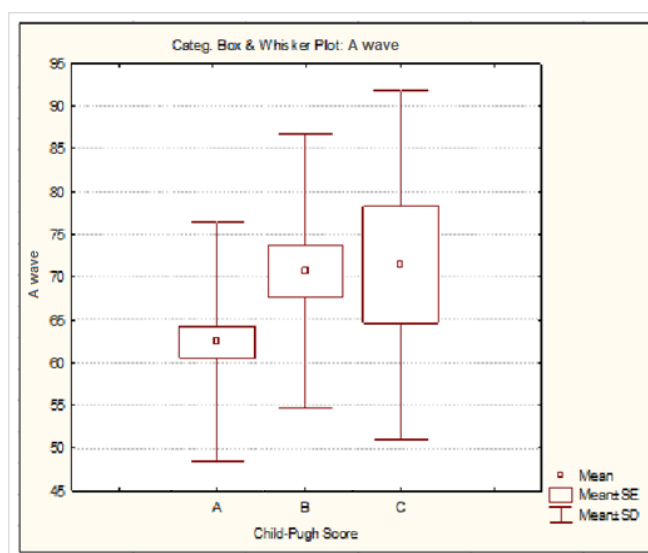


Figure 2. A waves distribution according to the Child-Pugh classification. SD, standard deviation; SE, standard error.

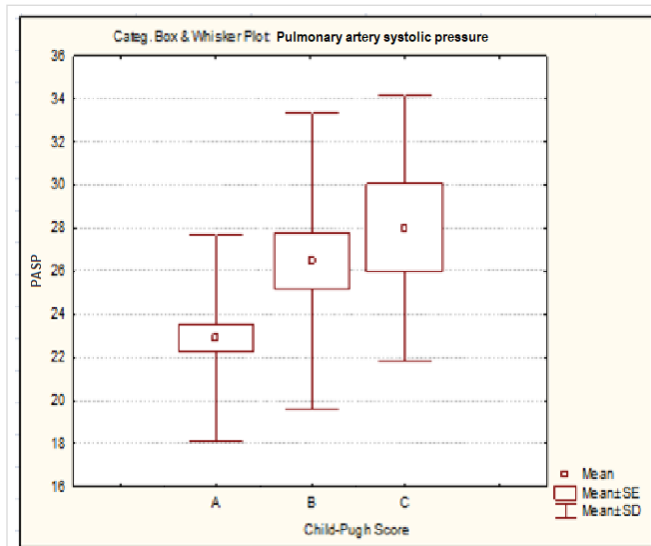


Figure 3. Pulmonary artery systolic pressure distribution according to the Child-Pugh classification. SD, standard deviation; SE, standard error.

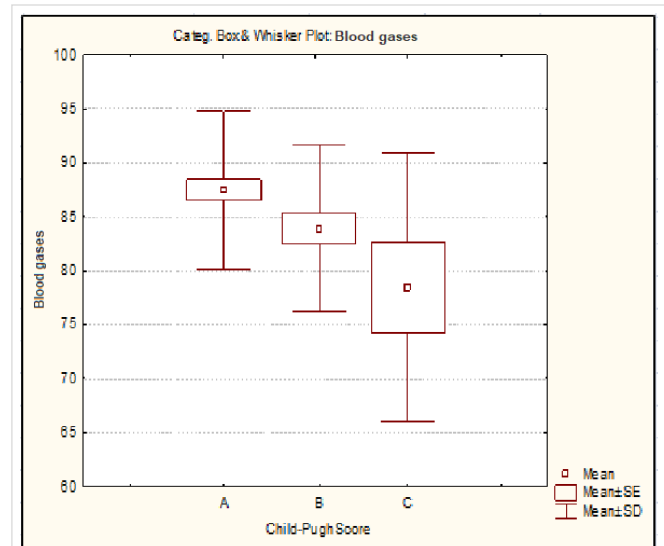


Figure 4. Oxygen blood pressure distribution according to the Child-Pugh classification. SD, standard deviation; SE, standard error.

differences, although in the E/e' and E/A ratio they showed a linear trend of their averages approaching rather abnormal values the more severe the disease, even though these remained within the normal range (**Table** and **Figure 2**).

In relation to pulmonary pressures, the mean pressure did not present relevant divergences among classification groups. Pulmonary systolic pressure behaved differently as a significantly larger mean was observed in Child-Pugh stages B and C, which are the most severe (**Table** and **Figure 3**).

The corrected QT became larger as the severity of liver cirrhosis increased, although without significant differences (**Table**).

Arterial oxygenation state is shown through blood oxygen pressure (PaO₂) in gasometry and pulse oximetry. PaO₂ showed evident differences where the mean reached abnormal values in stages B and C of the Child-Pugh classification, respectively (**Table** and **Figure 4**).

DISCUSSION

A good number of LC patients undergoing LT will have an inadequate ventricular response to the hemodynamic stress generated by graft reperfusion. This response correlates with postoperative cardiovascular complications and is closely linked to the presence of previous cardiovascular disorders that

have an underlying pathophysiological basis in LC^{11,25}.

Regardless of the type of heart condition, an extreme and abrupt hemodynamic overload occurs during LT, due to acute changes in preload, post-load, contractility, clamping and pulling-off of the great vessels, graft reperfusion and blood losses, which may be significant despite surgical strategies to, if possible, soften such cardiovascular impact^{11,25}.

Assessing the functional capacity of the heart to overcome the surgical hemodynamic stress is important not only because of the intra-operative complications resulting from impaired cardiac function, but also because of the effect that these may have on post-LT morbidity and mortality. In fact, heart disease is the third cause of post-LT morbidity, after infections and graft rejection^{6,25,26}.

The CIMEQ is a national reference center for liver transplantation. The present study describes the cardiovascular manifestations of LT protocol LC patients at this institution. Thus, it is intended to contribute to early therapeutic decisions that significantly modify the evolution of liver disease and post-transplantation morbidity and mortality related to the cardiovascular system.

With respect to the echocardiographic and electrocardiographic variables studied and their relationship to the severity of liver disease according to the Child-Pugh classification, the mean in all of them remained consistent with the normal ranges for that

classification except for the S' wave ($p=0.03$), A wave ($p=0.03$) and pulmonary artery systolic pressure ($p=0.004$). The trend was towards an approximation to the pathological ranges as the severity of liver disease increased. An increase in ventricular wall thickness was reported; however, no clear relationship to the stage of liver disease has been described^{5,10,27}. A retrospective analysis that included 802 deaths from LC, which were autopsied, revealed a significant sample with pathological ventricular wall thickening (53.2%), where LV predominated (31.0%) and, to a lesser extent, the right ventricle (9.3%) or both (12.9%), and heart failure was the cause of death in 25.8% of the patients²⁸.

The assessment of cardiac volumes in LC patients has yielded different results, depending on the methods. Some echocardiographic studies showed a normal LV size^{29,30}; however, other published papers have shown increased LV end-diastolic/end-systolic volumes³¹. It has also been reported that alcohol-related LC cases showed significantly higher left ventricular end-diastolic volume. Those with viral, cryptogenic and autoimmune causes followed that order. This coincides with the fact that the diastolic function variables behaved precisely in the same order; reflecting changes in ventricular wall tension⁵.

Likewise, with regard to the association between LV ejection fraction and the severity of liver disease, according to the classifications described, some studies have reported normal values^{19,23}, others, an increase^{33,34}, a decrease in their values unrelated to the severity of the disease^{35,36} and worsening as the condition becomes more severe^{5,27,29}.

Several studies have shown the existence of latent heart dysfunction in LC patients. These symptoms are masked by hyperdynamic circulation and low peripheral vascular resistance, typical of the underlying disease, which justifies normal ventricular function or its gradual increase until they are diagnosed during the clinical hepatic decompensation in most patients³³. An investigation carried out in Cuba showed no alteration of the systolic function at rest³², a result that coincides with this research. Although there is little research on the lateral mitral annulus S' wave and TAPSE, no significant differences between them and the etiological classification, nor the severity of LC, nor the presence of portopulmonary hypertension or HPS are reported³⁷.

The variables defining diastolic dysfunction were shown to be within the normal range; it presented significantly higher results with respect to the A wave as the severity of the LC increased, according

to the Child-Pugh classification. The same behavior was observed in the e' wave and E/e ratio, but within the normal range, with no significant differences.

It is known that echocardiographically, the typical pattern of diastolic dysfunction is a reduced E wave peak with increased atrial contraction (A wave), resulting in a reduction in the E/A ratio, which has also been confirmed in LC patients; thus indicating the presence of diastolic dysfunction in the disease, which is more noticeable if ascites is present⁵.

The information on echocardiographic findings available in literature does not show uniform results, perhaps due to biases in patient selection and differences when choosing echocardiographic measures, which depend to a greater or lesser extent on volume load, a major factor in LC patients. In this sense, Dowsley *et al*³⁵ propose the use of tissue Doppler and the E/e' ratio as a good predictor of the risk of developing post-LT heart failure.

In all cases reviewed in the international literature, there is an increase in diastolic dysfunction, measured by its echocardiographic variables, in LC patients. However, several studies have reported that these disorders are not exclusive to advanced stages of the disease³⁶⁻³⁸. Other series^{5,10,33,38} do establish a clear relationship with the scores and scales already mentioned.

In another study conducted in Cuba³⁹, patients with diastolic dysfunction presented significantly lower values in the E wave and higher values in the A wave, with an E/A-ratio < 0.8 in a significant group of cases (40%). The rest of the variables did not show relevant changes, similar to what was found in our research.

Knowledge of the presence of diastolic dysfunction in the LC patient is extremely important, since it behaves as a subclinical heart disease whose diagnosis has been directly related to an increase in post-transplantation mortality from cardiovascular causes^{5,27,40}. It is suggested to be related to impaired relaxation, due to abnormalities in the exchange of calcium through the sarcoplasmic reticulum. An American study showed its association with increased risk of graft rejection or acute graft failure³⁵; however, other research found no effect on patient survival⁴¹.

In our series, mean pulmonary pressures remained within the normal ranges, although it should be noted that for the Child-Pugh classification, systolic pulmonary artery pressure showed significantly higher results in more advanced stages. These re-

sults are not consistent with the literature reviewed^{6, 28,42,43}; in fact, research by Krowka *et al*⁴⁴ suggests that the severity of chronic liver disease, as determined by the Child-Pugh scale, is not associated with the presence or severity of pulmonary hypertension. However, several studies, among which the REVEAL register stands out, show an independent predictive value of increased risk of mortality in those cirrhotic patients with portopulmonary hypertension and Child-Pugh B and C classification^{25,45,46}; in which deleterious effects are produced at the survival level, since the average survival at 5 years is 10-50%⁴⁴. In another series, those who had a specific treatment during 12 months presented a survival of 74% and, at 5 years, only 40%⁴⁷. No other national literature was found on the subject.

QT interval prolongation is the most frequent electrocardiographic disorder in this type of patient. In the cases studied, a mean within normal parameters was found, below 440 ms, although with a linear trend towards increased values in more advanced stages of the Child-Pugh classification (B and C), which coincides with the international studies reviewed^{5,10,33,48,49}, where this relationship has been shown to be directly proportional to the severity of LC^{33,48-50}. The relationship between these variables has not been found in Cuban studies. The aforementioned QT prolongation has also been related to an increased risk of sudden death in LC patients, regardless of its cause, due to ventricular tachycardia, particularly torsades de pointes, although it has been stressed that cases are usually infrequent^{48,51}. However, these electrophysiological changes disappear in almost half of the patients after LT^{48,49}. It should be noted that prolonged QT does not contraindicate surgery^{48,51}; however, according to Zambruni *et al*⁴⁸, several authors suggest that early identification may be a sign of easy diagnosis and very useful in identifying patients at risk of presenting cirrhotic cardiomyopathy.

As for the variables that evaluate arterial oxygenation and its connection with the Child-Pugh classification, significantly higher differences were observed in the mean PaO₂, although within normal parameters in all cases. As regards the relationship with the degree of liver dysfunction, expressed by the stages of the same classification, the studies are contradictory since an important group shows no correlation with the severity of the LC and the presence of HPS⁵²⁻⁵⁶, while other studies do associate it with greater liver dysfunction⁵⁷⁻⁵⁹. Specifically, the study with the largest sample found an independent

relationship of HPS in the univariate analysis with a higher Child-Pugh score and with the presence of ascites⁵⁸.

The most severe forms of HPS have an absolute indication for LT, which is their most definitive invasive therapy^{60,61}. Approximately 82% of patients undergoing LT have resolution of hypoxemia 15 months after surgical procedure⁶².

The most severe forms of HPS have an absolute indication for LT, which is their most definitive invasive therapy^{60,61}. Approximately 82% of patients receiving LT have resolution of hypoxemia within 15 months of surgery⁶².

CONCLUSIONS

All study participants with liver cirrhosis showed a progressive approach to pathological values of the echocardiographic variables for analyzing diastolic function and pulmonary pressures, as well as PaO₂ blood oxygenation level percent, in the most advanced stages of liver cirrhosis according to the Child-Pugh classification.

REFERENCES

1. World Health Organization. World Health Statistics 2011. Geneva: WHO Press [Internet]; 2011 [cited 27 Abr 2019]. Available at: https://www.who.int/gho/publications/world_health_statistics/2011/en/
2. Ministerio de Salud Pública. Anuario Estadístico de Salud 2018. La Habana: Dirección de Registros Médicos y Estadísticas de Salud; 2019.
3. Poordad FF. Presentation and complications associated with cirrhosis of the liver. *Curr Med Res Opin.* 2015;31(5):925-37.
4. Kowalski HJ, Abelmann WH. The cardiac output at rest in Laennec's cirrhosis. *J Clin Invest.* 1953; 32(10):1025-33.
5. Møller S, Lee SS. Cirrhotic cardiomyopathy. *J Hepatol.* 2018;69(4):958-60.
6. Krowka MJ. Portopulmonary hypertension. *Semin Respir Crit Care Med.* 2012;33(1):17-25.
7. Voiosu AM, Daha IC, Voiosu TA, Mateescu BR, Dan GA, Băicuș CR, *et al.* Prevalence and impact on survival of hepatopulmonary syndrome and cirrhotic cardiomyopathy in a cohort of cirrhotic patients. *Liver Int.* 2015;35(12):2547-55.
8. Karagiannakis DS, Papatheodoridis G, Vlachogi

- annakos J. Recent advances in cirrhotic cardiomyopathy. *Dig Dis Sci*. 2015;60(5):1141-51.
9. Gassanov N, Caglayan E, Semmo N, Massenkeil G, Er F. Cirrhotic cardiomyopathy: a cardiologist's perspective. *World J Gastroenterol*. 2014;20(42):15492-8.
 10. Van Wagner LB, Serper M, Kang R, Levitsky J, Hohmann S, Abecassis M, Skaro A, Lloyd-Jones DM. Factors associated with major adverse cardiovascular events after liver transplantation among a national sample. *Am J Transplant*. 2016;16(9):2684-94.
 11. Pudil R, Pelouch R, Praus R, Vašatová M, Hůlekc P. Heart failure in patients with liver cirrhosis. *Cor et Vasa [Internet]*. 2013 [cited 28 Abr 2019];55(4): e391-e396. Available at: <https://doi.org/10.1016/j.crvasa.2013.06.002>
 12. Polavarapu N, Tripathi D. Liver in cardiopulmonary disease. *Best Pract Res Clin Gastroenterol*. 2013;27(4):497-512.
 13. Kamath PS. Portopulmonary hypertension and hepatopulmonary syndrome. *J Gastroenterol Hepatol*. 2002;17(Supl 3):S253-5.
 14. Porres-Aguilar M, Gallegos-Orozco JF, Garcia H, Aguirre J, Macias-Rodriguez RU, Torre-Delgadillo A. Complicaciones vasculares pulmonares en hipertensión pulmonar y enfermedades hepáticas: una revisión concisa. *Rev Gastroenterol Mex*. 2013;78(1):35-44.
 15. Karagiannakis DS, Vlachogiannakos J, Anastasiadis G, Vafiadis-Zouboulis I, Ladas SD. Diastolic cardiac dysfunction is a predictor of dismal prognosis in patients with liver cirrhosis. *Hepatol Int*. 2014;8(4):588-94.
 16. Marchetta S, Delwaide J, Lancellotti R. La cardiomyopathie du cirrhotique: un bref aperçu [Cirrhotic cardiomyopathy: a brief overview]. *Rev Med Liege*. 2015;70(2):86-91.
 17. Raevens S, Colle I, Reyntjens K, Geerts A, Berrevoet F, Rogiers X, *et al*. Echocardiography for the detection of portopulmonary hypertension in liver transplant candidates: an analysis of cutoff values. *Liver Transpl*. 2013;19(6):602-10.
 18. Porres-Aguilar M, Gallegos-Orozco JF, Garcia H, Aguirre J, Macias-Rodriguez RU, Torre-Delgadillo A. Complicaciones vasculares pulmonares en hipertensión pulmonar y enfermedades hepáticas: una revisión concisa. *Rev Gastroenterol Mex*. 2013;78(1):35-44.
 19. Zambruni A, Trevisani F, Caraceni P, Bernardi M. Cardiac electrophysiological abnormalities in patients with cirrhosis. *J Hepatol*. 2006;44(5):994-1002.
 20. Adinolfi LE, Restivo L, Zampino R, Guerrera B, Lonardo A, Ruggiero L, *et al*. Chronic HCV infection is a risk of atherosclerosis. Role of HCV and HCV-related steatosis. *Atherosclerosis*. 2012;221(2):496-502.
 21. Wang J, Wang Q, Yu G, She Q, Zhang W, Zhang J. Correlation Between Liver Stiffness Measured by Shear Wave Elastography and Child-Pugh Classification. *J Ultrasound Med*. 2018;37(9):2191-9.
 22. Armstrong WF, Ryan T. Feigenbaum's Echocardiography. 8^a ed. Philadelphia: Wolters Kluwer; 2018. p. 363-462.
 23. García-Fernández MA, Zamorano J, Azevedo J. Doppler tissue imaging echocardiography. Madrid: McGraw-Hill Interamericana; 1998. pp. 23-45.
 24. Sonny A, Govindarajan SR, Jaber WA, Cywinski JB. Systolic heart failure after liver transplantation: Incidence, predictors, and outcome. *Clin Transplant [Internet]*. 2018 [cited 28 Abr 2019];32(3):e13199. Available at: <https://doi.org/10.1111/ctr.13199>
 25. Rahman S, Mallett SV. Cirrhotic cardiomyopathy: Implications for the perioperative management of liver transplant patients. *World J Hepatol*. 2015;7(3):507-20.
 26. Licata A, Mazzola A, Ingrassia D, Calvaruso V, Cammà C, Craxì A. Clinical implications of the hyperdynamic syndrome in cirrhosis. *Eur J Intern Med*. 2014;25(9):795-802.
 27. Josefsson A, Fu M, Björnsson E, Kalaitzakis E. Prevalence of pre-transplant electrocardiographic abnormalities and post-transplant cardiac events in patients with liver cirrhosis. *BMC Gastroenterol [Internet]*. 2014 [cited 29 Abr 2019];14:65. Available at: <https://doi.org/10.1186/1471-230X-14-65>
 28. Wroński J, Fiedor P, Kwolczak M, Górnicka B. Retrospective analysis of liver cirrhosis influence on heart walls thickness. *Pathol Res Pract*. 2015;211(2):145-9.
 29. Pozzi M, Carugo S, Boari G, Pecci V, de Ceglia S, Maggiolini S, *et al*. Evidence of functional and structural cardiac abnormalities in cirrhotic patients with and without ascites. *Hepatology*. 1997;26(5):1131-7.
 30. Fukazawa K, Gologorsky E, Manmohansingh V, Nishida S, Vigoda MM, Pretto EA Jr. Is the immediate reversal of diastolic dysfunction of cirrhotic cardiomyopathy after liver transplantation a sign of the metabolic etiology? *Liver Transpl*. 2009;15(11):1417-9.
 31. Somani PO, Contractor Q, Chaurasia AS, Rathi

- PM. Diastolic dysfunction characterizes cirrhotic cardiomyopathy. *Indian Heart J.* 2014;66(6):649-55.
32. Castellanos MI, Rogel BI, Rodríguez F, Arjona IA, Lazo del Vallin S. Disfunción cardiaca en la cirrosis hepática. *Rev Cuban Med [Internet]*. 2014 [cited 30 Abr 2019];53(2):189-200. Available at: <http://scielo.sld.cu/pdf/med/v53n2/med08214.pdf>
 33. Torregrosa M, Aguadé S, Dos L, Segura R, González A, Evangelista A, et al. Cardiac alterations in cirrhosis: reversibility after liver transplantation. *J Hepatol.* 2005;42(1):68-74.
 34. Lenci I, Alvior A, Manzia TM, Toti L, Neuberger J, Steeds R. Saline contrast echocardiography in patients with hepatopulmonary syndrome awaiting liver transplantation. *J Am Soc Echocardiogr.* 2009;22(1):89-94.
 35. Dowsley TF, Bayne DB, Langnas AN, Dumitru I, Windle JR, Porter TR, et al. Diastolic dysfunction in patients with end-stage liver disease is associated with development of heart failure early after liver transplantation. *Transplantation.* 2012;94(6):646-51.
 36. Enache I, Oswald-Mammosser M, Woehl-Jaegle ML, Habersetzer F, Di Marco P, Charloux A, et al. Cirrhotic cardiomyopathy and hepatopulmonary syndrome: prevalence and prognosis in a series of patients. *Respir Med.* 2013;107(7):1030-6.
 37. Merli M, Calicchia A, Ruffa A, Pellicori P, Riggio O, Giusto M, et al. Cardiac dysfunction in cirrhosis is not associated with the severity of liver disease. *Eur J Intern Med.* 2013;24(2):172-6.
 38. Papastergiou V, Skorda L, Ligos P, Papakonstantinou N, Giakoumakis T, Ntousikos K, et al. Ultrasonographic prevalence and factors predicting left ventricular diastolic dysfunction in patients with liver cirrhosis: is there a correlation between the grade of diastolic dysfunction and the grade of liver disease? *ScientificWorldJournal [Internet]*. 2012 [cited 31 Abr 2019];2012:615057. Available en: <https://doi.org/10.1100/2012/615057>
 39. Fajardo MH, Arce M, Medina Y, Esteva L, Osorio MF. Comportamiento de la cirrosis hepática en el hospital “Arnaldo Milián Castro” de julio de 2007 a marzo de 2009. *Medisur [Internet]*. 2010 [cited 31 Abr 2019];8(4):257-65. Available at: <http://medisur.sld.cu/index.php/medisur/article/view/1154/7179>
 40. Al-Hamoudi WK. Cardiovascular changes in cirrhosis: pathogenesis and clinical implications. *Saudi J Gastroenterol.* 2010;16(3):145-53.
 41. Bernardi M, Calandra S, Colantoni A, Trevisani F, Raimondo ML, Sica G, et al. Q-T interval prolongation in cirrhosis: prevalence, relationship with severity, and etiology of the disease and possible pathogenetic factors. *Hepatology.* 1998;27(1):28-34.
 42. Oberkofler CE, Dutkowski P, Stocker R, Schuepbach RA, Stover JF, Clavien PA, et al. Model of end stage liver disease (MELD) score greater than 23 predicts length of stay in the ICU but not mortality in liver transplant recipients. *Crit Care [Internet]*. 2010 [cited 31 Abr 2019];14(3):R117. Available at: <http://doi.org/10.1186/cc9068>
 43. Alexopoulou A, Papatheodoridis G, Pouriki S, Chrysohoou C, Raftopoulos L, Stefanadis C, et al. Diastolic myocardial dysfunction does not affect survival in patients with cirrhosis. *Transpl Int.* 2012;25(11):1174-81.
 44. Krowka MJ, Swanson KL, Frantz RP, McGoon MD, Wiesner RH. Portopulmonary hypertension: Results from a 10-year screening algorithm. *Hepatology.* 2006;44(6):1502-10.
 45. Krowka MJ, Miller DP, Barst RJ, Taichman D, Dweik RA, Badesch DB, et al. Portopulmonary hypertension: a report from the US-based REVEAL Registry. *Chest.* 2012;141(4):906-15.
 46. Fritz JS, Fallon MB, Kawut SM. Pulmonary vascular complications of liver disease. *Am J Respir Crit Care Med.* 2013;187(2):133-43.
 47. Talwalkar JA, Swanson KL, Krowka MJ, Andrews JC, Kamath PS. Prevalence of spontaneous portosystemic shunts in patients with portopulmonary hypertension and effect on treatment. *Gastroenterology.* 2011;141(5):1673-9.
 48. Zambruni A, Di Micoli A, Lubisco A, Domenicali M, Trevisani F, Bernardi M. QT interval correction in patients with cirrhosis. *J Cardiovasc Electrophysiol.* 2007;18(1):77-82.
 49. Huo TI, Lee SD, Lin HC. Selecting an optimal prognostic system for liver cirrhosis: the model for end-stage liver disease and beyond. *Liver Int.* 2008;28(5):606-13.
 50. Bernardi M, Calandra S, Colantoni A, Trevisani F, Raimondo ML, Sica G, et al. Q-T interval prolongation in cirrhosis: prevalence, relationship with severity, and etiology of the disease and possible pathogenetic factors. *Hepatology.* 1998;27(1):28-34.
 51. Zamirian M, Tavassoli M, Aghasadeghi K. Corrected QT interval and QT dispersion in cirrhotic patients before and after liver transplantation. *Arch Iran Med.* 2012;15(6):375-7.
 52. Krowka MJ. Hepatopulmonary syndrome versus

- portopulmonary hypertension: distinctions and dilemmas. *Hepatology*. 1997;25(5):1282-4.
53. Sagnelli E, Stroffolini T, Mele A, Almasio P, Coppola N, Ferrigno L, *et al*. The importance of HCV on the burden of chronic liver disease in Italy: a multicenter prevalence study of 9,997 cases. *J Med Virol*. 2005;75(4):522-7.
54. Escobar Suárez BJ. Repercusión de la capacidad de respuesta cardiovascular en la estabilidad hemodinámica y la aparición de complicaciones en trasplante hepático [Tesis]. España: Universidad de Barcelona [Internet]; 2013. Available at: <https://www.tdx.cat/handle/10803/121242>
55. Hoeper MM, Krowka MJ, Strassburg CP. Portopulmonary hypertension and hepatopulmonary syndrome. *Lancet*. 2004;363(9419):1461-8.
56. Kamath PS. Portopulmonary hypertension and hepatopulmonary syndrome. *J Gastroenterol Hepatol*. 2002;17(Supl 3):S253-5.
57. Wiegand J, Berg T. The etiology, diagnosis and prevention of liver cirrhosis: part 1 of a series on liver cirrhosis. *Dtsch Arztebl Int*. 2013;110(6):85-91.
58. Pascasio JM, Grilo I, López-Pardo FJ, Ortega-Ruiz F, Tirado JL, Sousa JM, *et al*. Prevalence and severity of hepatopulmonary syndrome and its influence on survival in cirrhotic patients evaluated for liver transplantation. *Am J Transplant*. 2014;14(6):1391-9.
59. Alonso Martínez JL, Zozaya Urmeneta JM, García Sanchotena JL, Olaz-Preciado F, Estébanez-Estébanez C, Berjón-Reyero J. Síndrome hepatopulmonar: Relación con el grado de disfunción hepática y el trastorno hemodinámico de la cirrosis hepática. *Med Clin (Barc)*. 2004 Nov 27;123(19):721-5.
60. Rodríguez-Roisin R, Krowka MJ, Hervé P, Fallon MB; ERS Task Force Pulmonary-Hepatic Vascular Disorders (PHD) Scientific Committee. Pulmonary-Hepatic vascular Disorders (PHD). *Eur Respir J*. 2004;24(5):861-80.
61. Schenk P, Fuhrmann V, Madl C, Funk G, Lehr S, Kandel O, *et al*. Hepatopulmonary syndrome: prevalence and predictive value of various cut offs for arterial oxygenation and their clinical consequences. *Gut*. 2002;51(6):853-9.
62. Zardi EM, Zardi DM, Chin D, Sonnino C, Dobrina A, Abbate A. Cirrhotic cardiomyopathy in the pre- and post-liver transplantation phase. *J Cardiol*. 2016;67(2):125-30.