

## Arrhythmias caused by ondansetron: Case report

Juan M. Chala Tandrón<sup>1</sup>✉, MD; Liset Jiménez Fernández<sup>2</sup>, MD, MSc; Zoila Armada Esmores<sup>2</sup>, MD, MSc; Yudileidy Brito Ferrer<sup>2</sup>, MD, MSc; Melba Zayas González<sup>2</sup>, MD, MSc; and Maiyen García Arcia<sup>2</sup>, MD

<sup>1</sup> Department of Anesthesiology and Resuscitation, Hospital Oncológico Universitario “Dr. Celestino Hernández Robau”. Santa Clara, Villa Clara, Cuba.

<sup>2</sup> Department of Pharmacology, Universidad de Ciencias Médicas de Villa Clara. Santa Clara, Villa Clara, Cuba, Cuba.

*Este artículo también está disponible en español*

### ARTICLE INFORMATION

Received: April 4, 2019

Accepted: May 21, 2019

### Competing interests

The authors declare no competing interests

### ABSTRACT

The ondansetron is used to prevent nausea and vomiting caused by chemotherapy, radiotherapy and surgery, belonging to the serotonin 5-HT<sub>3</sub> receptor antagonists, a natural substance that can cause nausea and vomiting, and it blocks its action. The ondansetron is packaged in the form of rapid disintegration tablets, as a solution to be taken orally and in ampules, for parenteral use. The case of a 67-year-old female patient is presented, with a diagnosis of breast carcinoma, who underwent radical mastectomy with axillary dissection was performed, and who received chemotherapy with adriamycin, cyclophosphamide and paclitaxel; as well as ondansetron to treat nausea and vomiting. The patient presented a wide QRS complex tachycardia after taking the drug.

**Keywords:** Ondansetron, Cardiac arrhythmias, Wide QRS complex tachycardia

### *Arritmias provocadas por ondansetrón: Presentación de un caso*

### RESUMEN

El ondansetrón se usa para prevenir las náuseas y los vómitos causados por la quimioterapia, radioterapia y cirugías, pertenece a los antagonistas de receptores de serotonina 5-HT<sub>3</sub>, una sustancia natural que puede causar náuseas y vómitos, y bloquea su acción. El ondansetrón viene envasado en forma de tabletas de desintegración rápida, como una solución para tomar por vía oral y en ampulas, para su uso parenteral. Se presenta el caso de una paciente de 67 años de edad con diagnóstico de carcinoma de mama, a la cual se realizó mastectomía radical con vaciamiento axilar, y recibió quimioterapia con adriamicina, ciclofosfamida y paclitaxel; así como ondansetrón para tratar las náuseas y vómitos. La paciente presentó una taquicardia con QRS ancho después de utilizar el fármaco.

**Palabras clave:** Ondansetrón, Arritmias cardíacas, Taquicardia con QRS ancho

✉ JM Chala Tandrón

Hospital Oncológico Universitario

Celestino Hernández Robau.

Calle Cuba 564, e/ Hospital y Barcelona. Santa Clara 50200. Villa Clara,

Cuba. E-mail address:

chalatandron@infomed.sld.cu

### INTRODUCTION

Ondansetron is a serotonin 5-HT<sub>3</sub> receptor antagonist widely used as an antiemetic agent after chemotherapy, radiotherapy and surgery. It affects the peripheral and central nerves reducing the activity of the vagus nerve, which deactivates the vomiting center in the spinal bulb; and blocks sero-

tonin receptors in the chemoreceptor trigger zone<sup>1-3</sup>. The drug is available as 4 mg and 8 mg dissolving tablets and oral solution also in (4 mg and 8 mg ampules). The first dose of ondansetron is usually taken 30 minutes before the start of chemotherapy, 1 to 2 hours before the start of radiotherapy, or 1 hour before surgery. Additional doses are sometimes taken one to three times a day during chemotherapy or radiotherapy and for one to two days after the end of treatment<sup>4,5</sup>.

Among the toxicities of Ondansetron there is a known risk of QTc prolongation on the ECG with the risk of cardiac arrhythmia which includes torsades de pointes without knowing the exact magnitude of such prolongation<sup>6,7</sup>. Such effect on QTc has been evaluated in randomized, controlled, double-blind studies<sup>6</sup>. It has been described in both the child and adult, and it can compromise the life of pediatric patients<sup>7,9</sup>.

Patients with the highest risk of suffering torsades de pointes are those having pre-existing cardiac disorders such as congenital long QT syndrome, predisposition to hypokalemia or hypomagnesemia, or those taking medications that cause prolongation of the QT interval<sup>9-11</sup>. That is why the cardiovascular effects produced by ondansetron need to be thorough-

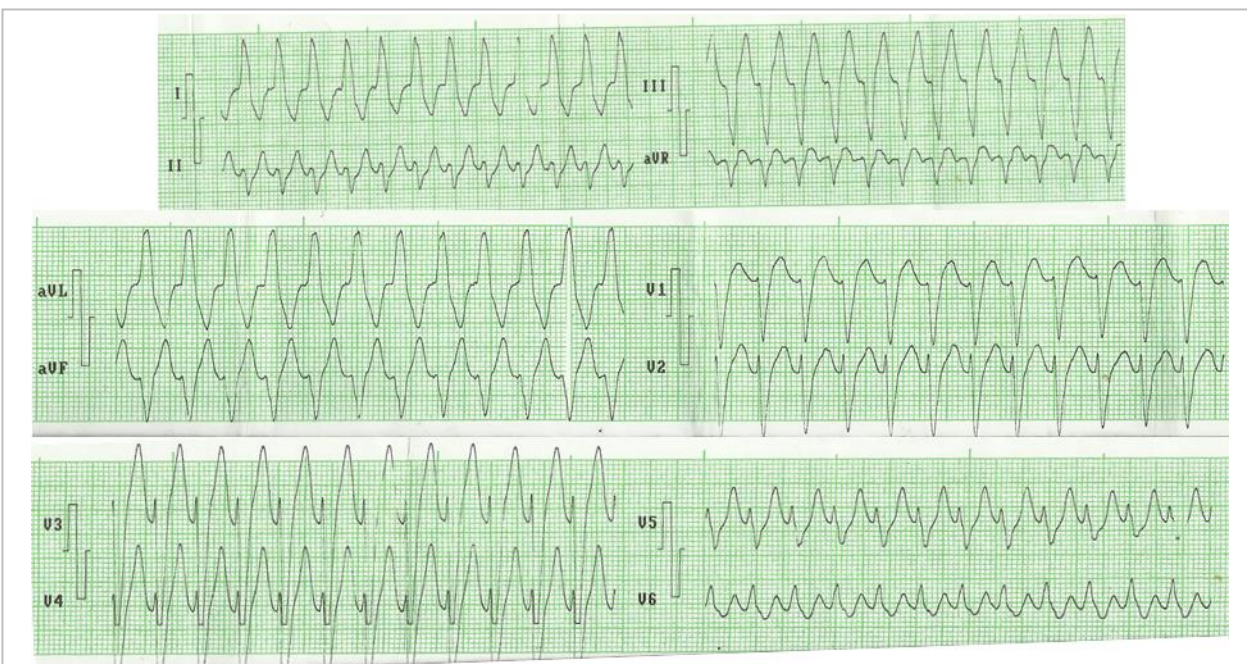
ly assessed<sup>10-12</sup>.

## CASE REPORT

A 67-year-old woman with a history of atopy, arterial hypertension and intranodal re-entry tachycardia, for which she was treated with enalapril (20 mg/day), hydrochlorothiazide (25 mg /day) and verapamil (320 mg/day); who underwent radical mastectomy with axillary emptying and chemotherapy with 4 cycles of adriamycin and cyclophosphamide, and another 4 cycles of paclitaxel under the diagnosis of right breast adenocarcinoma.

At the beginning of chemotherapy, she was commenced on ondansetron 8 mg taken orally every 8 hours. From the second tablet the patient began to feel increases in heart rate of up to 150 beats per minute, and with the fourth tablet she began with asthenia, anorexia, dizziness and strong palpitations. Upon arrival at the emergency department, an electrocardiogram was performed where a regular tachycardia with wide QRS was observed (**Figure 1**), which resolved with electrical cardioversion. **Figure 2** shows its basic rhythm.

The case was jointly discussed and the possibility



**Figure 1.** Electrocardiogram showing regular tachycardia, with wide QRS, related to the use of ondansetron.

of changing the chemotherapy regimen to try drugs that did not prolong the QT interval was assessed; but the patient showed a detailed treatment regimen and the appearance of arrhythmias where increased heart rate was associated with the ondansetron doses. Therefore, it was decided to maintain the same chemotherapy regimen and ondansetron administration was stopped; clinical or electrocardiographic manifestations completely ceased.

## COMMENTS

Since there are few studies about the adverse cardiovascular effects of ondansetron and being widely used for nausea and vomiting from radiotherapy and chemotherapy, we must take into account some aspects.

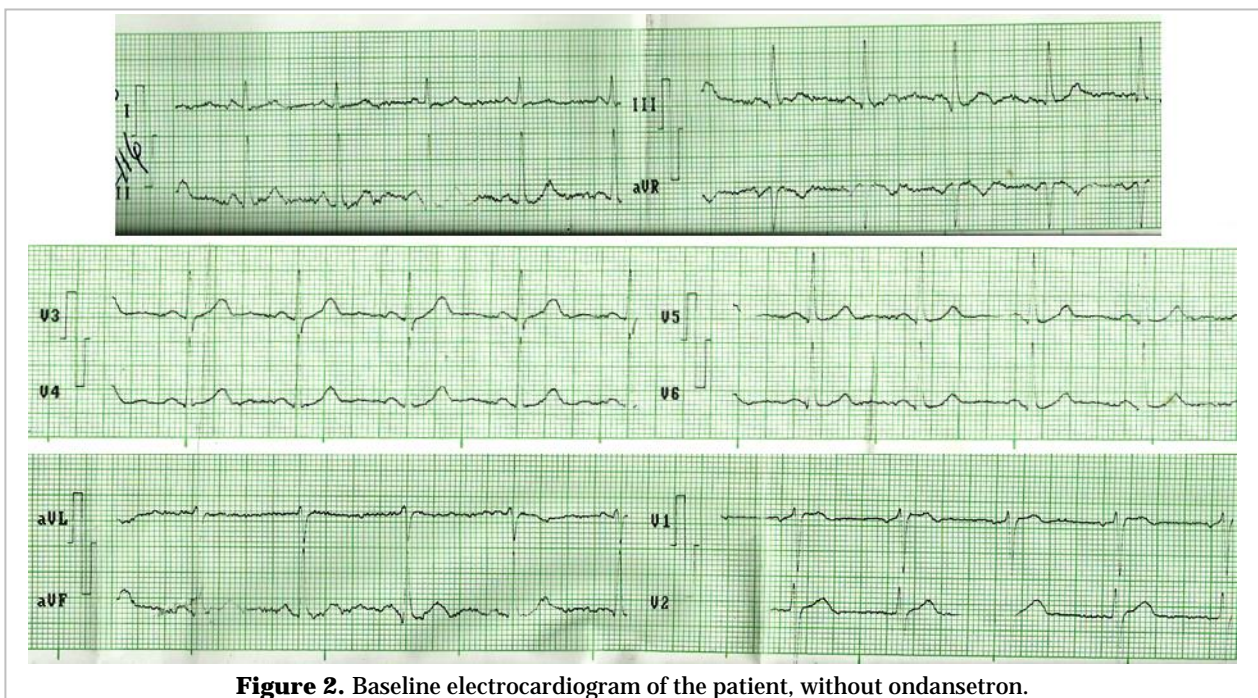
### Recommendations for the use of ondansetron:

- Ondansetron should be avoided in patients with congenital long QT syndrome, as well as in those at particular risk for cardiac arrhythmias or QT prolongation due to: administration of other drugs that prolong QT, congestive heart failure, hypokalemia, hypomagnesemia and bradyarrhythmias.

- For pediatric and adult patients receiving ondansetron as prophylaxis or treatment for postoperative nausea and vomiting, or for those caused by chemotherapy, no changes in dosage are suggested.
- In the prophylaxis of postoperative nausea and vomiting, as well as those caused by chemotherapy, single intravenous doses greater than 16 mg should be avoided.

### These drugs should not be administered with ondansetron:

- Antiarrhythmics: amiodarone, dronedarone, disopyramide, flecainide, sotalol.
- Antimicrobials: macrolides and quinolones.
- Antifungals: fluconazole, ketoconazole.
- Antidiarrheals and antiemetics: domperidone, granisetron, loperamide, metoclopramide.
- Antimalarials: quinine, chloroquine.
- Antipsychotics: chlorpromazine, clozapine, droperidol, fluphenazine, haloperidol, olanzapine, pimozide, risperidone.
- Antidepressants: amitriptyline, citalopram, escitalopram, dosulepin, doxepine, fluoxetine, imipramine, lofepramine.
- Miscellaneous: methadone, antiretrovirals (foscarnet), protein kinase inhibitors (sorafenib, sunitinib).



**Figure 2.** Baseline electrocardiogram of the patient, without ondansetron.

tinib), omeprazole, diphenhydramine, furosemide.

## REFERENCES

1. Morón Rodríguez FJ, Levi Rodríguez M. Farmacología General. La Habana: Ciencias Médicas; 2002.
2. Flórez J, Armijo JA, Mediavilla A. Farmacología humana. 6ª ed. Barcelona: Elsevier España; 2014.
3. Brunton LL, Hilal-Dandan R, Knollmann BC. Goodman & Gilman's: The Pharmacological Basis of Therapeutics. 13<sup>th</sup> ed. New York: McGraw-Hill Education; 2018.
4. Brião FF, Horta ML, Horta BL, de Barros GA, Behrendorf AP, Severo I, *et al.* Comparison of droperidol and ondansetron prophylactic effect on subarachnoid morphine-induced pruritus. *Braz J Anesthesiol.* 2015 Jul-Aug;65(4):244-8.
5. Ministerio de Salud Pública. Formulario Nacional de Medicamentos. La Habana: Editorial Ciencias Médicas; 2014.
6. Tricco AC, Soobiah C, Antony J, Hemmelgarn B, Moher D, Hutton B, *et al.* Safety of serotonin (5-HT<sub>3</sub>) receptor antagonists in patients undergoing surgery and chemotherapy: protocol for a systematic review and network meta-analysis. *Syst Rev [Internet].* 2013 [citado 31 Mar 2019];2:46. Disponible en: <https://www.ncbi.nlm.nih.gov/pmc/articles/PMC3702491/pdf/2046-4053-2-46.pdf>
7. McKechnie K, Froese A. Ventricular tachycardia after ondansetron administration in a child with undiagnosed long QT syndrome. *Can J Anesth.* 2010;57(5):453-7.
8. Buyukavci M, Olgun H, Ceviz N. The effects of ondansetron and granisetron on electrocardiography in children receiving chemotherapy for acute leukemia. *Am J Clin Oncol.* 2005;28(2):201-4.
9. Freedman SB, Hall M, Shah SS, Kharbanda AB, Aronson PL, Florin TA, *et al.* Impact of increasing ondansetron use on clinical outcomes in children with gastroenteritis. *JAMA Pediatr.* 2014;168(4):321-9.
10. Brenner SM, Boucher J. Fatal Cardiac Arrest in 2 Children: Possible Role of Ondansetron. *Pediatr Emerg Care.* 2016;32(11):779-84.
11. Faria C, Li X, Nagl N, McBride A. Outcomes Associated with 5-HT<sub>3</sub>-RA Therapy Selection in Patients with Chemotherapy-Induced Nausea and Vomiting: A Retrospective Claims Analysis. *Am Health Drug Benefits.* 2014;7(1):50-8.
12. Schwartzberg L, Barbour SY, Morrow GR, Ballinari G, Thorn MD, Cox D. Pooled analysis of phase III clinical studies of palonosetron versus ondansetron, dolasetron, and granisetron in the prevention of chemotherapy-induced nausea and vomiting (CINV). *Support Care Cancer.* 2014;22(2):469-77.