

Combined interventional and surgical treatment in pediatric patients with tetralogy of Fallot

Luis E. Marcano Sanz^a✉, PhD; Eugenio Selman-Housein Sosa^a, PhD; Alfredo M. Naranjo Ugalde^a, MD, MSc; Francisco J. Ozores Suárez^b, MD, MSc; Juan C. Ramiro Nova^b, MD, MSc; and Fernando Frías Griskho^a, MD

^a Department of Surgery.

^b Department of Hemodynamics.

Cardiocentro Pediátrico "William Soler". Havana, Cuba.

Este artículo también está disponible en español

ARTICLE INFORMATION

Received: July 06, 2013

Accepted: July 23, 2013

Competing interests

The authors declare no competing interests

Acronyms

VSD: ventricular septal defect

On-Line Versions:

Spanish - English

✉ C García Guevara

Cardiocentro Pediátrico William Soler

Avenida 100 y Perla Altahabana

CP 10800. La Habana, Cuba

E-mail address: rescv@infomed.sld.cu

ABSTRACT

In tetralogy of Fallot with hypoplastic pulmonary arteries, an alternative to avoid palliative surgeries is percutaneous pulmonary valvuloplasty using a balloon catheter. When there are major arteriovenous collaterals producing volume overload of the left chambers, their previous occlusion improves surgical outcomes. Two patients with aorto-pulmonary collaterals, closed in the laboratory of hemodynamics 24 hours before surgery, and two children who underwent pulmonary valve dilation and then surgery, seven and nine months afterwards, respectively, are reported. Mean follow-up was five years without complications. Interventional catheterization techniques before surgery for tetralogy of Fallot are feasible and can help reduce the number of palliations and improve the results of surgical correction of the disease in selected cases.

Key words: Cardiac catheterization, Cardiovascular surgery, Tetralogy of Fallot

Tratamiento combinado intervencionista y quirúrgico en pacientes pediátricos con tetralogía de Fallot

RESUMEN

En la tetralogía de Fallot con ramas pulmonares hipoplásicas, una alternativa para evitar cirugías paliativas es la valvuloplastia percutánea pulmonar con catéter de globo. Cuando existen colaterales arteriovenosas mayores que producen sobrecarga de volumen de las cavidades izquierdas, ocluir las previamente mejora los resultados quirúrgicos. Se presentan dos pacientes con colaterales aorto-pulmonares, cerradas en el laboratorio de hemodinámica 24 horas antes de la cirugía, y dos niños a quienes se les dilató la válvula pulmonar y luego recibieron cirugía, siete y nueve meses después, respectivamente. El seguimiento medio ha sido de cinco años sin complicaciones. Las técnicas de cateterismo intervencionista previas a la cirugía de la tetralogía de Fallot, son factibles y pueden contribuir a disminuir el número de paliaciones y a mejorar los resultados de la corrección quirúrgica de la enfermedad en casos seleccionados.

Palabras clave: Cateterismo cardíaco, Cirugía cardiovascular, Tetralogía de Fallot

INTRODUCTION

Diameter of pulmonary arteries is a determining factor for the correction of tetralogy of Fallot. Sometimes palliative surgeries are needed to stimulate the growth of the central pulmonary and intrapulmonary arteries. However, such interventions are not without high surgical risks¹⁻³.

A less invasive alternative is percutaneous transluminal pulmonary valvuloplasty with balloon catheter, in those who have not developed a significant infundibular stenosis²⁻⁴. This technique was described in 1986 by McCredie⁵ and allows a better distributed antegrade blood flow to both pulmonary artery branches, resulting in better anatomical conditions of patients at the time of surgical correction. Stents in the right ventricle outflow tract have also been used^{1,6}.

In other cases there are major arteriovenous collaterals producing volume overload of the left cardiac chambers and pulmonary hypertension, seriously complicating intraoperative and postoperative recovery. Their surgical closure is difficult, so that occluding them previously, via catheterization, could improve the results of corrective surgery⁷⁻¹⁰.

The aim of this case report is to describe the combined use of interventional catheterization techniques and corrective surgery in four patients with tetralogy of Fallot.

CASE REPORT

Under intravenous anesthesia with ketamine and midazolam a central venous access via the femoral artery was performed in the catheterization laboratory and in cases with multiple aorto-pulmonary collaterals, the femoral artery was also inserted. Anatomy was precisely defined by angiography.

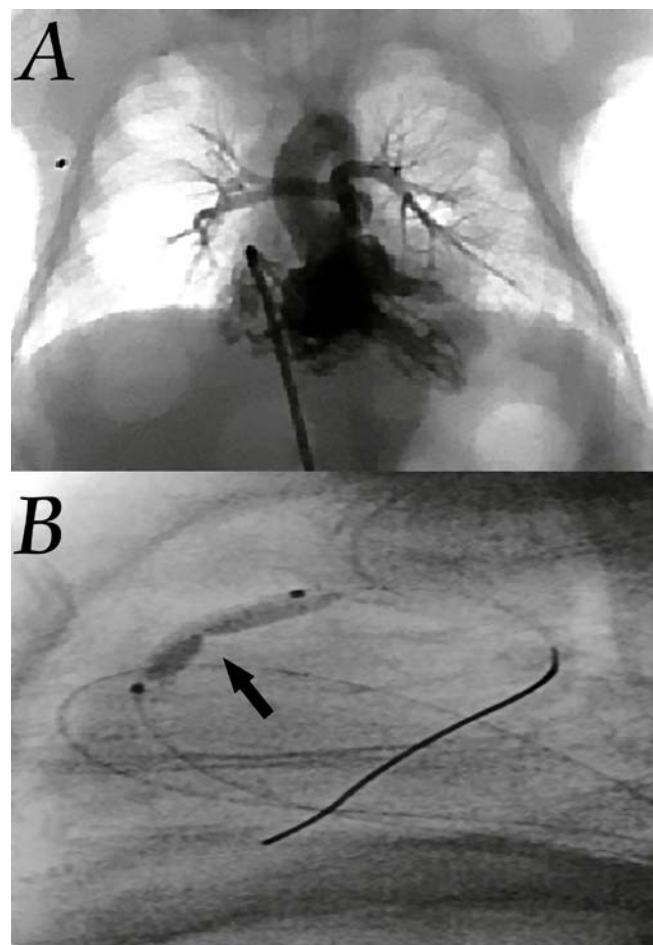
Aorto-pulmonary collaterals of significant diameter were closed with controlled release devices, 24 hours before surgery, after verifying the dual irrigation of lung segments by true pulmonary arteries.

The pulmonary valve dilation was performed with balloon catheters that exceeded 1.4 times the diameter of the pulmonary annulus (**Figure**).

Surgical and interventional details are reflected in **tables 1** and **2**. There were no hypoxia crises or serious arrhythmias during interventional procedures. In patients who received pulmonary valve dilation an improvement of the overall condition was achieved as

well as improvement of arterial oxygen saturation and of the pulmonary arteries size at the time of surgical correction.

In patients to whom collaterals were closed, cardio-pulmonary bypass was conducted with adequate pulmonary venous return and a good visualization of the surgical field, without having to lower the temperature and perfusion flow. The mean follow-up of cases has been of five years without complications. In all patients informed consent signed by the parents was obtained and procedures are part of protocols approved by the Scientific Council and the Ethics Committee of the research.



A. Anteroposterior view of angiogram with contrast injection into the right ventricle in a newborn of 11 days and 1.9 kg in weight, where the tiny branches of the pulmonary artery (2 mm) are observed. **B.** Side view which shows the balloon catheter in the right ventricular outflow and the notch at the pulmonary annulus level is indicated.

Table 1. Data of interventional treatment.

Age	Weight	Anatomy	Indication	Technique	Evolution
11 days	1,9 kg	Pulmonary branches of 2 mm	Arterial oxygen saturation: 40 %	Pulmonary valve dilation	No complications. Arterial oxygen saturation: 85 %.
9 months	5 kg	Valve stenosis and pulmonary branches of 3 mm	Arterial oxygen saturation: 55 %	Pulmonary valve dilation	No complications. Arterial oxygen saturation: 88 %.
2 years	14 kg	Thick direct collateral arteries of the aorta	Volume overload of left cardiac cavities	Closure of three collaterals of the thoracic aorta and one infradiaphragmatic	No complications. No drop in arterial oxygen saturation.
10 years	32 kg	Thick direct collateral arteries of the aorta	Volume overload of left cardiac cavities	Closure of two collaterals of the thoracic aorta	No complications. No drop in arterial oxygen saturation.

Table 2. Data of surgical treatment.

Edad	Peso	Características anatómicas	Técnica quirúrgica	Evolución y seguimiento
9 months	8 kg	Significant improvement of pulmonary branches. Right 5 mm and left 5,7 mm	Correction. No pulmonary annulus section.	No complications at 5 years
16 months	10 kg	Mixed infundibular and valvular stenosis. Appropriate branches	Correction with a section of the pulmonary annulus and patch enlargement with monocuspid valve of autologous pericardium	No complications at 3 years
2 years	14 kg	Mixed supra-ventricular, infundibular and valvular stenosis.	Correction with a section of the pulmonary annulus and patch enlargement with monocuspid valve of autologous pericardium	No complications at 7 years
10 years	32 kg	Mixed supra-ventricular, infundibular and valvular stenosis.	Correction with a section of the pulmonary annulus and patch enlargement with monocuspid valve of autologous pericardium	No complications at 5 years

COMMENT

In tetralogy of Fallot, although the correction at a time is preferred, sometimes the anatomical characteristics make us choose palliative measures. Systemic pulmonary Blalock-Taussig shunt is the usual measure in

such cases. However, its morbidity is significant. The rate of mortality in preterm or low weight at birth is 10 to 18%^{2,3}.

The opening of the outflow tract of the right ventricle, without closing the ventricular septal defect

(VSD) is another option that increases the effective transpulmonary antegrade flow and may promote the growth of the pulmonary arteries. However, this must be done under cardiopulmonary bypass and is very difficult to predict the magnitude of the flow through the VSD, so congestive heart failure, prolonged mechanical ventilation and long term pulmonary hypertension occur frequently².

Percutaneous transluminal pulmonary valvuloplasty with balloon catheter is an alternative in which valvular obstruction predominates and hypoplasia at the pulmonary arterial branches is also present²⁻⁵. The accepted indications are: arterial oxygen saturation below 80 %, hypoxia crisis and lung perfusion dependent of ductus arteriosus^{2,5}.

In these circumstances, an improvement in the growth of the main pulmonary artery, in the size of its branches and in oxygen arterial saturation has been reported^{2,3,5}. For some, although there is an immediate increase in the annulus, its growth remains abnormal and a transannular patch may be required at the surgical moment⁴.

This method of treatment that could palliate about half of symptomatic newborns and young infants with tetralogy of Fallot, is less effective in those who have had recurrent hypoxia crisis. The growth achieved in the pulmonary arteries is comparable to that of the systemic pulmonary shunt^{2,3}.

The complications reported are mainly in older children in whom the infundibular component is predominant and thus the incidence of serious arrhythmias, or in newborns with less than 2,500 grams, in whom crossing the valve is more difficult³.

Benefits with the use of stents in the right ventricular outflow are identified when compared with systemic pulmonary shunts, as they prevent complications and technical difficulties of placing them in so tiny branches. Potential limitations of these interventional procedures include obstruction due to endothelial proliferation, device fracture and cardiac perforations^{1,4,6}.

Surgical ligation or section of undesirable vascular connections between the aorta and the pulmonary vasculature, which is established in some patients, can considerably increase surgical time, extracorporeal circulation, and besides being technically difficult due to its position, can predispose to profuse bleeding. Pulmonary venous return during cardiopulmonary

bypass can be of great magnitude, and the perfusion flow is diverted from such important organs such as the brain and kidneys^{7,8}.

The usefulness and effectiveness of closing them before surgery has currently been demonstrated, with a level of evidence B, as long as there is native pulmonary circulation in the affected segments⁹. It was recently proposed to carry it out as hybrid procedures during surgery¹⁰. Valvular balloon dilation and the closing of major collaterals in a single patient was also reported⁴.

Interventional catheterization techniques before surgery for tetralogy of Fallot are feasible and can help reduce the number of palliations and improve the results of surgical correction of the disease in selected cases.

REFERENCES

1. Laudito A, Bandisode VM, Lucas JF, Radtke WA, Adamson WT, Bradley SM. Right ventricular outflow tract stent as a bridge to surgery in a premature infant with Tetralogy of Fallot. *Ann Thorac Surg.* 2006;81(2):744-6.
2. Wu ET, Wang JK, Lee WL, Chang CC, Wu MH. Balloon valvuloplasty as an initial palliation in the treatment of newborns and young infants with severely symptomatic Tetralogy of Fallot. *Cardiology.* 2006;105(1):52-6.
3. Kohli V, Azad S, Singh M, Joshi S, Joshi R, Makram E. Balloon dilation of the pulmonary valve in premature infants with Tetralogy of Fallot. *Pediatr Cardiol.* 2008;29(5):946-9.
4. Kreutzer J, Perry S, Jonas R, Mayer J, Castañeda A, Lock J. Tetralogy of Fallot with diminutive pulmonary arteries: preoperative pulmonary valve dilation and transcatheter rehabilitation of Pulmonary arteries. *J Am Coll Cardiol.* 1996;27(7):1741-7.
5. McCredie RM, Swinburn MJ, Lee CL, Warner, G. Balloon dilatation pulmonary valvuloplasty in pulmonary stenosis. *Aust N Z J Med.* 1986;16(1):20-3.
6. Dryzek P, Mazurek-Kula A, Moszura T, Sysa A. Right ventricle outflow tract stenting as a method of palliative treatment of severe tetralogy of Fallot. *Cardiol J.* 2008;15(4):376-9.
7. Seltzer S, Aboulhosn J, Levi DS. Use of interlock fibered detachable coils for occlusion of collaterals, coronary artery fistulae, and patent ductus arteriosus. *Catheter Cardiovasc Interv.* 2009;74(5):770-6.

8. Inamura S, Sakurai Y, Kawada S, Shohtsu A, Kuribayashi S. Improvement of heart failure after intracardiac operation for tetralogy of Fallot by transcatheter embolization of major aortopulmonary collateral arteries. *Kyobu Geka*. 1990;43(3):219-21.
9. Feltes TF, Bacha E, Beekman RH, Cheatham JP, Feinstein JA, Gomes AS, et al. Indications for cardiac catheterization and intervention in pediatric cardiac disease: A scientific statement from the American Heart Association. *Circulation*. 2011; 123(22):2607-52.
10. Li SJ, Zhang H, Sheng XD, Yan J, Deng XC, Chen WD, et al. Intraoperative hybrid cardiac surgery for neonates and young children with congenital heart disease: 5 years of experience. *Ann Thorac Cardiovasc Surg*. 2010;16(6):406-9.