

## Prenatal diagnosis of double aortic arch

Carlos García Guevara<sup>a</sup>✉, MD, MSc; Yamelic Bernal Pérez<sup>b</sup>, MD; Yalili Hernández Martínez<sup>a</sup>, MD, MSc; Andrés Savío Benavides<sup>a</sup>, PhD; Francisco Díaz Ramírez<sup>a</sup>, MD; Carlos García Morejón<sup>a</sup>, MD, MSc

<sup>a</sup> Cardiocentro Pediátrico "William Soler". Havana, Cuba.

<sup>b</sup> Centro Municipal de Genética de Marianao. Havana, Cuba.

*Este artículo también está disponible en español*

### ARTICLE INFORMATION

Received: April 22, 2013

Accepted: June 04, 2013

### Competing interests

The authors declare no competing interests

Acronyms

**AoA:** aortic arch

On-Line Versions:

Spanish - English

✉ C García Guevara

Cardiocentro Pediátrico William Soler  
Avenida 100 y Perla Altahabana

CP 10800. La Habana, Cuba

E-mail address:

carlos.guevara@infomed.sld.cu

### ABSTRACT

A case is reported with sonographic examination performed in the second trimester of pregnancy, in which the presence of a double aortic arch was suspected. Fetal echocardiography, performed at Cardiocentro Pediátrico "William Soler", a reference center for prenatal diagnosis of congenital heart disease in Cuba, confirmed the suspicion of such diagnosis performed at a primary health care center. The double aortic arch is a rare congenital abnormality; this condition, together with the few cases with prenatal diagnosis reported in the literature, led us to its publication.

**Key words:** Double aortic arch, Right aortic arch, Prenatal diagnosis, Congenital heart disease

### *Diagnóstico prenatal de doble arco aórtico*

### RESUMEN

Se presenta un caso, con examen sonográfico realizado en el segundo trimestre de la gestación, en los cuales se sospechó la presencia de un doble arco aórtico. El estudio ecocardiográfico fetal, realizado en el Cardiocentro Pediátrico "William Soler", centro de referencia para el diagnóstico prenatal de cardiopatías congénitas en Cuba, confirmó la sospecha del referido diagnóstico realizado en la atención primaria de salud. El doble arco aórtico es una anomalía congénita poco frecuente; situación esta que, junto a los pocos casos referidos en la bibliografía con diagnóstico prenatal, motivó su publicación.

**Palabras clave:** Doble arco aórtico, Arco aórtico derecho, Diagnóstico prenatal, Cardiopatía congénita

### INTRODUCTION

The defects of the aortic arch (AoA) are present in 1-2% of human fetuses and may be related to complex heart defects or classified as normal variants, which are rarely associated with clinical signs after birth<sup>1,2</sup>.

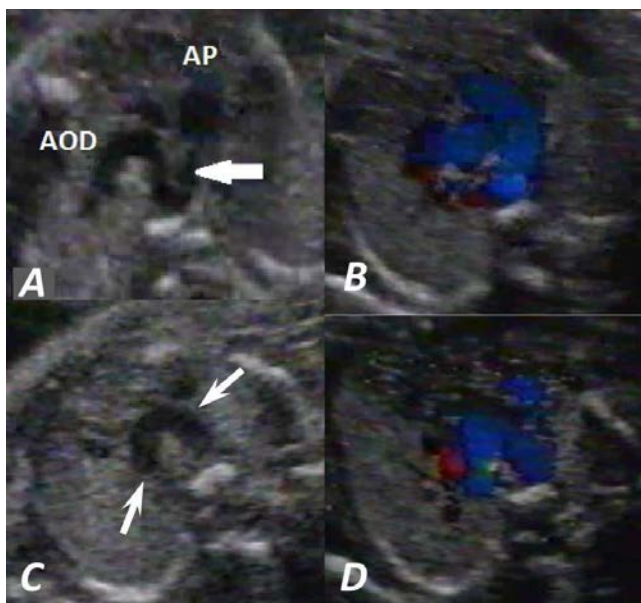
One such anomaly is double AoA, also considered a form of vascular ring where

the trachea and esophagus are surrounded in the form of a circle by the right and left AoA<sup>3</sup>.

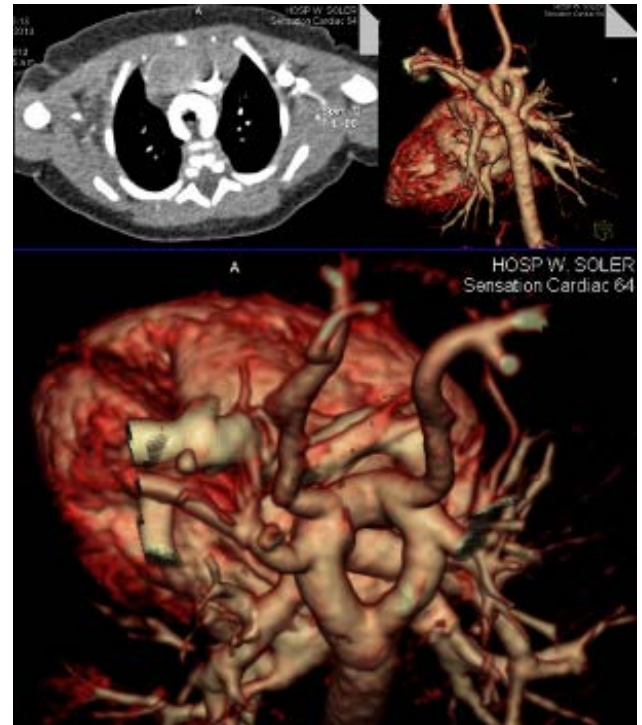In this paper a patient with this type of congenital heart disease is presented. This rare condition and the few cases reported in the literature with prenatal diagnosis, led us to publish this article.

## CASE REPORT

With the consent of the couple, the case of a 20 year-old primigravida with early detection of pregnancy, gestational age of 23 weeks and classified as low genetic risk is presented. She was referred to the national reference center for prenatal diagnosis of congenital heart diseases due to a suspected heart defect, found in the view of the three vessels in the ultrasound. Fetal echocardiography was performed with ALOKA 5500, a Japanese equipment with a 5 MHz convex transducer, and Doppler technology (pulsed, continuous and color). The essential element for diagnosis was the full view of the three vessels<sup>4</sup>, where from the classic view with previous movements of the



**Figure 1.** **A.** Fetal echocardiographic view of the transverse aortic arch, where both AoAs are observed. The arrow identifies the left *ductus* that connects to the left AoA. **B.** Equivalent image with color-coded flow. **C.** Both arches (right and left are being identified by the two arrows). **D.** Color Doppler demonstrates the presence of both arches. PA: pulmonary artery. RAA: right aortic arch.



**Figure 2.** CT angiography study of patients with different types of slices, where both aortic arches are showed.

transducer, the presence of two arcs of similar caliber could be visualized. They originated from the last portion of the ascending aorta and both had posterior direction and passed through their respective bronchi, ending in the descending aorta (**Figure 1**). The presence of single *ductus* was demonstrated (left).

A C-section was performed at 40.3 weeks without complications, and the newborn had a weight of 3,100 grams and a size of 49 cm, with Apgar scores of 9/9. From the beginning he presented stridor, respiratory distress and suffocation crises during suckling. Esophagogram under fluoroscopic screen was performed, where an extrinsic compression on the back was found at the level of the middle third of the esophagus, suggestive of this disease. CT angiography was subsequently performed with a Siemens multislice equipment of 64 channels (**Figure 2**), which showed the presence of a double aortic arch. Pediatric Echocardiography showed the presence of an atrial septal defect of 2.5mm (like an oval fossa) and mild tricuspid regurgitation.

The patient underwent corrective surgery and was discharged from hospital without complications.

## COMMENT

In normal cardiovascular development conditions, the fourth left AoA will constitute the aortic arch, while the fourth AoA will turn into the right brachiocephalic trunk (which will contain the right carotid and right subclavian arteries), and will always be the first vessel of the neck. Conversely, when the AoA that develops is the right one, an AoA to the right will be produced, and in this situation, the fourth left arc will become the brachiocephalic trunk innominate artery (in this case containing the left carotid and left subclavian arteries), and will be also the first vessel of the neck. When the two AoA quarters (right and left) are developed, the different variables of AoA will be produced, and since in this congenital anomaly both fourth AoAs are "used", there is no brachiocephalic trunk and therefore, the first vessels of the neck are the carotid arteries, which originate independently. The absence of brachiocephalic trunk therefore, is a key factor in doubtful diagnoses of double aortic arch<sup>5</sup>.

This disease was suspected during prenatal ultrasound screening, when performing the echocardiographic view of the three vessels, which together with the four-chamber view, left ventricular long axis and short axis of the aorta, are part of the ultrasound screening program that is performed to all pregnant women in our country between 20 and 24 weeks.

In the aforementioned echocardiographic view, the presence of an ascending aorta was evidenced, with unusual separation of the pulmonary artery, from where an arc that originated and descended through the right bronchus and the trachea at a position to the left of it was observed. Also, the case was referred with the suspicion of the existence of another arc of similar caliber in the opposite direction (that is to the left) which left the trachea in a position to the right of this. What is typical in this disease is not the similar size of the two arcs as was found in our patient, but their difference, which is why the right one is larger in most cases, and in many of them the left one may be atresic<sup>6</sup>.

At the national reference center for prenatal diagnosis of congenital heart diseases, the previous observation was found, especially when performing extended view of the three vessels with a more anterior move of the transducer, where the cross-sectional view of the AoA was obtained which could be

identified with gentle movements in both arches.

The angled view of the arch and the ductus simultaneously allowed to identify the presence of the AoA on the right, but not the presence of the left AoA. In other echocardiographic views it was not possible to identify suspicious signs of the anomaly and let alone its diagnosis.

Echocardiography also showed the unilateral presence of the *ductus* (left), as shown in **Figure 1A**, although in this disease a right or bilateral ductus may also be found<sup>6</sup>.

At birth, the presence of stridor was observed in the patient. This symptom along with dysphagia are the typical elements of this congenital anomaly because both arcs compress the trachea and esophagus<sup>7-8</sup>. The patient underwent surgery without complications.

It is considered that if during the screening ultrasound the operator uses the view of the three vessels, the suspected diagnosis of this type of heart disease would increase, allowing earlier diagnosis and early behavior anticipadas.

## REFERENCES

1. Chaoui R, Rake A, Heling SK. Aortic arch with four vessels: aberrant right subclavian artery. *Ultrasound Obstet Gynecol.* 2008;31(1):115-7.
2. García C, Savi A, García C, Somoza F, Arencibia J, Marantz P. Diagnóstico prenatal de anillo vascular con arco aórtico derecho. *Rev Argent Cardiol.* 2012;80(3): 250-3.
3. Seo HK, Je HG, Kang IS, Lim KA. Prenatal double aortic arch presenting with a right aortic arch and an anomalous artery arising from the ascending aorta. *Int J Cardiovasc Imaging.* 2010;26(Suppl 1): 165-8.
4. Tongsong T, Tongprasert F, Srisupundit K, Luewan S. The complete three-vessel view in prenatal detection of congenital heart defects. *Prenat Diagn.* 2010;30(1):23-9.
5. Somoza F, Bruno M, editors. *Cardiología pediátrica. Cardiología perinatal.* Argentina: ISAG; 2007.
6. Díaz GF, Vélez JF, Cabrera C. Anomalías de los arcos aórticos. En: Díaz Góngora G, Sandoval Reyes N, Vélez Moreno J, Carrillo Ángel G, editores. *Cardiología Pediátrica.* Bogotá: McGraw-Hill; 2003. p. 281-95.

7. Cox DA, Quinn RD, Moran AM. Two cases of a double aortic arch with left arch atresia. *Cardiol Young*. 2011;21(2):220-1.
8. Zidere V, Tsapakis EG, Huggon IC, Allan LD. Right aortic arch in the fetus. *Ultrasound Obstet Gynecol*. 2006;28(7):876-81.