









Atrial fibrillation by accessory pathway with pattern of ventricular pre-excitation: A case report

Lázaro A. Mata Cuevas¹ , MD; Jesús J. Roque Corzo¹ , MD; Jesús A. Pérez González¹ , MD; Celibel García Meneses¹ , MD; Caleb Vegas Peraza² , MD; Carla Mata Carvajal² , MD; Lilibet Vegas Peraza² , MD; and Yailem Companioni Sola¹ , BSc

¹ Department of Cardiology. Hospital General Docente Mártires del 9 Abril. Sagua la Grande, Villa Clara, Cuba.

² Facultad de Ciencias Médicas de Sagua la Grande, Universidad de Ciencias Médicas de Villa Clara. Santa Clara, Villa Clara, Cuba.

Este artículo también está disponible en español

ARTICLE INFORMATION

Received: November 22, 2019
Accepted: January 3, 2020

Competing interests

The authors declare no competing interests.

Figures

Images from complementary tests are shown with patient's consent.

Abbreviations

AF: Atrial fibrillation
AV: Atrioventricular
WPW: Wolff-Parkinson-White

✉ C Vegas Peraza

Carretera Circuito Norte a Quemado de Güines, km 2½. Sagua La Grande 52300. Villa Clara, Cuba.

E-mail address:

cavegas2605@nauta.cu

ABSTRACT

Atrial fibrillation by accessory pathway is a dangerous disease that can cause sudden death, it is rare and it needs a careful management, even more, if a pattern of ventricular pre-excitation appears. The case of a white skin 17-year-old teenager with a history of short palpitations at moderate effort, and occasional loss of consciousness of short duration, without other associated symptoms, is presented. At the moment of admission, he presents palpitations, fatigue, pallor and low blood pressure; in the electrocardiogram a tachycardia with wide, irregular QRS, with delta wave and rapid ventricular rate is observed, which was interpreted as pre-excited atrial fibrillation. Synchronized electrical cardioversion to QRS with 100 joules was performed, and sinus rhythm was restored with electrocardiographic pattern of ventricular pre-excitation (Wolff-Parkinson-White syndrome).

Keywords: Atrial fibrillation, Syncope, wide QRS complex tachycardia, Ventricular pre-excitation

Fibrilación auricular por vía accesoria con patrón de preexcitación ventricular: Informe de un caso

RESUMEN

La fibrilación auricular por vía accesoria es una peligrosa enfermedad que puede provocar muerte súbita; es poco frecuente y necesita una conducta exacta, mucho más si aparece un patrón de preexcitación ventricular. Se presenta el caso de un adolescente masculino de 17 años de edad y piel blanca, con antecedentes de palpitaciones cortas a esfuerzos moderados y pérdida ocasional del conocimiento de breve duración, sin otra sintomatología asociada. Al momento del ingreso presenta un cuadro de palpitaciones, fatiga, palidez e hipotensión arterial, y en el electrocardiograma se observa una taquicardia con QRS ancho, irregular, con onda delta y frecuencia ventricular rápida, que fue interpretada como fibrilación auricular preexcitada. Se realiza cardioversión eléctrica sincronizada al QRS con 100 julios y se logra restaurar el ritmo sinusal con patrón electrocardiográfico de preexcitación ventricular (síndrome de Wolff-Parkinson-White).

Palabras clave: Fibrilación auricular, Síncope, Taquicardia con QRS ancho, Pre-excitación ventricular.

INTRODUCTION

Historically speaking, the presence of atrioventricular (AV) conduction pathways considered as accessory was enunciated in parallel to the discovery of the regular conduction system. By the end of the 19th century, the concept of the conduction of the electrical impulse from atriums to ventricles confronted the proponents of myogenic conduction with the proponents of neurogenic conduction¹.

Atrial fibrillation (AF) is the most frequent sustained arrhythmia in clinical practice. In spite of the fact that its underlying mechanism continues to be the subject of controversy among electrophysiologists, AF probably corresponds to a complex interaction between stimuli that cause its initiation and the atrial anatomical substrate required for its perpetuation².

The origin of the impulses is predominantly found in the pulmonary veins and may correspond to variable forms of abnormal focal automatism, or activity triggered in the vein or to micro-reentrant circuits around the pulmonary veins openings under an intense influence of the autonomic system. The pulmonary veins not only contribute to the AF's initiation, but also participate in maintaining the arrhythmia. Other non-pulmonary triggers have also been described, such as those in the coronary sinus, the superior vena cava or the ligament of Marshall^{2,3}.

Its diagnostic electrocardiographic characteristics are: the absence of a sinus P wave, irregular baseline, presence of a variable R-R interval, variable atrial heart rate between 350 and 600 beats per minute and narrow QRS complexes (<120 milliseconds), in the absence of other conduction disorders; it may be presented as wide QRS complex tachycardia

(>120 milliseconds) in patients with bundle branch block or aberrant infrahisian conduction. From a clinical point of view, it can be asymptomatic or it can be presented with non-specific symptoms, such as dyspnea on exertion, palpitations, angina or syncope⁴.

It is considered the most frequent arrhythmia in clinical practice⁵. Its global prevalence is 0.4%, increasing from 2-5% in patients over 60 years old and it gets up to 10% in those over 80 years old. In Colombia, there has been an increase in its incidence (0.35 per 1000 treated patients in 2010) and it affects mainly males (male-female ratio of 1:1.27), in the seventh decade of life and with a mortality rate of 0.0468 per 1000 inhabitants in the period from 2000 to 2009^{4,6}.

Syncope may be the initial manifestation of a cardiac arrhythmia and it may indicate danger for the patient's life. The case presented here is an example of the importance of an adequate treatment for a patient with palpitations, syncope and an electrocardiogram with a wide QRS tachycardia.

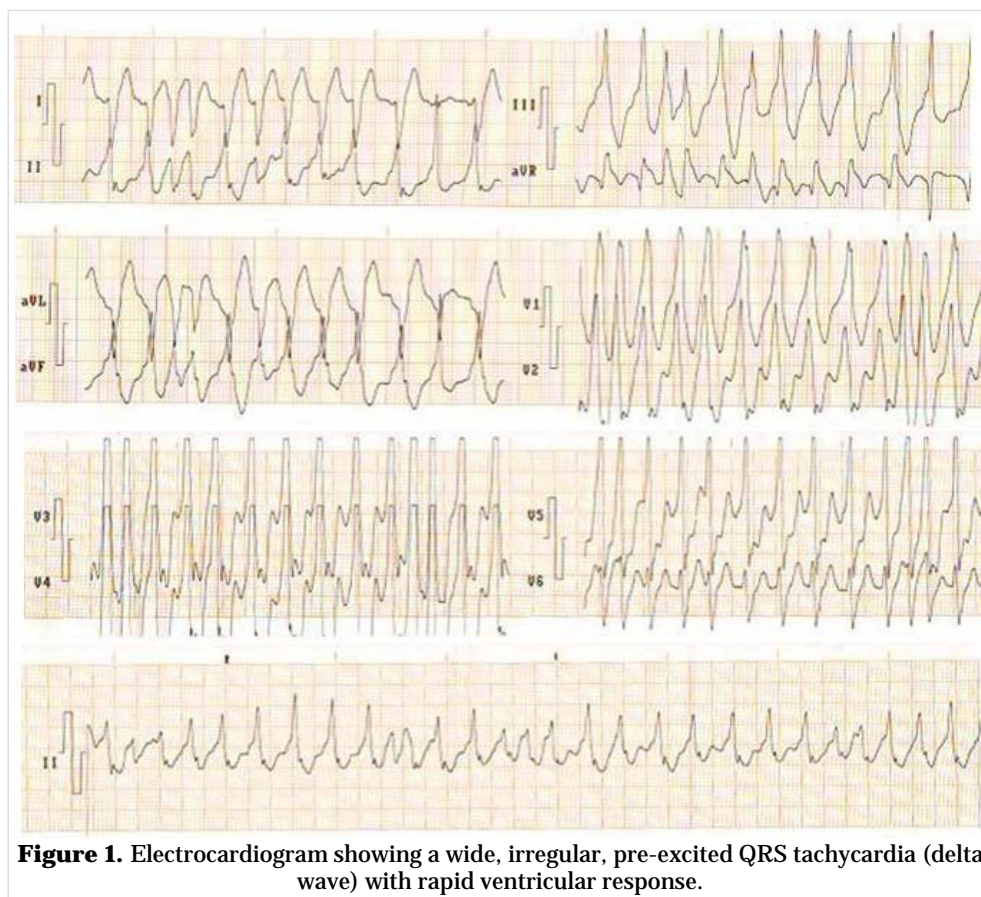


Figure 1. Electrocardiogram showing a wide, irregular, pre-excited QRS tachycardia (delta wave) with rapid ventricular response.

CASE REPORT

White skin color 17-year-old male teenager, with a history of short duration palpitations during moderate effort; however, he has also been woken up during some nights (without any physical effort), who also reports two episodes accompanied by extreme fatigue and brief loss of consciousness completely recovered later.

He goes to the doctor in his health care area, where he is evaluated by the pediatrics and cardiology specialists without finding any clinical disorder, not even in the performed complementary tests. This last time he was taken to the Emergency Department at *Hospital General Docente Mártires del 9 Abril* of Sagua la Grande, presenting similar symptoms: rapid palpitations that woke him up, accompanied by fatigue, pallor and weakening. During the initial physical examination tachycardial heart sounds, fine and irregular rapid pulse, mucocutaneous pallor, blood pressure of 80/50 mmHg, heart rate of 146 beats per minute and respiratory rate of 13 breaths per minute were noted.

The electrocardiogram showed a tachycardia with wide, irregular, delta wave QRS, with rapid ventricular response (**Figure 1**), which was interpreted as a pre-excited AF, with hemodynamic repercussion. Synchronized electrical cardioversion with 100 joules was performed to the QRS, and sinus rhythm was restored, showing an electrocardiographic pattern of ventricular pre-excitation, Wolff-Parkinson-White syndrome (**Figure 2**).

The patient evolved favorably and he was transferred to the *Instituto de Cardiología y Cirugía Cardiovascular* (Havana, Cuba) which is a national reference center, where the ablation of the accessory pathway was carried out.

COMMENTS

There are currently two classifications recommended by the clinical practice guidelines of the European Society of Cardiology^{4,6,7}, which define AF according to its pattern, duration and clinical type:

- First event: initial event in a patient with no previous diagnosis, regardless of its duration and related symptoms.
- Paroxysmal: event lasting between 48 hours and seven days, including those cases with electrical or pharmacological cardioversion in the first 48 hours.
- Persistent: event lasting more than seven days and less than one year, including those with pharmacological or electrical cardioversion after 48 hours.
- Long-term persistent: duration equal to or greater than one year in patients to whom the sinus rhythm has been decided to be recovered.
- Permanent: event lasting more than one year, or one of less duration, in which the

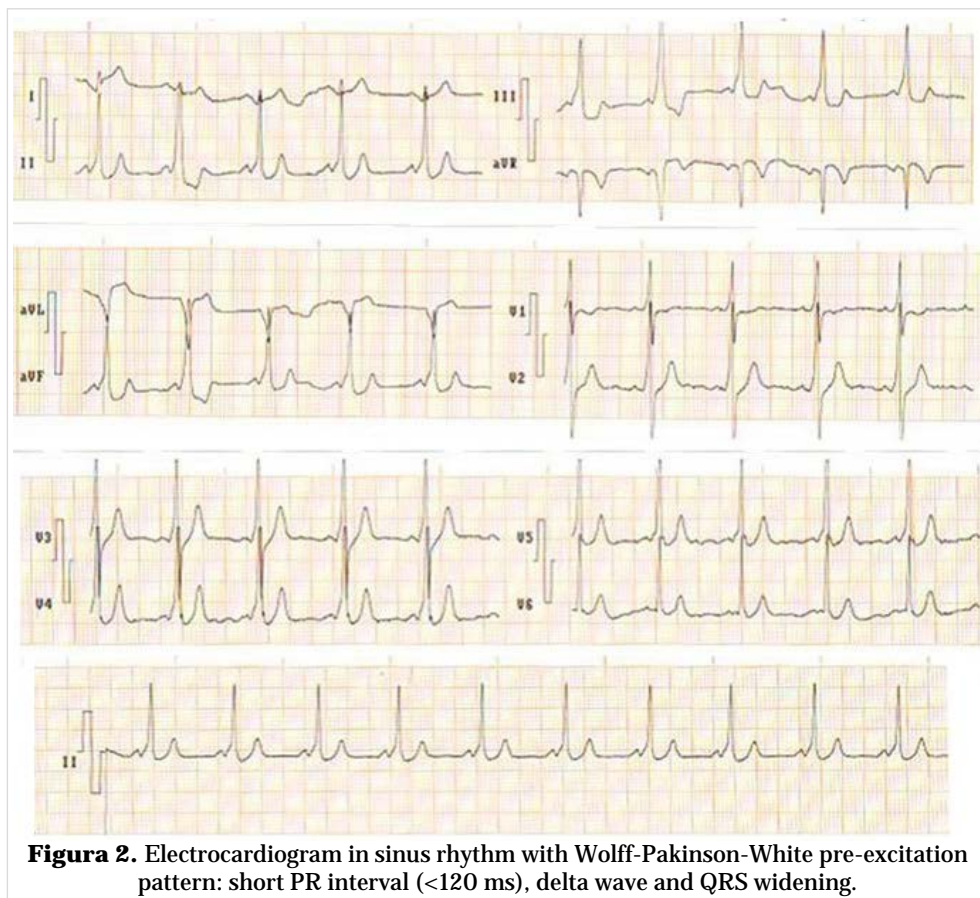


Figura 2. Electrocardiogram in sinus rhythm with Wolff-Parkinson-White pre-excitation pattern: short PR interval (<120 ms), delta wave and QRS widening.

doctor and the patient agree that recovery of sinus rhythm will not be sought.

Closely related to AF are ventricular pre-excitation syndromes, so called because the ventricles begin their electrical activation (excitation) earlier than it would be expected, hence the term “pre-excitation”. Its main exponent is the Wolff-Parkinson-White syndrome (WPW), alluding to those who have described it. This phenomenon is due to the existence of an anomalous connection or accessory pathway that typically “jumps” the annulus of the mitral or tricuspid valves, it is inserted proximally at some atrial point and distally at some ventricular point, and it has an electrical conduction at a higher speed than through the AV node⁸. Patients with pre-excitation syndromes can also suffer from AF, thus, it is very possible for a “tachycardia with participation of the accessory pathway” to take place^{8,9}.

The name of WPW syndrome is applied to situations in which there is ventricular pre-excitation (short PR and wide QRS with initial notch called delta wave) and a tendency to paroxysmal tachycardia by these anomalous AV pathways. Most of these bundles are characterized by rapid conduction in both directions^{10,11}, so that different types of tachycardia can appear: orthodromic, antidromic, and being associated with flutter or atrial fibrillation⁸, with danger of degenerating into ventricular fibrillation.

Syncope, a very prevalent situation that is a frequent cause of medical consultation¹², in certain patients can be presented in the form of very recurrent crises that seriously affect their life quality. Moreover, between 6-30% of patients, depending on their age and the context in which they are analyzed, present syncope due to a cardiac cause throughout their lives, which –sometimes– is the first manifestation of their disease and can be a marker of poor prognosis with risk of sudden death⁴. Hence, the importance of a comprehensive assessment of any patient treated due to an episode of transitory loss of consciousness.

Currently, there are two ways of approaching AF, one of which is aimed at reducing the deleterious electromechanical effects of the arrhythmia on the myocardium and the other, at reducing the appearance of thromboembolic complications^{4,13}.

If a patient with WPW syndrome presents an AF, the administration of drugs that block the AV node (beta-blockers, verapamil, adenosine, digoxin) is contraindicated because they favor conduction through

the accessory pathway and it would lead to tachycardia or ventricular fibrillation. If the patient is not unstable enough to require urgent electrical cardioversion, intravenous procainamide is the best choice for acute treatment. Other effective options are flecainide, propafenone, ajmaline and amiodarone^{9,11,13,14}.

The evolutionary behavior of WPW can lead to different situations such as its total disappearance or, on the contrary, the beginning of symptoms compatible with cardiac arrhythmias, as occurred in the present case. Some studies, with long-term follow-up, describe the clinical evolution of these patients. Cain *et al*¹⁵ mention a 35% of children under three months old and a 6% of those older than that with spontaneous disappearance; furthermore, they refer a 11% of previously asymptomatic patients with more than one event of arrhythmia in their evolution, similar to the 12% described by Santinelli and coworkers¹⁶.

CONCLUSIONS

The pattern of ventricular pre-excitation can be detected in young populations that are asymptomatic or have few symptoms, and can be associated to the appearance of atrial fibrillation. It is important to take into account each and every one of the semiological, physiological and electrocardiographic aspects present in patients with rapid arrhythmias, where wide QRS with fibrillary characteristics and the presence of delta wave are seen, allowing the diagnosis to be established and timely treatment to be applied in order to avoid therapeutic mistakes. The definitive behavior of choice is the ablation of the accessory pathway.

REFERENCES

1. Moya-I-Mitjans Á, Rivas-Gándara N, Sarrias-Mercè A, Pérez-Rodón J, Roca-Luque I. Síncope. *Rev Esp Cardiol*. 2012;65(8):755-65.
2. Larraitz G, Marchlinski FE, Betensky BP. Mecanismos de las arritmias. *Rev Esp Cardiol*. 2012; 65(2):174-85.
3. Altamirano R. Alternativas terapéuticas en la fibrilación auricular. *Rev Med Las Condes*. 2018;29(1): 69-75.
4. Forero-Gómez JE, Moreno JM, Agudelo CA, Rodríguez-Arias EA, Sánchez-MoscOSO PA. Fibrila-

- ción auricular: enfoque para el médico no cardiólogo. *Iatreia*. 2017;30(4):404-22.
5. Macle L, Cairns J, Leblanc K, Tsang T, Skanes A, Cox JL, *et al*. 2016 Focused Update of the Canadian Cardiovascular Society Guidelines for the Management of Atrial Fibrillation. *Can J Cardiol*. 2016;32(10):1170-85.
 6. Pava-Molano LF, Perafán-Bautista PE. Generalidades de la fibrilación auricular. *Rev Colomb Cardiol*. 2016;23(Supl 5):5-8.
 7. Kirchhof P, Benussi S, Kotecha D, Ahlsson A, Atar D, Casadei B, *et al*. 2016 ESC Guidelines for the management of atrial fibrillation developed in collaboration with EACTS. *Eur Heart J*. 2016;37(38):2893-962.
 8. Almendral J, Castellanos E, Ortiz M. Taquicardias paroxísticas supraventriculares y síndromes de preexcitación. *Rev Esp Cardiol*. 2012;65(5):456-69.
 9. Cis-Spoturno A, Valenzuela-Candelario L, López-Zea M, Beas-Jiménez JD. Preexcitación ventricular: dificultad en el tratamiento de un caso de Wolff-Parkinson-White en un deportista. *Rev Andal Med Deporte*. 2014;7(2):90-3.
 10. Puga Bravo M, Navia Intriago OL, Gómez Hernández A, Gómez Núñez K. Fibrilación auricular por vía accesoria. *Rev Cuban Cardiol [Internet]*. 2018 [cited 19 Nov 2019];24(2). Available at: http://revcardiologia.sld.cu/index.php/revcardiologia/article/view/739/pdf_124
 11. González Zuelgaray J, Abud AM, Abud M, Picolini A, Szyszko AE. Fibrilación auricular en situaciones especiales. *Rev Urug Cardiol*. 2016;31(1):138-64.
 12. Baron-Esquivias G, Martínez-Alday J, Martín A, Moya A, García-Civera R, Paz López-Chicharro M, *et al*. Epidemiological characteristics and diagnostic approach in patients admitted to the emergency room for transient loss of consciousness: Group for Syncope Study in the Emergency Room (GESINUR) study. *Europace*. 2010;12(6):869-76.
 13. Restrepo-Jaramillo CA. Cardioversión farmacológica. *Rev Colomb Cardiol*. 2016;23(Supl. 5):52-6.
 14. Negrete-Salcedo A, Gil-Roncancio E. Estrategias para el control de la frecuencia cardíaca en pacientes con fibrilación auricular. *Rev Colomb Cardiol*. 2016;23(Supl 5):108-11.
 15. Cain N, Irving C, Webber S, Beerman L, Arora G. Natural history of Wolff-Parkinson-White syndrome diagnosed in childhood. *Am J Cardiol*. 2013;112(7):961-5.
 16. Santinelli V, Radinovic A, Manguso F, Vicedomini G, Gulletta S, Paglino G, *et al*. The natural history of asymptomatic ventricular pre-excitation a long-term prospective follow-up study of 184 asymptomatic children. *J Am Coll Cardiol*. 2009;53(3):275-80.