

Modifications to the classic simple-longitudinal inferior pericardiotomy (Sauerbruch technique)

Yoandy López-de la Cruz[✉], MD, MSc; and Yolepsis F. Quintero-Fleites, MD, MSc

Department of Cardiovascular Surgery, Hospital Provincial Universitario Cardiocentro Ernesto Che Guevara. Santa Clara, Villa Clara, Cuba.

Este artículo también está disponible en español

ARTICLE INFORMATION

Received: March 10, 2019

Accepted: April 11, 2019

Competing interests

The authors declare no competing interests

ABSTRACT

Since the 1960s, subxyphoid pericardiotomy has become one of the preferred surgical procedures for rapidly and safely evacuating pericardial effusions of different etiologies, obtaining biopsies, placing epicardial electrodes, and even repairing cardiac perforations. This surgery is erroneously thought to require specific surgical instruments and specially trained personnel; but the plain fact is that any doctor working in an emergency department must know the technique and be ready to perform it at any time. Since the longitudinal incision was described, originally attempting to repair a cardiac wound through the diaphragm, some authors have tried to simplify the procedure through innovations. In this article we present some simple maneuvers that may facilitate subxyphoid pericardial access and shorten the surgery time.

Keywords: Pericardium, Pericardial effusion, Pericardiocentesis, Modification of surgical technique

Modificaciones a la técnica clásica de pericardiotomía inferior longitudinal simple de Sauerbruch

RESUMEN

Desde la década de 1960 la pericardiotomía subxifoidea se ha convertido en uno de los procedimientos quirúrgicos preferidos para evacuar, de forma rápida y segura, derrames pericárdicos de múltiples etiologías, obtener biopsias, colocar electrodos epicárdicos, e incluso reparar perforaciones cardíacas. Erróneamente existe la creencia de que esta cirugía requiere instrumental quirúrgico específico y personal especialmente entrenado; pero lo cierto es que todo médico que labore en un servicio de emergencia debe conocer la técnica y estar preparado para realizarla rápidamente. Desde que se describió la incisión longitudinal, originalmente con la intención de reparar una herida cardíaca a través del diafragma, varios autores han intentado simplificar la técnica mediante la introducción de innovaciones. En este trabajo se presentan algunas sencillas maniobras que pueden facilitar el abordaje subxifoideo al pericardio y acortar el tiempo de cirugía.

Palabras clave: Pericardio, Derrame pericárdico, Pericardiocentesis, Modificación de técnica quirúrgica

✉ Y López de la Cruz
Ave 26 de Julio, Edificio 306 Apto. 18.
Reperto Escambray Sur.
Santa Clara, Villa Clara, Cuba.
E-mail address:
yoandylc@infomed.sld.cu

INTRODUCTION

It has been reported that Claudius Galen of Pergamum removed the ster-

num and anterior wall of the pericardium from a soldier in whom a neglected wound of the chest had led to the development of a suppurative pericarditis¹. However, man's first efforts to evacuate pericardial fluids probably date back to the beginning of the thirteenth century, but interestingly it is not found in any surgical text. The earliest account of an approach to the pericardial cavity, to drain a hemo-pericardium, is found in the first lines of the tenth book in the poem "Parzival, a knightly epic" written by Wolfram von Eschenbach allegedly around 1210, and set in the prairies of the sixth century Europe². This charming and richly convoluted medieval poem tells that Sir Gawain, one of the Knights of King Arthur's Round Table, found a dying wounded man who had been pierced by a spear; he quickly understood that the blood was compressing his heart, and decided to evacuate it with a cannula made from a lime branch, which could undoubtedly be considered as the oldest description of a pericardiocentesis. The passage ends with the following words: "the hero's strength revived so that he could speak and talk again..."³.

Since the mid-seventeenth century several surgeons began to propose approaches to evacuate the pericardial cavity by trephination of the sternum or small intercostal openings^{4,5}, but there is no clear evidence that such attempts were carried out before 1800¹.

At present, most experts agree that the first surgical drainage of the pericardial cavity was performed by the Catalan surgeon Francisco Romero in the spring of 1801. The patient was 35-year-old Antonio de Mira suffering from pericardial hydrops, and the physician accessed the pericardium by means of an unspecified length-thoracotomy above the sixth left rib curvature, where its cartilage begins^{4,6}.

Almost three decades later, in 1829, the chief surgeon of Napoleon Bonaparte's armies, Baron Dominique Jean Larrey, after five years of experimentation in the search for an unobstructed access to the pericardium, described the oblique subcostal route⁷⁻⁹, which from our perspective has fallen into disuse nowadays.

Probably the first approach to the heart through a longitudinal subxiphoid incision took place around 1911. That year, a surgeon by the name of Fuchsig (difficult to find other information about his life) reported the repair of a right ventricular injury resulting from a stab wound to the chest. The wound perforated the diaphragm and his surgery showed for the first time the possibility of suturing the heart

through an opening in that muscle, with full recovery of the patient¹⁰. In the operation, a midline incision of about 12-15 cm from the base of the xiphoid process downwards was performed; the midline aponeurosis was opened and the peritoneal fat was carefully removed to release the inferior wall of the mentioned cartilage and proceed to resect it.

The technique was completed, after blunt dissection to break up the phrenic-external insertions, with a 2 cm incision in the diaphragm, which allowed exploration, with good visibility, of the diaphragmatic wall of the heart¹¹.

Later, the most renowned surgeon of the first half of the 20th century, Ernst Ferdinand Sauerbruch, modified Fuchsig's incision and called it simple-longitudinal inferior pericardiotomy. Some authors place this description in the year 1926¹², but it's unlikely that the gifted German would have taken 15 years to make his contributions to the procedure, especially when it is known that he had already been operating on the heart since the beginning of the century and innovating maneuvers that are still described in current surgical texts^{9,13}. It seems that the year Sauerbruch published his monumental work *Thoracic Surgery*, which describes the procedure, has historically been taken as the date to locate the origin of the technique¹⁴; that, surely, he had already devised decades earlier. However, we must point out that we are simply speculating, since we have not found a description of the procedure at earlier dates and unfortunately, the great Teutonic surgeon did not mention this aspect in his autobiography¹⁵.

The Department of Cardiovascular Surgery at the Cardiocentro in Villa Clara performs every year more than a dozen pericardial evacuation procedures in patients without prior sternotomy, from a number of medical centers in the central region of the country, and especially from an adjacent cancer hospital, since subxiphoid pericardiotomy is the classic surgical treatment for pericardial effusion of neoplastic origin^{16,17}. Below, some modifications made by the authors, in the last five years, to the pericardial subxiphoid approach described by Sauerbruch (modification of Fuchsig's), and misnamed "Parsonnet" in many surgical services of our country are thoroughly commented and analyzed.

TECHNIQUE

The technique described by Sauerbruch also opens

the skin exactly at the midline, but the incision is only 5-6 cm long and its first step is to release the anterior wall of the xiphoid process; which is not immediately resected, but pulled upwards by means of a retractor. This maneuver allows to release the lateral walls (up to the angles with the seventh ribs) and sectioning, with a scalpel, the middle fingerings of the diaphragm (sternal portion) that are inserted in the middle of the base of the mentioned cartilage. After performing the cut, the pericardium is finally accessed and opened with a small incision.

The longitudinal incision performed by the authors of this work is not developed in the midline, but in a left paraxiphoid location, also in an approximate length of 5-6 cm (**Fig. 1A**). It is not considered necessary to release the anterior wall of the xiphoid process much less resect it; it is only necessary to cut the left lateral end tissue with electro-scalpel or scissors, up to the cartilage of the seventh rib, long enough to allow deep blunt digital dissection and the placement of two blunt Kocher retractors, that facilitate elevation of the sternum on the right side and of the last sternocostal cartilage on the left side.

By inserting the index finger in the direction of

the patient's left shoulder, the surgeon will usually be able to palpate the cardiac activity, irrespective of the amount of effusion. The opening of a layer that visually resembles the pericardium, where the heartbeat cannot be felt beneath it, usually leads to the abdominal cavity.

An important feature of the technique is the removal of the subxiphoid mediastinal fat layer¹⁸ covering the pericardium to allow for tight and proper grip. No specific instruments have been described for this specific maneuver¹⁹. It may be performed using the suction cannula, a long gauze-protected clamp, or by tearing the fatty tissue with an Allis or ring forceps. Once a small segment of the pericardium has been exposed, the next step is to grasp it in order to gradually and thoroughly open it. A fairly simple way to facilitate this procedure consists of anchoring the pericardium with a thick suture-wide stitch, thus allowing its traction almost up to the level of the skin; At this point, the surgeon could either decide to perform the pericardiotomy or perform another stitch some distance from the first, to make the incision between the two.

The placement of counter-opening drainage and

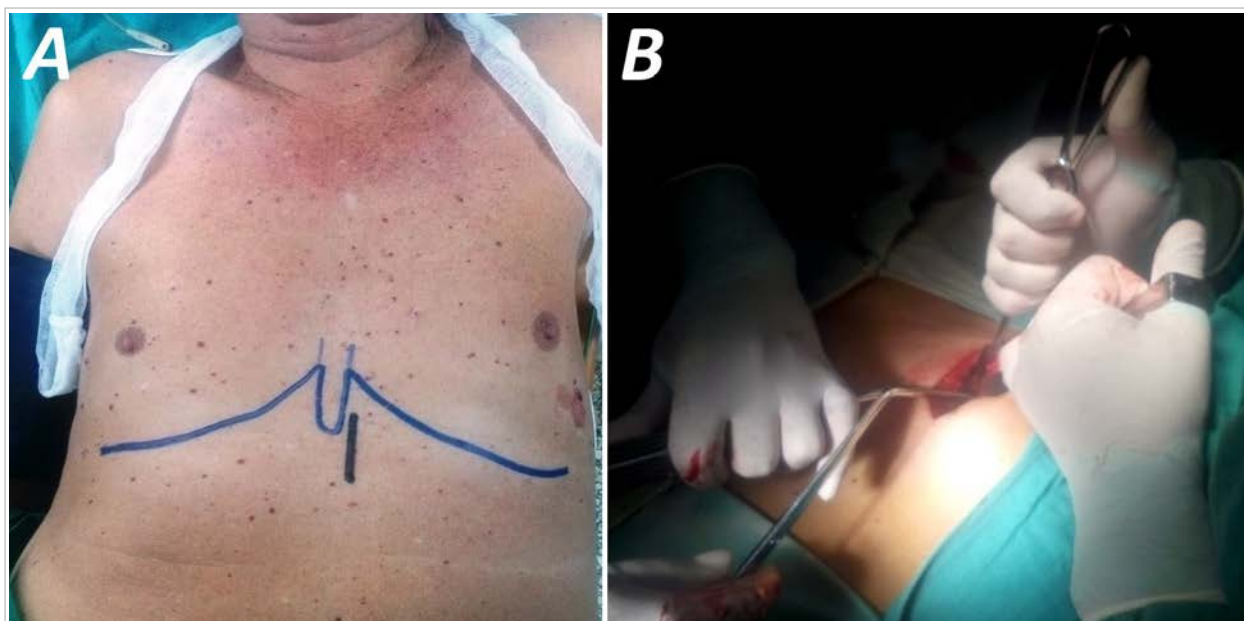

Fig. 1. A. Preoperative sketch for the site of the small incision in a left paraxiphoid line. Subsequent traction and elevation of the wound edges will allow the dissection to be extended to the last costosternal angle without requiring the skin incision to be widened. **B.** The combined use of aspiration and mobilization of pre-pericardial fat, while being extracted with Allis forceps, has become an effective strategy in patients. This maneuver can be concluded by firmly clamping the pericardium, if not too tensed.

closure of the incision are performed as usual. We have actually obtained excellent results by closing all layers with a single absorbable suture thread; First addressing the aponeurosis and concluding with an intradermal closure of the skin including the knot at the end of the wound.

COMMENTS

The progressive use of pericardial window techniques began in the mid-1960s, when many surgical groups were no longer satisfied with pericardiocentesis²⁰, as it often fails to achieve complete fluid evacuation and is associated with high rates of recurrence²¹ and complications²². That moment also marked the beginning of multiple efforts to modify the classical techniques that began to be described in the late 1820s, in an attempt to achieve less bloody approaches and reduce their complications; The introduction of the echocardiographic guidance for pericardial puncture in 1979 is a good example^{23,24}.

Subxyphoid longitudinal pericardiotomy is a safe²⁵, efficient²⁶ and easy-to-perform technique²⁷, which should be mastered by all surgeons, and even by physicians working in emergency departments. It does not require sophisticated surgical instruments; It is advisable to perform it in the operating room with general endotracheal anaesthesia²⁴, but it is also performed in emergency situations¹⁹, with local anaesthesia²⁵ or even without it. It is currently indicated mainly in scenarios where, for whatever reason, the performance of ultrasound-guided pericardiocentesis is not possible, or when the presence of clotted blood, adhesions and septa preventing total evacuation of the effusion is suspected. A different variation of the technique is performed in the post-operative period of cardiovascular surgery^{26,30}, where the opening of a small distal segment of the sternotomy facilitates drainage by digitally dissecting the layers until reaching the pericardial cavity.

As for the incision in the simple-longitudinal inferior pericardiotomy, its midline location has remained the same over time^{7,21,25,31,32}. In the review of the literature we found no other group supporting our initiative to open the skin in a paraxiphoid line, although-obviously-some reports may have been overlooked. In all the descriptions found, the incision is made in the linea alba above some portion of the xiphoid, an aspect that is considered to be of

little advantage, since afterwards surgeon have to cope with its interposition, often having to resect it^{13,19,25-27,32-35}. The technique presented here avoids, if possible, disturbing the anatomy of this cartilage. We have never needed to dissect its anterior aspect or its right edge, nor section the xiphoid process. We must remember that some terminal leads of the internal thoracic artery are disseminated around the xiphoid process³⁶, and that if injured, bleeding may be difficult to correct, which in any case will delay the surgical procedure. Since 190 years ago Larrey had already confirmed that the shortest route to the pericardium begins at the angle of the xiphoid process with the seventh rib¹, some extensive midline incisions that even reach the navel are unreasonable³¹, as is the proposal by certain authors to complement the longitudinal opening with a cross-section cut³².

Interestingly, removing the pre-pericardial fat that hampers visual identification of the segment to be controlled could be the most delayed phase of the surgery, since it is quite firm and therefore difficult to remove with the suction cannula but at the same time is very loose and could easily be torn in the attempt to remove it with forceps. The authors have no preference for a specific procedure to carry out this lipectomy; Perhaps the best strategy is simply a clever combination of the two methods (**Fig. 1B**). Some groups stress the importance of performing a careful hemostasis at this stage of surgery to avoid misdiagnosis once the pericardium has been opened^{13,34}.

Practice and experience have shown us that such a concern is groundless if the principles we have presented so far are respected. It is really very unlikely that any major vessel will be injured; most bleeding in our patients is controlled spontaneously, and in the specific case of subxyphoid mediastinotomy in patients with recent sternotomy, we have never had to use the electrocautery during surgery.

In our first subxyphoid pericardiotomies we found it difficult to control the pericardium to open it. Every cardiovascular surgeon knows how difficult it can be to grab a tensed pericardium between two forceps, even by means of a median longitudinal sternotomy. Nevertheless, most authors report clamping with Allis or Kocher forceps before opening. However, from experience we can state that in the presence of a large effusion, this grip is generally weak and quickly fails, leading to loss of control and prolonging surgery, even after the pericardiotomy has been performed. The maneuver obviously becomes

more complex through a small skin incision, with poor visibility and above all in obese patients with constrictive pericarditis³¹, or with an elevated diaphragm due to gastric distension. As for the latter circumstance, we obtained favorable results with the placement of a nasogastric tube in one of our patients, undergoing emergency surgery in the post-prandial period.

Controlling the pericardium with a thick stitch, widely inserted to avoid tearing it when pulled, is a harmless maneuver that makes opening the cavity much easier. The authors of this work do so in all cases (**Fig. 2**), even in those where effective control of the pericardium with forceps has been achieved, since there is an imminent risk of coming loose during traction, as previously mentioned. It is obvious that the stitch must be inserted almost tangentially to avoid myocardial injury, although we should not be too concerned since the interposed fluid band prevents this situation. In this sense, we consider that the maneuver is safe even with small effusions, since it is in this portion of the pericardial sac where there is a less intimate relationship between the heart and the mesothelial layer that covers it³⁷, therefore, this is the site of choice for carrying out “blind” pericardiocentesis³⁸⁻⁴⁰.

Abundant effusions, with tensioned pericardium, begin to drain spontaneously and rapidly through the orifices that the needle has drilled; at this point the fluid can be collected for pertinent analysis. The stitch traction allows the pericardium to be brought closer, practically at skin level, thus facilitating its opening with a scissors or, if better control is desired, with the placement of another stitch and subsequent pericardiotomy between the two (**Fig. 3**). The positioning of a second stitch is advantageous because, once the cavity has been opened, one of them (generally the most distal) provides excellent reference for taking a biopsy sample from the surrounding pericardium; while effective control of the opening by means of the most proximal stitch is maintained, which will also facilitate adequate placement of the drain tube.

Some of the procedures we have commented on are modifications that the authors have added to the longitudinal inferior pericardiotomy technique proposed by Sauebruch⁴¹ at the beginning of the last century. Their application has managed to considerably reduce the duration of the surgery, as less than three minutes are used between the skin incision and pericardiotomy, in patients without excessive obesity. During the last five years, no complications

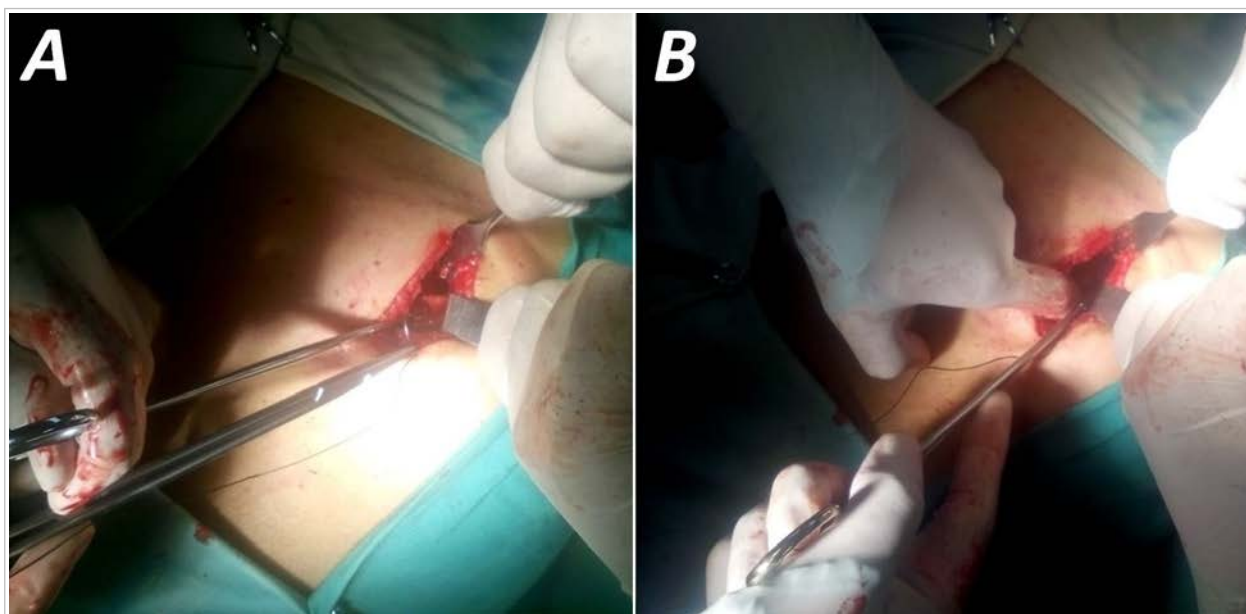


Fig. 2. A. Even if the pericardium is clamped, a wide thick silk stitch is always placed for better control during pericardiotomy. **B.** When it is difficult to grasp the pericardium by tension or the forceps slip when pulled, a simple digital depression of the diaphragm will allow sufficient field to tangentially insert the stitch into the mesothelial layer.

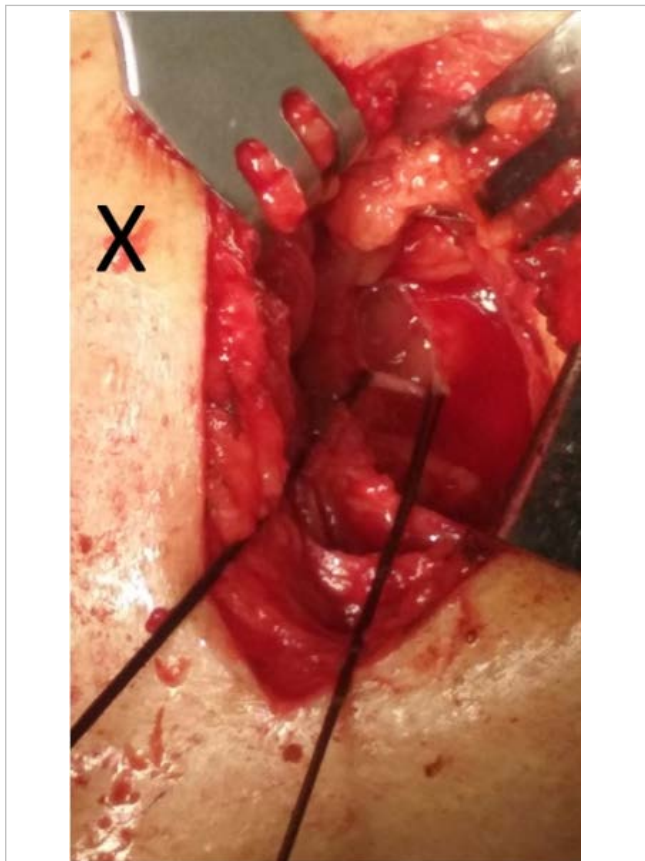


Fig. 3. A silk suture can be used for traction of the pericardium to bring it closer to the skin. Once the effusion has been evacuated, a circular cut in the pericardium around one of the stitches will make it easier to take a biopsy. In this patient the xiphoid process remained practically intact in its normal position (marked with an X); there was no bleeding and the pericardium was opened in less than three minutes.

related to the operative procedure, during or after surgery, have occurred in the group of patients where these innovations have been performed. We could not assure that these modifications are exclusively performed by our group and this article is not intended to establish a precedent for authorship. We only wish to share our experience with the community of surgeons, to continue perfecting their beautiful work of curing diseases simply with their hands.

REFERENCES

1. Winslow N, Shipley AM. Pericardiotomy for pyopericardium. Review of literature to may, 1927, and report of ten new cases. *Archives of Surgery*. 1927;15(3):317-50.
2. Farrar W. Parzival's pericardial puncture. *Ann Intern Med*. 1980;92(5):640.
3. von Eschenbach W. Parzival: A knightly epic. New York: O. E. Stechert & Co.; 1912.
4. Saplacan V, Cuttone F, Massetti M. The Ignored Birth of Cardiac Surgery: The History of the Surgical Treatment of Heart Wounds and Pericardial Effusions. En: Picichè M, editor. *Dawn and Evolution of Cardiac Procedures*. Rome: Springer-Verlag; 2013. p. 19-28.
5. Baue AE, Blakemore WS. The Pericardium. *Ann Thorac Surg*. 1972;14(1):81-106.
6. Hernández Estefanía R. Ludwig Rehn: las virtudes de un pionero. *Cir Cardio*. 2008;15(2):211-6.
7. Santos GH, Frater RW. The subxiphoid approach in the treatment of pericardial effusion. *Ann Thorac Surg*. 1977;23(5):467-70.
8. Tóth I, Rami-Porta R, Rendeki S, Molnár TF. First steps in the management of pericardial effusion: Who was first to relieve the pericardial sac - Larrey or Romero? *World J Surg*. 2013;37(9):2242-5.
9. Asensio JA, Ceballos JJ, Forno W, Gambaro E, Chahwan S, Marengo J, *et al*. Lesiones cardíacas penetrantes. Una revisión desde sus orígenes históricos hasta las últimas fronteras en el nuevo milenio. *Cir Esp*. 2000;67(1):64-79.
10. Pool EH. Treatment of heart wounds. Report of successful cardiorrhaphy and tabulation of cases. *Ann Surg*. 1912;55(4):485-512.
11. Kleinschmidt O. Operaciones en el mediastino. En: Kirschner M, editor. *Tratado de Técnica Operativa General y Especial*. Barcelona: Editorial Labor S.A.; 1944. p. 704-1036.
12. Dittrich H, Achatzy R. Technique of permanent pacemaker implantation. En: Schaldach M, Furman S, eds. *Advances in Pacemaker Technology*. Berlin: Springer-Verlag; 1975. p. 25-54.
13. Tesoriero R. Cardiac Injury. En: Scalea TM, editor. *The Shock Trauma: Manual of Operative Techniques*. New York: Springer Science+Business Media; 2015. p. 173-94.
14. Sauerbruch F. *Cirugía del tórax*. Barcelona: Labor; 1926.
15. Sauerbruch F. *Mi vida. Memorias de un cirujano*. Barcelona: Ediciones Destino; 1954.
16. Maker VK, Guzman-Arrieta ED. *Cognitive Pearls in General Surgery*. New York: Springer Science+Business Media; 2015.
17. Montañez-Valverde RA, Olarte NI, Zablah G, Hur-

- tado-de-Mendoza D, Colombo R. Swinging heart caused by diffuse large B-cell lymphoma. *Oxf Med Case Reports* [Internet]. 2018 [citado 10 Feb 2019];9:299-301. Available at: <https://www.ncbi.nlm.nih.gov/pmc/articles/PMC6109201/pdf/omy075.pdf>
18. Agarwal V, Uretsky S, Makaryus AN. Multimodality Imaging (X-Ray, CT, and MRI) in Pericardial Disease. En: Herzog E, editor. *Management of Pericardial Disease*. Heidelberg: Springer; 2014. p. 89-105.
 19. Kurimoto Y, Maekawa K, Tanno K, Mori K, Koyanagi T, Ito T, *et al*. Blind subxiphoid pericardiectomy to relieve critical acute hemopericardium: A final report. *Eur J Trauma Emerg Surg*. 2012; 38(5):563-8.
 20. Hankins JR, Satterfield JR, Aisner J, Wiernik PH, McLaughlin JS. Pericardial window for malignant pericardial effusion. *Ann Thorac Surg*. 1980;30(5): 465-71.
 21. Langdon SE, Seery K, Kulik A. Contemporary outcomes after pericardial window surgery: Impact of operative technique. *J Cardiothorac Surg* [Internet]. 2016 [citado 11 Feb 2019];11(1):73. Disponible en: <https://cardiothoracicsurgery.biomedcentral.com/track/pdf/10.1186/s13019-016-0466-3>
 22. Sakanoue I, Hamakawa H, Okubo Y, Minami K, Miyamoto E, Shomura Y, *et al*. Efficacy and safety of thoracoscopic pericardial window in patients with pericardial effusions: A single-center case series. *J Cardiothorac Surg* [Internet]. 2016 [citado 11 Feb 2019];11(1):92. Available at: <https://cardiothoracicsurgery.biomedcentral.com/track/pdf/10.1186/s13019-016-0488-x>
 23. Bhargava M, Wazni OM, Saliba WI. Interventional pericardiology. *Curr Cardiol Rep* [Internet]. 2016 [citado 16 Feb 2019];18(3):31. Available at: <https://doi.org/10.1007/s11886-016-0698-9>
 24. Sherrid MV. Echocardiography-Guided Pericardial Drainage. En: Herzog E, editor. *Management of Pericardial Disease*. Heidelberg: Springer; 2014. p. 139-47.
 25. Vincent JL, Hall JB. *Encyclopedia of Intensive Care Medicine*. Berlin: Springer-Verlag; 2012.
 26. Schmid C. Cardiac Tumors and Pericardial Diseases. En: Ziemer G, Haverich A, eds. *Cardiac Surgery*. Berlin: Springer-Verlag; 2017. p. 995-1008.
 27. Johnston DR. Surgical management of pericardial diseases. *Prog Cardiovasc Dis*. 2017;59(4):407-16.
 28. Halpern DG, Agarwal V, Lilly LS. Etiologies of Pericardial Diseases. En: Herzog E, editor. *Management of Pericardial Disease*. Heidelberg: Springer; 2014. p. 11-26.
 29. van Schil P, Paelinck B, Hendriks J, Lauwers P. Pericardial Window. En: Astoul P, Tassi G, Tschopp JM, eds. *Thoracoscopy for Pulmonologists: A Didactic Approach*. Berlin: Springer-Verlag; 2014. p. 197-204.
 30. Ergunes K, Iner H, Yurekli I, Gokalp O, Yetkin U, Gurbuz A. The post-pericardiectomy syndrome causing cardiac tamponade and pleural effusion in a patient that underwent mitral valve replacement. *J Cardiothorac Surg* [Internet]. 2015 [citado 20 Feb 2019];10(Supl 1):A112 [Resumen]. Available at: <http://www.cardiothoracicsurgery.org/content/10/S1/A112>
 31. Prager RL, Wilson CH. The subxiphoid approach to pericardial disease. *Ann Thorac Surg*. 1982; 34(1):6-9.
 32. Balaram SK, Teng A, Praeger J. *Surgical Management of Pericardial Disease* En: Herzog E, editor. *Management of Pericardial Disease*. Heidelberg: Springer; 2014. p. 149-65.
 33. Jackson JR, Ford HR, Kim ES. Pediatric Perioperative Complications and Emergencies. En: Y Fong, Kauffmann RM, Marcinkowski E, *et al*, eds. *Surgical Emergencies in the Cancer Patient*. Heidelberg: Springer; 2017. p. 289-301.
 34. Milia DJ, Paul JS. Overview of Chest Trauma. En: Dua A, Desai SS, Holcomb JB, *et al*, eds. *Clinical Review of Vascular Trauma*. Berlin: Springer-Verlag; 2014. p. 131-44.
 35. Tissot C. Pericardial Diseases. En: Da Cruz EM, Ivy D, Jaggars J, eds. *Pediatric and Congenital Cardiology, Cardiac Surgery and Intensive Care*. London: Springer-Verlag; 2014. p. 2369-94.
 36. Harky A, Mohammad HA, Garner M, Ali M, Alani MS. Anomalous right internal thoracic artery terminating in the right superior pulmonary vein. *Ann Thorac Surg*. 2017;104(4):e323-4.
 37. Hoit BD. Anatomy and physiology of the pericardium. *Cardiol Clin*. 2017;35(4):481-90.
 38. Gluer R, Murdoch D, Haqqani HM, Scalia GM, Walters DL. Pericardiocentesis – How to do it. *Heart Lung Circ*. 2015;24(6):621-5.
 39. Petri N, Ertel B, Gassenmaier T, Lengenfelder B, Bley TA, Voelker W. “Blind” pericardiocentesis: A comparison of different puncture directions. *Catheter Cardiovasc Interv*. 2018;92(5):E327-E332.
 40. Maisch B, Ristić AD, Seferović PM, Tsang TSM. *Interventional Pericardiology*. Pericardiocentesis, Pericardioscopy, Pericardial Biopsy, Balloon Per-

- icardiotomy and Intrapericardial Therapy. Heidelberg: Springer; 2011.
41. Hirsch HH, Scior H, Zipf KE. On longitudinal inferior pericardiotomy (Sauerbruch) as an approach to the heart for pacemaker implantation in Morgagni-Adams-Stokes Syndrome. *Brunn Beitr Klin Chir.* 1964;208:446-55.