

Mitral valve trauma in an infant during aortic valvuloplasty and its surgical treatment

Luis E. Marcano Sanz^a, MD; Juan C. Ramiro Novoa^b, MD; Gilberto Bermúdez Gutiérrez^a, MD; Francisco Díaz Ramírez^b, MD; and Katia Rivera Ladino^a✉, MD

^a Department of Cardiovascular Surgery. Cardiocentro Pediátrico "William Soler". Havana, Cuba.

^b Department of Hemodynamics. Cardiocentro Pediátrico "William Soler". Havana, Cuba.

Este artículo también está disponible en español

ARTICLE INFORMATION

Received: November 26, 2012

Accepted: January 14, 2013

Competing interests

Authors have no competing interests

On-Line versions:

Spanish - English

✉ K Rivera Ladino
Cardiocentro Pediátrico William Soler
Ave. 100 y Perla, Alta Habana
Boyeros, CP 10800
La Habana, Cuba
E-mail address:
ladinok@infomed.sld.cu

ABSTRACT

Balloon valvuloplasty is widely accepted as the treatment of choice for congenital aortic stenosis in newborns and infants. Complications from the procedure are well known but mitral valve damage is rare. This is the case of a 7-month-old male patient with the diagnosis of coarctation of the aorta and aortic valve stenosis who underwent dilation of both lesions via catheterization. At 20 hours of the procedure a severe heart failure secondary to an injury of the anterior mitral valve was diagnosed. The patient underwent emergency surgery and a slit-like tear from the free edge to the annulus was observed, which was repaired and annuloplasty in the lateral commissure was performed. In the immediate postoperative period the patient progressed without complications and at one year follow up he shows mild valve regurgitation without evidence of recoarctation or aortic valve stenosis.

Key words: Aortic valvuloplasty, Mitral valve, Heart surgery

Trauma valvular mitral en un lactante durante la valvuloplastia aórtica y su tratamiento quirúrgico

RESUMEN

La valvuloplastia con globo es ampliamente aceptada como tratamiento de elección de la estenosis aórtica congénita en recién nacidos y lactantes. Las complicaciones por el procedimiento son bien conocidas pero el daño valvular mitral es infrecuente. Se presenta un paciente masculino, de siete meses de edad, con el diagnóstico de coartación de la aorta y estenosis valvular aórtica a quién se le realizó dilatación de ambas lesiones por cateterismo intervencionista. A las 20 horas del procedimiento se diagnosticó insuficiencia cardíaca grave secundaria a lesión de la valva anterior mitral. Se intervino quirúrgicamente de urgencia y se observó un desgarro en forma de hendidura desde el borde libre hasta el anillo, el cual se reparó y se realizó anuloplastia en la comisura lateral. En el postoperatorio inmediato evolucionó sin complicaciones y al año de seguimiento presenta insuficiencia valvular mitral leve sin signos de recoarctación ni de estenosis valvular aórticas.

Palabras clave: Valvuloplastia aórtica, Válvula mitral, Cirugía cardíaca

INTRODUCTION

Aortic stenosis has an incidence of 3-6% among congenital heart diseases¹. Balloon valvuloplasty is widely accepted as the treatment of choice for this heart disease in newborns and infants due to the short hospital stay and the good results obtained with this type of intervention². However, this procedure is not without risks. Different complications including cardio-respiratory arrest, ventricular perforation, cardiac tamponade, acute aortic valve regurgitation have been described³. Mitral valve damage is very rare and occurs because of the very posterior position of the guidewire, inflation of a malpositioned balloon or by the presence of small and hypoplastic ventricles^{4,5}. The aim of this case report is to present a patient with severe heart failure, who underwent surgical repair of the mitral valve secondary to a trauma caused by the balloon of the aortic valvuloplasty.

CASE REPORT

This is the case of a 7-month-old male patient with 8 kg of body weight, with clinical and echocardiographic diagnosis of severe circumscribed coarctation of the aorta and critical aortic valve stenosis. The aortic valve was bicuspid and showed no regurgitation.

Under general anesthesia and elective endotracheal intubation a left heart catheterization via the right femoral artery was performed. A gradient of 48 mmHg at the level of the coarctation and of 77 mmHg between the left ventricle and the aorta was found. The aortic annulus measured by cineangiography was 8.5 mm. Successful manual dilation of aortic coarctation, without residual gradient, was performed as well as valvuloplasty of the aortic valve lesion with manometer at a pressure of 8 atmospheres. The residual gradient at that level was 18 mm Hg and aortic regurgitation was not found (Figure 1).

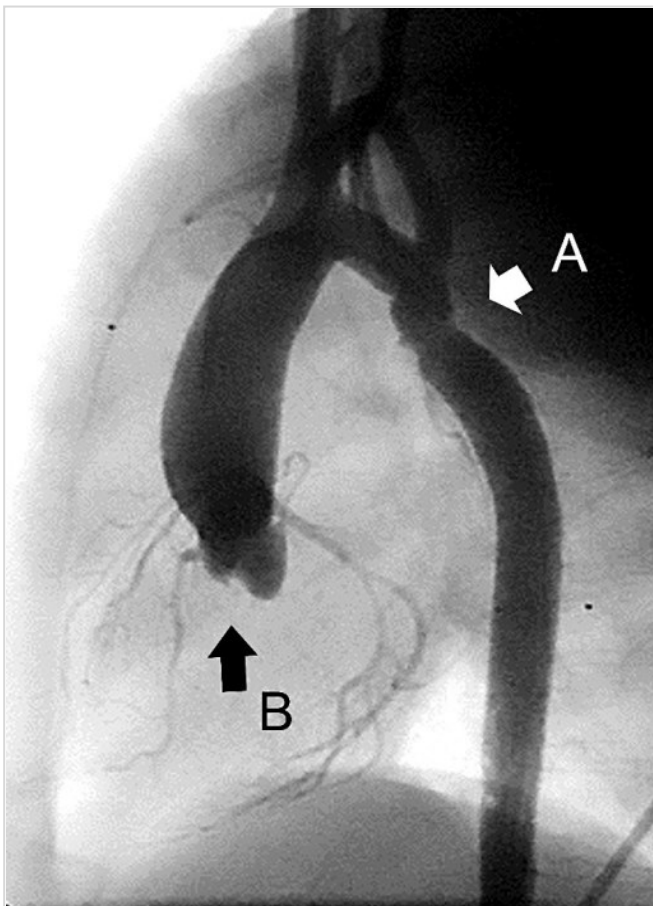


Figure 1. Cineangiography in left lateral view. A: successful dilation of aortic coarctation. B: Absence of aortic valve regurgitation.

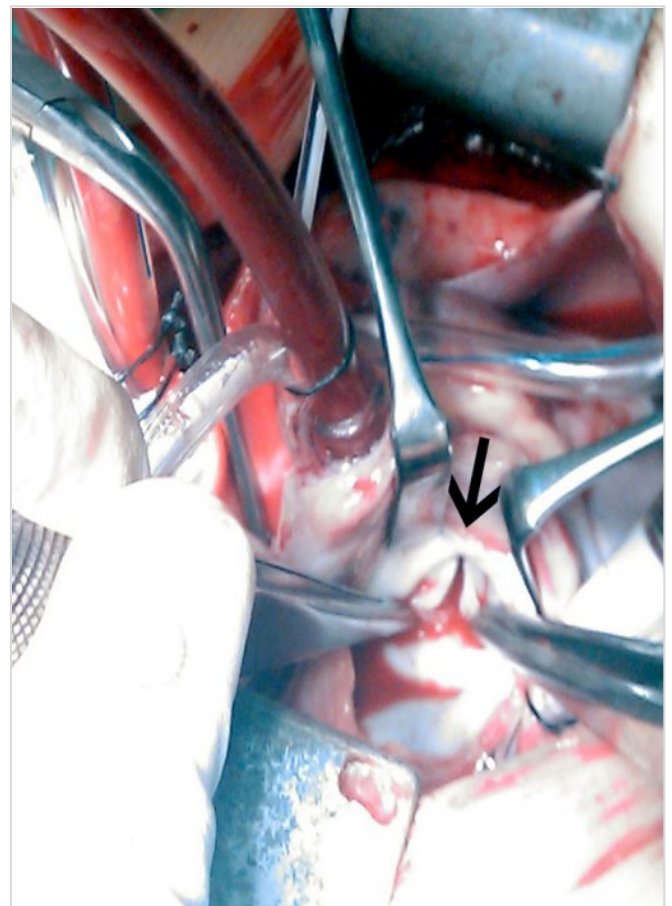


Figure 2. Surgical image. The anterior mitral leaflet, fissured in transverse direction (arrow), is accessed through the left atrium.

At 20 hours of the procedure, the patient had clinical signs of cardiogenic shock and required transfer to the Intensive Care Unit (ICU), mechanical ventilation and inotropic support. Transthoracic echocardiography showed a traumatic mitral valve lesion with tear of the anterior leaflet as well as severe and acute mitral regurgitation.

Emergency surgery was performed using cardiopulmonary bypass at normothermia, aortic clamping and cold crystalloid cardioplegia. The mitral valve was accessed through the left atrium, the slit was repaired from the free edge of the anterior leaflet to the annulus (Figure 2), with three 6/0 polypropylene stitches reinforced with autologous pericardium; annuloplasty was performed in the lateral commissure with one 5/0 polypropylene stitch. Transesophageal echocardiogram showed minimal mitral regurgitation and good biventricular systolic/diastolic function.

The postoperative course was uneventful, and the patient stayed in the ICU for two days and was discharged from hospital on the seventh day. At follow-up, echocardiography at one year from surgery showed mild mitral valve regurgitation with no signs of coarctation of the aorta or aortic valve stenosis.

COMMENT

Among the complications that may occur during aortic valvuloplasty, mitral valve injury has been reported in a few patients, and it has been related to a very posterior positioning of the guidewire into the left ventricle or the left atrium (Figure 3), although it has been suggested that this malpositioning is most likely to occur if the patient has a small ventricular cavity or abnormal mitral valve apparatus^{2,5}.

In this patient, the valve lesion occurred presumably by inflating the valvuloplasty balloon, positioned at the level of mitral valve plane. At that time, the detail that the guidewire had reached the cavity of the left atrium was overlooked, which could have alerted to the malpositioning of the catheter-balloon. Left ventricular hypertrophy, due to coarctation of the aorta and thus the smaller size of such cavity, may have favored the abnormal course of the guidewire.

The extent of the damage, which involved the mitral valve annulus, explains the earliness of symptoms. In the literature reviewed, reports about the time these injuries were diagnosed range from 10 weeks to 3 months after the procedure⁵, but the more repair surgery is delayed, the more damages are produced by

regurgitant flow in other structures of the valve apparatus such as chordae tendinae elongation and annular dilation. Hence, early valve repair in the patient presented has shown excellent results in clinical and echocardiographic follow-up one year after surgery.

The mitral valve lesion as a complication of aortic valve replacement is rare but can have serious consequences for patients. Assessing the correct position of the guidewire before using the balloon catheter is essential to avoid this complication. Early surgical repair prevents further mitral valve damage and provides excellent functional results.

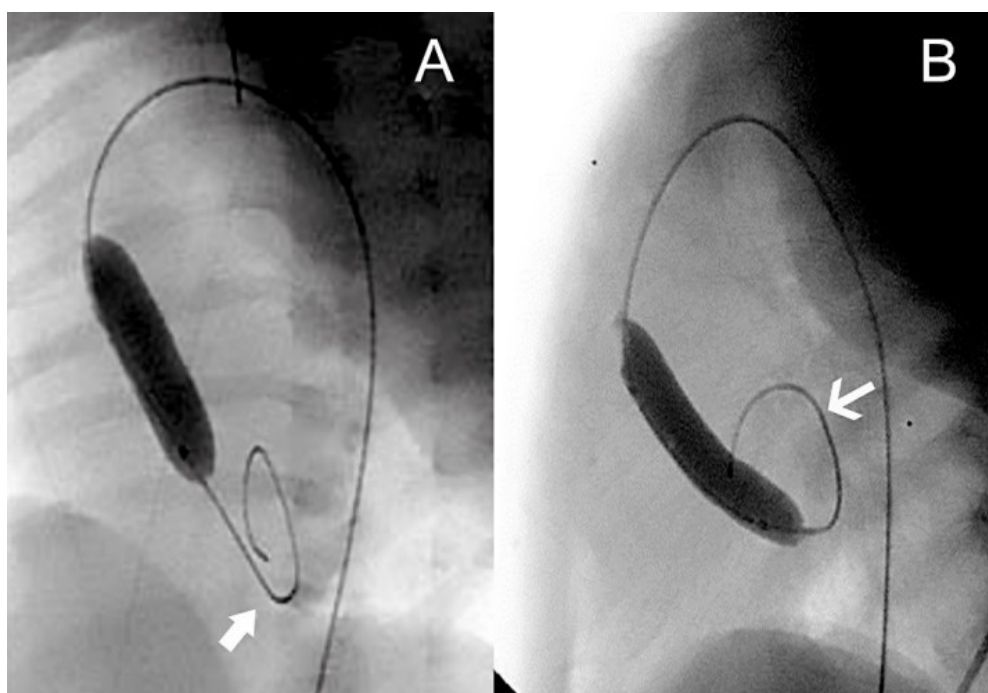


Figure 3. Cineangiography in left lateral view. A guidewire correctly placed in left ventricular cavity (arrow). B: The guidewire is observed with a very posterior pathway, whose end is in the left atrial cavity (arrow). The balloon catheter in the left ventricle is below the mitral valve plane.

REFERENCES

1. Kitchiner DJ, Jackson M, Walsh K. Incidence and prognosis of congenital aortic valve stenosis in Liverpool (1960-1990). *Br Heart J.* 1993;69(1):71-9.
2. Sarihoglu E, Erek E, Yalçınbaş YK, Öztürk N, Sarioğlu A, Sarioğlu T. Mitral valve injury during aortic ballon valvuloplasty and its surgical treatment. *Turkish J Thorac Cardiovasc Surg.* 2005; 13: 169-70.
3. Yamamoto Y, Shiraishi I, Yamagishi M, Hamaoka K. Mitral valve injury during ballon valvuloplasty for an infant with severe aortic stenosis: Spatial evaluation using three dimensional echocardiography. *Pediatr Cardiol.* 2003;24(3):300-3.
4. McCrindle BW, Blackstone EH, Williams WG, Sittiwangkul R, Spray TL, Azakie A, et al. Are outcomes of surgical versus transcatheter ballon valvotomy equivalent in neonatal critical aortic stenosis? *Circulation.* 2001;104(12 Suppl 1):152-8.
5. Brierley JJ, Reddy TD, Rigby ML, Thanopoulous V, Redington AN. Traumatic damage to the mitral valve during percutaneous valvotomy for critical aortic stenosis. *Heart.* 1998;79(2):200-2.