




## Internal mammary artery harvesting in cardiac surgery: An often mistold story

Yoandy López de la Cruz<sup>1</sup> , MD, MSc; Manuel S. Nafeh Abi-Rezk<sup>2</sup> , MD, PhD; and Julio R. Betancourt Cervantes<sup>3</sup> , MD, PhD

<sup>1</sup> Department of Cardiovascular Surgery. Hospital Provincial Universitario Cardiocentro Ernesto Che Guevara. Santa Clara, Villa Clara, Cuba.

<sup>2</sup> Department of Cardiovascular Surgery. Hospital Hermanos Ameijeiras. Havana, Cuba

<sup>3</sup> Department of Surgery. Hospital Manuel "Piti" Fajardo Rivera. Santa Clara, Villa Clara, Cuba.

*Este artículo también está disponible en español*

### ARTICLE INFORMATION

Received: July 17, 2019  
Accepted: August 22, 2019

### Competing interests

The authors declare no competing interests

### Abbreviations

LAD: left anterior descending  
ICS: intercostal space  
IMA: internal mammary artery

### ABSTRACT

The left internal mammary artery is the conduit of choice for left anterior descending coronary artery grafting. A huge body of evidence shows that the short and long-term outcomes of coronary artery bypass grafting depend on specific factors related to the preparation of the artery, namely, its blood flow and residual sternal vascularization degree. Accordingly, the internal mammary artery harvesting has received as much attention as the grafting construction technique in recent decades. However, the story of its origins and subsequent progress has not always been properly told as many inaccuracies have been passed on over the years.

**Keywords:** Coronary artery bypass graft surgery, Internal mammary artery, Dissection, Vineberg operation, History of Medicine

### *Dissección de la arteria mamaria interna en cirugía cardíaca: Una historia no siempre bien contada*

### RESUMEN

La arteria mamaria interna es el hemoducto de elección para injertar en la arteria coronaria descendente anterior. Un enorme cuerpo de evidencia demuestra que los resultados de la cirugía de revascularización miocárdica en el corto y largo plazo dependen de determinados factores relacionados con la preparación de la arteria, como su flujo y el grado de vascularización esternal residual. Por ese motivo, en las últimas décadas el procedimiento de disección de la arteria mamaria interna ha recibido tanta atención como la técnica de construcción de los injertos. Sin embargo, la historia de su origen y posterior evolución no ha sido siempre adecuadamente contada y muchas imprecisiones se han transmitido a lo largo de los años.

**Palabras clave:** Revascularización miocárdica quirúrgica, Arteria mamaria interna, Disección, Operación de Vineberg, Historia de la Medicina

### INTRODUCTION

Coronary artery bypass graft surgery is without any doubt one of the most researched and published surgical procedures in the history of medicine<sup>1,2</sup>. Countless books and articles expose, scientifically or anecdotally, the lives

✉ YLópez de la Cruz  
Ave 26 de Julio, Edificio 306 Apto. 18.  
Reperto Escambray Sur.  
Santa Clara, Villa Clara, Cuba.  
E-mail address:  
yoandylic@infomed.sld.cu

of its most important pioneers or protagonists, and tell the events that have stitched together over a century of breathtaking events. However, the history of the internal mammary artery (IMA) harvesting procedures is still waiting to be properly written. Plagued by inaccuracies are many works that have sown more doubts and ignorance about the historical evolution of the simple, but essential technique, on whose success may depend the addition of many years of life to patients suffering from coronary artery disease. This brief review has been written in the humble hope of shedding some light; we also wish to serve as a simple tribute to the 70 years that are commemorated in this 2020, of an event that marked a milestone in the long struggle of man against heart disease: the first surgery to implant an IMA in a human heart.

### Background of a revolutionary technique


In 1927, inspired in a lecture by Professor Horst Oertel at McGill University in Montreal, Canada, on how coronary artery disease primarily affected the superficial epicardial vessels, medical student Arthur Martin Vineberg considered the possibility of using another artery to implant it within the heart muscle, thus, that its branches could gather undamaged intramyocardial arterioles. Then, he considered the IMA as the most viable graft due to its proximity to the left ventricle and the possibility of removing it without significant consequences for its surrounding tissues<sup>3</sup>. In the following 18 years, different events, both family and scientific, created the conditions so that in November 1945, the surgeon Vineberg (**Figure 1**) began his experiments, consisting in tunneling the artery in canine myocardia until he could demonstrate the existence of the theorized anastomoses<sup>4,5</sup>, which occurred in dog 8A, operated on February 8, 1946 and killed 99 days later<sup>6-8</sup>. Unfortunately, in his first publications, he did not sufficiently detail the technique used to separate the IMA from the thoracic wall and only reported that it was a partial removal. Nevertheless, in the photomicrographs accompanying his articles, only the light of a grafted vessel in the myocardium was observed, which allows the presumption that only the arterial graft was dissected, probably between the 4th and 6th intercostal space (ICS), through a thoracotomy.

On the other hand, at the same time that Vineberg carried out his experiments, at the Johns Hopkins Hospital in Maryland, United States (USA), William Polk Longmire Jr. became, perhaps, the first

surgeon in history to dissect a small pedicled segment of human mammary vessels to use their blood flow and venous drainage in other organs, in this case, for irrigating –in the thoracic cavity– a portion of the jejunal loop used for esophageal reconstruction<sup>9-15</sup>.

### The first harvesting of (a segment of) IMA in human cardiac surgery

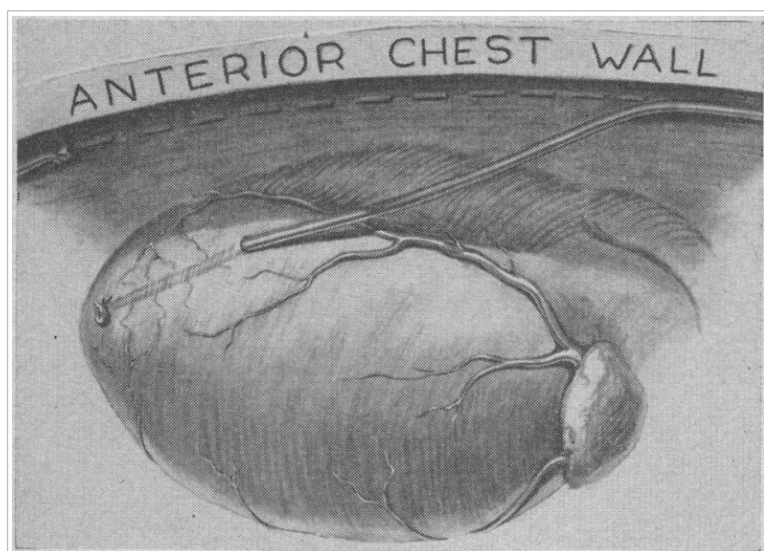
On April 28, 1950, the modern era of coronary artery bypass graft surgery procedures probably began. A patient suffering from angina, for 14 years, had been admitted four days earlier to the Royal Victoria Hospital in Montreal, to undergo a practically experimental surgery. After almost five years of experiments in dogs, Vineberg decided that the time had come to implement his novel procedure in humans. Mr. J.P, a 53-years-old tailor, was operated by left anterolateral thoracotomy in the 5th ICS with a 10 cm resection of the 4th and 5th ribs, near the sternum. Regarding the IMA harvesting, the Canadian surgeon only pointed out in his article<sup>16</sup> that it was released from the thoracic wall between the 4th and 6th ICS, with ligatures of the 4th and 5th intercostal arteries.



**Figure 1.** Arthur M. Vineberg (1903-1988). Inventor of the “mammary implant”, also known as Vineberg operation. Taken from Zalaquett R. *Rev Chil Cardiol.* 2017;36:162-9<sup>5</sup> (License CC BY-NC-ND 4.0).

Probably the few data related to IMA preparation that Vineberg provided in most of his articles, or the misguided practice of some researchers to transmit information without adequately corroborating the original sources, has caused unfortunate errors when trying to tell the story of that procedure. Some authors have indicated that he carried out the IMA harvesting in a pedicled way<sup>17,18</sup>; also, it has been commented that he did not specify his harvesting method in any of his articles,<sup>19</sup> and others have stated that he began to skeletonize the artery as late as in 1964<sup>20</sup>. All of these claims are wrong. First, it should be noted that in the early 1950s the terms “skeletonized” or “pedicled” dissection had not yet been coined; therefore, whoever tries to find this characteristic literally in the works where Vineberg describes his technique, will be wasting time. Nonetheless, in the first articles where he commented his clinical practice, he always pointed out that he only released the artery—initially a segment of a few centimeters—and in the publications dated 1951 and 1954, he again showed photomicrographs, where only the light of an arterial vessel is seen in the preparations of deceased patients; this last publication is accompanied by a drawing (reproduced with other details in 1958 and 1961<sup>21,22</sup>), where clearly, only the IMA implanted in the wall of the left ventricle is observed (**Figure 2**)<sup>16,21</sup>.

Certainly, in none of those early Vineberg works,



**Figure 2.** Drawing showing internal mammary artery detached from chest wall and buried in myocardial tunnel made in left ventricle. Taken from Vineberg A. *Can Med Assoc J.* 1958; 78:871-9<sup>21</sup>, with permission from the Canadian Medical Association Journal.

there is a reference to the fate of the mammary vein. It may be speculated that not needing it for the success of his procedure, he left it intact in the thoracic wall (which is why he did not consider important to mention it) or, on the other hand, it could be thought that he separated the artery along with its vein, which he later discarded, but this last possibility seems improbable because, for ethical reasons, being an almost experimental technique, surely he would have been careful to mention that detail, in anticipation of the possible and unknown consequences of eliminating that venous drainage. So far, the circumstances point, with little doubt, to the fact that Vineberg harvested the segment of the mammary artery in a skeletonized way, but the final confirmation was yet to come.

#### First IMA harvesting for its direct anastomosis to a coronary artery

As already mentioned, for most of the 1940s, Bill Longmire worked at the Hopkins. There he was eventually considered by his Professor Alfred Blalock to be a “specialist in difficult surgeries”<sup>24</sup>. From that stage of his life, it should not be forgotten that, on November 29, 1944, he was the first assistant in the operation in which, for the first time, an anastomosis was successfully performed between the pulmonary and subclavian arteries (Blalock-Taussig procedure) in a 15-month-old girl diagnosed with tetralogy of Fallot<sup>25</sup>. However, ten years later, Longmire was the brand-new Chief of Surgery at the Medical Center of the University of California (Los Angeles, USA), and had passed through virtually every branch of that specialty. Furthermore, throughout the 1950s, he had boldly dabbled in heart valve surgery and, in 1958, he felt that the time had come to leave his mark on the surgical treatment for coronary artery failure.

Two years earlier, Charles Bailey had performed the first closed endarterectomy using a blind technique, but Longmire considered it best to perform the procedure with cardiopulmonary bypass, with the longitudinal opening of the vessel, directly on its diseased segment<sup>24</sup>. Thus, probably on March 17, 1958 (date never published before<sup>26</sup>), while performing his method, a highly calcified right coronary artery was destroyed in his hands and, in

a desperate attempt to save his patient's life, he decided to dissect the ipsilateral IMA and anastomosing it to the cardiac vessel<sup>27,31</sup>. That was the first time in history that an extracardiac artery was directly connected to a coronary artery, for increasing blood flow to an ischemic myocardium, but Longmire apparently considered the procedure too daring for its time and never reported those details of the surgery<sup>24</sup>. For this reason, the characteristics of the IMA harvesting procedure used will never be known exactly; the authors of this article venture to theorize that only a proximal segment of the artery was prepared, given that the patients underwent surgery through an anterior bilateral thoracotomy, and that, the majority of the lesions that were then addressed were located in the first coronary segment<sup>32</sup>. Because Longmire had dissected the two mammary vessels in 1946, and knew that they were not necessary in the thorax, he was able to choose to separate the pedicle to save time, but being a very practical and skilled surgeon, he probably only separated the artery by needing just its flow; it is hard to guess.

### Birth of pedicled harvesting technique

Until the early 1960s, all of the mammary artery segments implanted around the world were dissected as described by Vineberg. However, some groups continued to conduct experimental studies in the belief that the Canadian's technique could be improved. Around 1954, William Horace Sewell, a surgeon at a Veterans Administration Hospital in Oteen (North Carolina, USA), had begun his research to better understand the physiological factors that controlled the development of collateral channels to the coronary arteries<sup>33</sup>. Five years later<sup>34</sup> he was in a position to experimentally propose a new way of preparing the IMA, on the grounds that a deficiency of the Vineberg's procedure was the absence of a venous vessel which could accompany the artery, drain excess blood into the postoperative period and could avoid the formation of hematomas in the myocardium<sup>35,36</sup>.

It has been impossible to pinpoint the date when this procedure designated as "pedicle operation"<sup>36</sup> was first performed on humans, despite the fact that almost all of Sewell's articles, published during those years and later digitized, were reviewed. Nevertheless, evidence has been found that the fourth patient who underwent this surgery was operated on January 28, 1963. In essence, the technique was similar to that currently used during the pedicled IMA harvest-

ing, with the only differences that it was performed through an anterolateral thoracotomy and probably, only the vessels between 2° and 6° ICS were separated, although the detail is not explicit<sup>33</sup>. It is difficult to determine whether it was in late 1962 or during January 1963 that the IMA pedicled harvesting was first performed; it will probably never be known with complete accuracy, but as previously mentioned, Sewell's need of modifying the Vineberg's procedure became the final confirmation that the Canadian only dissected the left IMA.

### 1960s: Pedicled or skeletonized harvesting?

By 1965, René Gerónimo Favalaro (**Figure 3**), from the group of the Cleveland Clinic (Ohio, USA), and probably with him many other surgeons, had realized that the IMA harvesting, together with its veins and surrounding tissue, was a faster procedure and, at least in theory, less traumatic for the graft<sup>5,37</sup>. Nonetheless, during the rest of that decade, the mammary arteries were implanted skeletonized or pedicled, according to the preference of surgeons, since Vineberg's work eventually showed that hematomas never occurred in the myocardium of his patients<sup>38</sup>, hence, the alleged advantage of venous drainage in the artery pedicle, as Sewell argued, was unfounded.

In turn, on January 31, 1966, the Canadian performed the first right IMA implantation in the ipsilateral ventricular myocardium in a 43-year-old New Yorker. This was probably the first IMA harvesting through a median longitudinal sternotomy; he had to choose this approach because the patient had undergone a thoracotomy in the left parasternal region two years before, due to an accidental wound with a knife, which was perhaps the cause of the subsequent stenosis of her right coronary artery. In this case, also, possibly for the first time, the IMA was dissected in its entire length, between the 1st and 6th ICS, since the anatomical relationships between the ventricle and the left conduit had not required, up to this time, an extensive preparation of the artery. Interestingly, in that surgery, the implantation of the two mammary arteries was planned, but the left one turned out to be very small and with little flow, due to an inadvertent injury to the artery in one of the previous incisions. Finally, a month later, on March 3, 1966, Vineberg achieved the implantation, for the first time, of both mammary arteries in the heart of a 48-year-old cook<sup>38</sup>.

Also during 1966, Favalaro performed intramyocardial implants of one and both mammary arteries,



**Figure 3.** René Favaloro (left) and Mason Sones (right). Photo taken at the Hemodynamics Laboratory of the Cleveland Clinic. Obtained from Zalaquett R. *Rev Chil Cardiol.* 2017;36:162-95 (License CC BY-NC-ND 4.0).

always using the Sewell's technique. It was probably the Argentinian who first, in that same year<sup>37,39</sup>, created a sternal retractor specially designed to prepare the IMA<sup>40</sup>; which, with few modifications, is still in use nowadays. In May of the following year, he performed his first reconstruction of a right coronary artery with an intervening segment of the saphenous vein, but aware of the limitations of this technique, he promptly decided to connect one end of the vein to the anterolateral wall of the aorta. By December 1968, the Ohio group had successfully operated 171 patients with this method<sup>37,39</sup>, and a period began in which mammary implantations commenced to decrease and aorto-coronary connection surgeries with vein grafts began to increase. Until the beginning of the next decade, there are few reports of revascularization with the IMA.

### 1970s: Direct coronary artery bypass grafting

During the first years of the 1970s, surgeons abandoned mammary implantation and adhered to direct coronary artery bypass grafting. The most common grafts were the internal saphenous vein and the IMA. In 1971, George E. Green introduced papaverine into the practice of coronary artery surgery<sup>41</sup>, recommending its injection within the IMA<sup>42</sup>. It was an important moment in the historical evolution of internal mammary harvesting because it was the begin-

ning of the era of surgeons' efforts to overcome, with drugs, the spasm of arterial grafts<sup>43</sup>, which on many occasions, makes it impossible or hinders their use.

The following year, in the month of January, David L. Galbut's group from the Heart Institute of Miami, USA, began to harvest all the IMA in a skeletonized form in an extensive series of revascularized patients<sup>44</sup>. Everything seems to indicate that in the era of direct coronary approach, these surgeons were the first to develop mammary skeletonization as a habitual practice in their patients, over a long period of time<sup>45</sup>. Conversely, few authors acknowledge this achievement to the Florida physicians, probably because it took 13 years to publish the first results of their work, or because it took until 2012 to include the term "skeletonization" in the description of their technique<sup>46</sup>. Until then, they limited themselves to pointing out that the artery was not mobilized as a

pedicle; instead, it was isolated from its lymphatics and endothoracic fascia, and the mammary vein divided near the subclavian vein and separated from the IMA<sup>44</sup>.

Moreover, this series was also one of the first with patients revascularized with both mammary arteries, started at least two years before the first relationships between this technique and the complications of the sternal wound were established<sup>47</sup>. Therefore, although Galbut does not specify the reasons why his group began to dissect the mammary in a skeletonized way, it seems that it was not related to better sternal protection. Their articles do not allow to specify whether the skeletonization was used from the very beginning of the series. Probably, in the first cases, the harvesting was pedicled, but the need to construct sequential anastomoses and the possibility of accurately inspecting the graft while preparing it, led them to skeletonize the artery, in a similar way as it was still done in the Vineberg operation<sup>48</sup>. This hypothesis seems to be confirmed in the group's publication in 1990<sup>45</sup>, where they noted that: "although the risk of injury to the IMA during its mobilization may be greater (...) this method allows the visualization of the entire graft to ensure that no damage or intramural hematoma has occurred (...) and it provides superior length".

Thanks to the work of Galbut, Suzuki, Barner and others, in the mid-1970s the IMA acquired a certain

prominence in cardiac surgery's operating rooms<sup>44</sup>.<sup>49</sup> By 1975, most surgeons had once again adopted its use as a graft to revascularize the stenotic coronaries<sup>50</sup>, and it became the bridge of choice for the left anterior descending (LAD) artery<sup>51</sup>.

During that time, the pedicled dissection was, without doubt, the most widely used technique, but its "relationship" with the skeletonized must be ultimately clarify. In recent years, some authors<sup>52-54</sup> have suggested that the skeletonization of the IMA is a recent technique, which emerged as a strategy to limit the degree of sternal devascularization during pedicled dissection of the arterial conduit graft, through the intentional preservation of arterial collateral branches and venous drainage from the thoracic wall. However, Vineberg's early practice and the start of Galbut's extensive series, before the first links between sternotomy complications and use of the two mammary arteries were reported, demonstrate that this was not the true historical relationship of these surgical techniques.

### 1980s: Longer mammary arteries are needed

According to Hicks<sup>55</sup>, in the early 1980s, the selection of blood vessel grafts in coronary artery surgery depended on the availability of the saphenous vein and the experience of the surgeon in mammary harvesting. Those first years witnessed an increase in interest in performing a greater number of arterial grafts, but this desire was opposed by the shorter length and lateral pedicle of the IMA in the way it was usually prepared. For this reason, in 1985, Delos M. Cosgrove and Floyd D. Loop<sup>56</sup>, of the Ohio group, proposed a technique to maximize the length of the artery previously dissected as a pedicle, by making multiple cross sections in its pleura and fascia, thus achieving an additional length of 1 cm for each performed fasciotomy.

Two years later, Samuel B. Keeley, at Scripps Memorial Hospital (California, USA), suggested separating the IMA from its bed in the traditional way and then stripping the mid-distal segment of its pedicle, with the help of a bipolar electrocautery. He entitled his work as "The skeletonized internal mammary artery"<sup>57</sup>, and by quoting this term –"skeletonized"– in the body of his article, it gave rise to one of the most reproduced inaccuracies in the history of cardiac surgery, since in the following three decades a large number of authors<sup>53,58-67</sup> have wrongly considered that Keeley was the father of the IMA skeletonization technique. As it has already been shown,

this recognition to the American surgeon is undeserved, and he cannot even be credited for having coined the term "skeletonization" in relation to the IMA, since a year earlier, Lester R. Sauvage and his group (Seattle, USA) had already done it in one of their articles<sup>68</sup>, but neither can the creation of the method be attributed to these, as other authors have claimed<sup>69</sup>.

Before finalizing the balance of this decade, it cannot be ignored that on November 1, 1988, James M. Cunningham and his collaborators, from the California Center for Cardiothoracic Surgery, began a series that, in the end, would consist of more than a thousand patients, whose analysis would culminate three years later. The significance of this study is that it resulted in a simple article in 1992, where they exposed their main considerations concerning the skeletonization of the IMA, and for the first time, the procedure is explained in detail, as it is currently done<sup>70</sup>, which has earned some authors to consider it the description of the "classic technique" or –erroneously– the true start of skeletonized dissection of the IMA<sup>67,71</sup>. In the operation, equal attention was paid to the protection of the sternum and the vessel graft, the mammary vein was cut if it interfered with the proximal dissection of the artery and they tried not to open the pleura. Apparently, at the time, Cunningham did not assess the true value of his article and he would admit years later, that he had only written it in the hope of decreasing the learning curve of the procedure and avoiding unnecessary technical setbacks<sup>72</sup>.

### 1990s: End of story?

The recent history of the development of classical IMA harvesting techniques probably ends in 1997, when Taiko Horii and Hisayoshi Suma<sup>73</sup>, at the Shonan Kamakura General Hospital, in Japan, described a method, which combines the advantages of skeletonization and pedicled dissection, which was called semi-skeletonization<sup>73,74</sup>. After this innovation, the three IMA preparation methods have not undergone major changes, except for those related to the introduction of technological advances, such as thoracoscopic or robotic dissection in the late 1990s<sup>75-83</sup>, as well as the harmonic technology in the year 2000<sup>84</sup>.

### Internal mammary artery harvesting in Cuba

The history of coronary artery surgery in Cuba is waiting to be written, thus, trying to sketch the evo-



**Figure 4.** Some pioneers of cardiovascular surgery in Cuba. From left to right: professor Julio Taín Blázquez, nurse Oralia González Castillero, professor Noel González Jiménez, nurse Amparo González Giménez, professor Gilberto Gil Ramos and professor Felipe Rodiles Aldana. Taken from: Bejerano Gil, *et al.* Rev Cuban Med Int Emerg. 2018;17(3)<sup>86</sup> (License CC BY-NC-ND 4.0).

lution of IMA harvesting procedures is a task that borders on the impossible.

Presumably, the first surgical procedure on a cardiac vessel in Cuba was performed in 1974, at the *Instituto de Cardiología y Cirugía Cardiovascular*, in Havana; when, during an aortic valve replacement surgery, an aneurysmal right coronary artery was grafted. In the same center, the following year, the first coronary artery bypass graft surgery also took place on the island<sup>85</sup>.


Unfortunately, we have not been able to access the original reports of these interventions, but we can affirm that the grafts were venous and probably performed by Dr. Julio Noel González Jiménez (Santo Domingo, Las Villas; December 2, 1928 – Havana; January 17, 2016) and Dr. Julio Taín Blázquez (Colón, Matanzas; December 20, 1930 – Havana, May 4, 2019) (**Figure 4**<sup>86</sup>).

In 1986, this type of intervention began at the Hospital Hermanos Ameijeiras<sup>87</sup>. Two years later, exactly on March 9, 1988 (**Figure 5**), doctors Mauricio Alberto Cassinelli Arana (Montevideo, Uruguay; December 17, 1953) and Álvaro Luis Lagomasino Hidalgo (Havana; December 15, 1947) (**Figure 6**) performed the first coronary artery bypass graft surgery in another province outside the country's capital (**Figure 7**): at the Cardiocentro Ernesto Che Guevara of Santa Clara city<sup>88</sup>, to a 48-year-old patient with LAD artery disease, who received pedicled left IMA graft<sup>89</sup>. Probably before, in Havana, an IMA had been

dissected for the first time in Cuba, but we have not been able to identify that date. A year later, it would correspond to initiate this type of surgery to the Cardiocentro of Santiago de Cuba<sup>90,91</sup>.

Undoubtedly, the saphenous vein was the most frequently used conduit during the first years of coronary artery surgery in Cuba<sup>87,90</sup>; it is difficult to pinpoint exactly when the IMA became the graft of choice for routine LAD revascularization. In the center of the island, as a result of the tense economic situation of the 1990s, due to the lack, above all, of specific instruments to manipulate the IMA and of the sternal retractor to dissect it, arterial grafts to the LAD were stopped during approximately two years (personal communication, Dr. Álvaro Lagomasino Hidalgo). Finally, from May 1992, this practice was restarted, and a period of time ensued, in which the construction of multiple arterial grafts became frequent<sup>92</sup>.

In the *Hospital Hermanos Ameijeiras*, the skeletonized harvesting of the IMA probably started around 2006<sup>93</sup>; the date in Santiago de Cuba has not been specified. In Santa Clara, until 2012, if any skeletonized dissection of the IMA was performed, it occurred anecdotally; in January of that year, the abandoned practice of constructing multiple arterial grafts was regularly resumed<sup>94</sup>, and the IMA of these patients began to be systematically skeletonized. In



**Figure 5.** Graphic proof of the date and signature of the participants in the first coronary artery surgery performed "to the east of the tunnel" (outside Havana). Archive from Cardiocentro Ernesto Che Guevara.

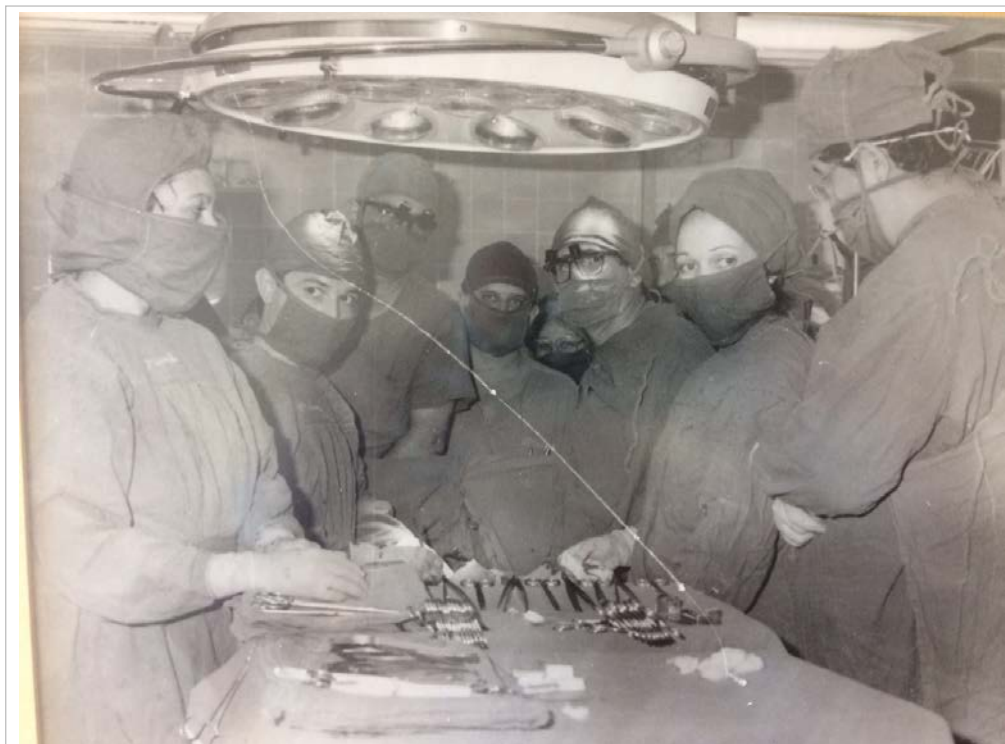

**Figura 6.** Doctors Mauricio A. Cassinelli Arana (left) and Álvaro L. Lagomasino Hidalgo. Courtesy of Dr. Cassinelli.

this center, in recent years there has been a sustained growth of revascularizations with the two mammary arteries, which has become an important stimulus for the rise of the skeletonized dissection technique; at the time of writing this article, almost all of the mammary arteries are prepared in this way. On the other hand, in the absence of works that specifically address this topic, personal communications from colleagues in Havana and Santiago de Cuba, allow the authors of this article to assert that, contrary to what happens in the world, where pedicled dissection is preferred by 65% of surgeons<sup>95</sup>, currently most of the mammary arteries in Cuba are skeletonized.

### ACKNOWLEDGEMENTS

We acknowledge the collaboration in the search for information of: Raúl Dueñas Fernández (Former General Director of Cardiocentro Ernesto Che Guevara),



**Figure 7.** First coronary artery bypass graft surgery performed at the Cardiocentro Ernesto Che Guevara of Santa Clara. Photograph taken in the operating room, just before starting the operation. From left to right (foreground): Zenaida Hurtado Pacheco (nurse), Mauricio Cassinelli Arana (surgeon), Arturo Iturralde Espinosa (surgeon), Ignacio Fajardo Egozcué (anesthesiologist), Álvaro Lagomasino Hidalgo (surgeon), María Caridad Marín Lugo (nurse) and Raúl Dueñas Fernández (surgeon). Background: Valeria Magalis Espinosa (nurse) and José Cirilo Mesa Hurtado (anesthesiologist). Archive of Cardiocentro Ernesto Che Guevara.



Mauricio Cassinelli Arana (Cardiovascular Surgeon), Álvaro Lagomasino Hidalgo (Cardiovascular Surgeon), Humberto Sainz Cabrera (Cardiovascular Anesthesiologist), Eduardo Rivas Estany (President of the Cuban Society of Cardiology), Lázara González Pérez (Nurse) and Francisco Luis Moreno Martínez (Editor-in-Chief of CorSalud).

## REFERENCES

1. Leonard JR, Abouarab AA, Taggart DP, Gaudino MFL. Bilateral internal thoracic artery use in coronary bypass surgery: is there a benefit? *Indian J Thorac Cardiovasc Surg.* 2018;34:230-3.
2. Dar MI, Dar AH, Ahmed M, Haseeb A, Bilal M. Internal mammary artery flow in different racial groups of Pakistan. *J Pak Med Assoc.* 2017;67(10):1558-61.
3. Katrapati P, George JC. Vineberg Operation: A Review of the Birth and Impact of This Surgical Technique. *Ann Thorac Surg.* 2008;86(5):1713-6.
4. Vineberg A. Experimental background of myocardial revascularization by internal mammary artery implantation and supplementary technics, with its clinical application in 125 patients: A review and critical appraisal. *Ann Surg.* 1964;159(2):185-207.
5. Zalaquett R. 50 Años de Cirugía de Bypass Coronario: Meditar el pasado, enfrentar el presente y forjar el futuro. *Rev Chil Cardiol.* 2017;36(2):162-9.
6. Vineberg AM. Development of an anastomosis between the coronary vessels and a transplanted internal mammary artery. *Can Med Assoc J.* 1946;55(2):117-9.
7. Vineberg AM, Jewett BL. Development of an anastomosis between the coronary vessels and a transplanted internal mammary artery. *Can Med Assoc J.* 1947;56(6):609-14.
8. López-De la Cruz Y. La primera fotografía a color en un artículo científico: ¿El corazón del perro que cambió la historia de la medicina? *CorSalud* [Internet]. 2019 [cited 10 Jul 2019];11(3):241-2. Available at: <http://www.revcorsalud.sld.cu/index.php/cors/article/view/491/917>
9. Longmire WP Jr. A modification of the Roux technique for antethoracic esophageal reconstruction. *Surgery.* 1947;22(1):94-100.
10. Blalock A. The use of shunt or by-pass operations in the treatment of certain circulatory disorders, including portal hypertension and pulmonic stenosis. *Ann Surg.* 1947;125(2):129-41.
11. Kesler KA, Pillai ST, Birdas TJ, Rieger KM, Okerke IC, Ceppa D, *et al.* "Supercharged" isoperistaltic colon interposition for long-segment esophageal reconstruction. *Ann Thorac Surg.* 2013;95(4):1162-8; Discussion 1168-9.
12. Bakshi A, Sugarbaker DJ, Burt BM. Alternative conduits for esophageal replacement. *Ann Cardiothorac Surg.* 2017;6(2):137-43.
13. Chaikhouni A. Jejuno-esophageal interposition graft as a salvage procedure, Report of two cases. *Int J Cardiovasc Thorac Surg.* 2016;2(2):9-11.
14. Zhang Z, Guo Y, Liang C, Feng H, Liu D. Free jejunum interposition as salvage surgery after cervical esophagus injury. *J Thorac Dis.* 2016;8(7):E513-6.
15. Watanabe M, Mine S, Nishida K, Kuroguchi T, Okamura A, Imamura Y. Reconstruction after esophagectomy for esophageal cancer patients with a history of gastrectomy. *Gen Thorac Cardiovasc Surg.* 2016;64(8):457-63.
16. Vineberg A, Miller G. Internal mammary coronary anastomosis in the surgical treatment of coronary artery insufficiency. *Can Med Assoc J.* 1951;64(3):204-10.
17. Lobo Filho JG, de Azevedo Leitão MC, Lobo Filho HG, Albuquerque da Silva A, Aquino Machado JJ. Vineberg Procedure by "Vineberg technique modified by Lobo Filho": morbidity and mortality in the immediate post operative period, angiography results and flow analyze of the left internal thoracic artery implanted. *Rev Bras Cir Cardiovasc.* 2003;18(1):15-22.
18. Bernal-Aragón R, Sáenz-Rodríguez R, Orozco-Hernández E, Guzmán-Delgado N, Aragón-Manjarrez R, Hernández-Alvídrez A. Experiencia de la endarterectomía coronaria en cirugía de revascularización miocárdica. *Cir Ciruj.* 2015;83(4):273-8.
19. Kieser TM, Rose MS, Aluthman U, Narine K. Quicker yet safe: skeletonization of 1640 internal mammary arteries with harmonic technology in 965 patients. *Eur J Cardiothorac Surg.* 2014;45(5):e142-50.
20. Calafiore AM, Vitolla G, Iaco AL, Fino C, Di Giammarco G, Marchesani F, *et al.* Bilateral internal mammary artery grafting: midterm results of pedicled versus skeletonized conduits. *Ann Thorac Surg.* 1999;67(6):1637-42.
21. Vineberg A. Coronary vascular anastomoses by internal mammary artery implantation. *Can Med Assoc J.* 1958;78(11):871-9.

22. Vineberg AM, Becerra A, Chari RS. The influence of the Vineberg sponge operation upon the hydrostatics of the myocardial circulation in health and disease: evidence of luminal ventricular circulation in the beating heart. *Can Med Assoc J.* 1961;85(20):1075-90.
23. Vineberg A. Internal mammary artery implant in the treatment of angina pectoris: A three year follow up. *Can Med Assoc J.* 1954;70(4):367-78.
24. López de la Cruz Y. William Polk Longmire Jr. y los primeros 60 años de la cirugía de puentes aorto-coronarios. *CorSalud* [Internet]. 2018 [cited 10 Jul 2019];10(2):158-63. Available at: <http://www.revcorsalud.sld.cu/index.php/cors/article/view/338/691>
25. Lowenstein E, Reves JG. A History of Cardiac Anesthesiology. In: Eger II EI, Saidman LJ, Westhorpe RN, editores. *The Wondrous Story of Anesthesia.* New York: Springer; 2014. p. 829-46.
26. López-de la Cruz Y, Quintero Fleites YF. Do not forget other fathers of coronary artery bypass grafting! *J Thorac Cardiovasc Surg* [Internet]. 2020 [cited 12 Jul 2019];159(1):e65. Available at: <https://doi.org/10.1016/j.jtcvs.2019.06.093>
27. Lawton JS. Lessons Learned Regarding Myocardial Revascularization Remain True 50 Years Later: 50th Anniversary Perspective on Diethrich EB, Morris JD, Liddicoat JE, Wessinger JB. Myocardial Revascularization. Evaluation of Autogenous Vein Grafts Between Aorta and Myocardium. *Ann Thorac Surg* 1965;1:671-82. *Ann Thorac Surg.* 2015 Jun;99(6):1872-4.
28. Al-Atassi T, Toeg HD, Chan V, Ruel M. Coronary Artery Bypass Grafting En: Sellke FW, del Nido PJ, Swanson SJ, editores. *Sabiston & Spencer: Surgery of the Chest.* 9<sup>a</sup> ed. Philadelphia: Elsevier; 2016. p. 1551-88.
29. Monteith S, Goren O, Sampath R, Lehr E, Patel A, Choi PJ, *et al.* Internal thoracic artery to middle cerebral artery bypass surgery: Cadaveric Feasibility Study. *World Neurosurg* [Internet]. 2018 [cited 12 Jul 2019];112:e298-e301. <https://doi.org/10.1016/j.wneu.2018.01.040>
30. Benetti F. The History of OPCAB. *JSM Cardiothorac Surg* [Internet]. 2017 [cited 12 Jul 2019];2(2): 1013. Available at: <https://www.jscimedcentral.com/CardiothoracicSurgery/cardiothoracicsurgery-2-1013.pdf>
31. Benetti F, Scialacomo N. The evolution of minimally invasive coronary surgery. *Clin Surg* [Internet]. 2018 [cited 12 Jul 2019];3:1954. Available at: [http://www.clinicsinsurgery.com/pdfs\\_folder/cis-v3-id1954.pdf](http://www.clinicsinsurgery.com/pdfs_folder/cis-v3-id1954.pdf)
32. Longmire WP, Cannon JA, Kattus AA. Direct-vision coronary endarterectomy for angina pectoris. *N Engl J Med.* 1958;259(21):993-9.
33. Sewell WH, Sones FM, Fish RG, Joyner JT, Effler DB. The pedicle operation for coronary insufficiency: Technique and preliminary result. *J Thorac Cardiovasc Surg.* 1965;49:317-29.
34. Sewell WH. The surgical treatment of coronary artery disease. *Am Surg.* 1959;25:560-6.
35. Ellis PR, Del Rosario VC. Internal mammary implantation: A comparison of the Vineberg and Sewell Operation in dogs. *Ann Thorac Surg.* 1966;2(6):862-7.
36. Sewell WH. Results of 12 mammary pedicle implantations for angina pectoris. *Ann Thorac Surg.* 1966;2(1):17-30.
37. Favaloro RG. Landmarks in the development of coronary artery bypass surgery. *Circulation.* 1998; 98(5):466-78.
38. Vineberg AM, Zamora BO. Right internal mammary artery implantation into right ventricular myocardium for revascularization of the entire heart: experimental data and preliminary report. *Can Med Assoc J.* 1966;95(11):570-5.
39. Favaloro RG. Critical analysis of coronary artery bypass graft surgery: a 30-year journey. *J Am Coll Cardiol.* 1998;31(4 Suppl B):1-63.
40. Bakaeen FG, Blackstone EH, Pettersson GB, Gillinov AM, Svensson LG. The father of coronary artery bypass grafting: René Favaloro and the 50th anniversary of coronary artery bypass grafting. *J Thorac Cardiovasc Surg.* 2018;155(6):2324-8.
41. Ray Mohapatra CK, Mishra P, Saxena P, Raut C, Khandekar J, Ammannaya GK, *et al.* Use of nitroglycerin and verapamil solution by organ bath technique in preparation of left internal thoracic artery for coronary artery bypass surgery. *Indian Heart J.* 2017;69(6):772-6.
42. Tabel Y, Hepağuşlar H, Erdal C, Catalyürek H, Acikel U, Elar Z, *et al.* Diltiazem provides higher internal mammary artery flow than nitroglycerin during coronary artery bypass grafting surgery. *Eur J Cardiothorac Surg.* 2004;25(4):553-9.
43. Tarhan A, Kehlibar T, Yapici F, Yilmaz M, Arslan Y, Yapici N, *et al.* Role of physiological state 'normothermia' in internal thoracic artery spasm after harvesting. *Eur J Cardiothorac Surg.* 2006; 30(5):749-52.
44. Galbut DL, Traad EA, Dorman MJ, DeWitt PL, Larsen PB, Weinstein D, *et al.* Twelve-year experi-

- ence with bilateral internal mammary artery grafts. *Ann Thorac Surg*. 1985;40(3):264-70.
45. Galbut DL, Traad EA, Dorman MJ, DeWitt PL, Larsen PB, Kurlansky PA, *et al*. Seventeen-year experience with bilateral internal mammary artery grafts. *Ann Thorac Surg*. 1990;49(2):195-201.
46. Galbut DL, Kurlansky PA, Traad EA, Dorman MJ, Zucker M, Ebra G. Bilateral internal thoracic artery grafting improves long-term survival in patients with reduced ejection fraction: a propensity-matched study with 30-year follow-up. *J Thorac Cardiovasc Surg*. 2012;143(4):844-53.
47. Barner HB. Double internal mammary-coronary artery bypass. *Arch Surg*. 1974;109(5):627-30.
48. Shrager JB. The Vineberg procedure: the immediate forerunner of coronary artery bypass grafting. *Ann Thorac Surg*. 1994;57(5):1354-64.
49. Suzuki A, Kay EB, Hardy JD. Direct anastomosis of the bilateral internal mammary artery to the distal coronary artery, without a magnifier, for severe diffuse coronary atherosclerosis. *Circulation*. 1973;48(1 Suppl):III190-7.
50. Ancalmo N, Ochsner JL. A modified sternal retractor. *Ann Thorac Surg*. 1976;21(2):174.
51. Flemma RJ, Singh HM, Tector AJ, Lepley D, Frazier BL. Comparative hemodynamic properties of vein and mammary artery in coronary bypass operations. *Ann Thorac Surg*. 1975;20(6):619-27.
52. Rubens FD, Chen L, Bourke M. Assessment of the Association of Bilateral Internal Thoracic Artery Skeletonization and Sternal Wound Infection After Coronary Artery Bypass Grafting. *Ann Thorac Surg*. 2016;101(5):1677-82.
53. Cheng K, Rehman SM, Taggart DP. A review of differing techniques of mammary artery harvesting on sternal perfusion: Time for a randomized study? *Ann Thorac Surg*. 2015;100(5):1942-53.
54. Van den Eynde J, Heeren A, Szelc D, Meuris B, Jacobs S, Verbrugghe P, *et al*. Skeletonisation contributing to a reduction of sternal wound complications: a retrospective study in OPCAB patients. *J Cardiothorac Surg [Internet]*. 2019 [cited 13 Jul 2019];14(1):162. Available at: <https://doi.org/10.1186/s13019-019-0985-9>
55. Hicks GL Jr. Dissection of the internal mammary artery during cephalic vein removal for coronary artery surgery. *Ann Thorac Surg*. 1984;37(1):95.
56. Cosgrove DM, Loop FD. Techniques to maximize mammary artery length. *Ann Thorac Surg*. 1985;40(1):78-9.
57. Keeley SB. The skeletonized internal mammary artery. *Ann Thorac Surg*. 1987;44(3):324-5.
58. Satdhabudha O, Noppawinyoowong N. A randomized comparison of flow characteristics of semiskeletonized and pedicled internal thoracic artery preparations in coronary artery bypass. *J Cardiothorac Surg [Internet]*. 2017 [cited 13 Jul 2019];12(1):28. Available at: <http://doi.org/10.1186/s13019-017-0589-1>
59. Deja MA, Gołba KS, Malinowski M, Woś S, Kowalcza M, Biernat J, *et al*. Skeletonization of internal thoracic artery affects its innervation and reactivity. *Eur J Cardiothorac Surg*. 2005;28(4):551-7.
60. Hu X, Zhao Q. Skeletonized internal thoracic artery harvest improves prognosis in high-risk population after coronary artery bypass surgery for good quality grafts. *Ann Thorac Surg*. 2011;92(1):48-58.
61. Massey RM, Warren OJ, Szczeklik M, Wallace S, Leff DR, Kokotsakis J, Darzi A, Athanasiou T. Skeletonization of radial and gastroepiploic conduits in coronary artery bypass surgery. *J Cardiothorac Surg [Internet]*. 2007 [cited 13 Jul 2019];2:26. Available at: <http://doi.org/10.1186/1749-8090-2-26>
62. Dos Santos Filho EC, Moraes Neto FR, Silva RA, Moraes CR. Should the diabetics have the internal thoracic artery skeletonized? Assessment of sternal perfusion by scintillography. *Rev Bras Cir Cardiovasc*. 2009;24(2):157-64.
63. Boodhwani M, Lam BK, Nathan HJ, Mesana TG, Ruel M, Zeng W, *et al*. Skeletonized internal thoracic artery harvest reduces pain and dysesthesia and improves sternal perfusion after coronary artery bypass surgery: a randomized, double-blind, within-patient comparison. *Circulation*. 2006;114(8):766-73.
64. Gao YJ, Zeng ZH, Teoh K, Sharma AM, Abouzahr L, Cybulsky I, *et al*. Perivascular adipose tissue modulates vascular function in the human internal thoracic artery. *J Thorac Cardiovasc Surg*. 2005;130(4):1130-6.
65. Wendler O, Tscholl D, Huang Q, Schäfers HJ. Free flow capacity of skeletonized versus pedicled internal thoracic artery grafts in coronary artery bypass grafts. *Eur J Cardiothorac Surg*. 1999;15(3):247-50.
66. Athanasiou T, Crossman MC, Asimakopoulos G, Cherian A, Weerasinghe A, Glenville B, *et al*. Should the internal thoracic artery be skeletonized? *Ann Thorac Surg*. 2004;77(6):2238-46.
67. Huang Q, Wendler O, Langer F, Tscholl D, Schäfers HJ. Effects of skeletonized versus pedicled internal thoracic artery grafts on free flow capaci-

- ty during bypass. *J Tongji Med Univ.* 2000;20(4): 308-10.
68. Sauvage LR, Wu HD, Kowalsky TE, Davis CC, Smith JC, Rittenhouse EA, *et al.* Healing basis and surgical techniques for complete revascularization of the left ventricle using only the internal mammary arteries. *Ann Thorac Surg.* 1986;42(4): 449-65.
  69. Raja SG, Dreyfus GD. Internal thoracic artery: to skeletonize or not to skeletonize? *Ann Thorac Surg.* 2005;79(5):1805-11.
  70. Cunningham JM, Gharavi MA, Fardin R, Meek RA. Considerations in the skeletonization technique of internal thoracic artery dissection. *Ann Thorac Surg.* 1992;54(5):947-50; Discussion 951.
  71. Bonini RC, Staico R, Issa M, Arnoni AS, Chacur P, Abdulmassih Neto C, *et al.* Effects of skeletonized versus pedicled radial artery on postoperative graft patency and flow. *Arq Bras Cardiol.* 2014;102(5):441-8.
  72. Cunningham JM. Skeletonization of the internal thoracic artery: pros and cons. *Ann Thorac Surg.* 2006;81(1):405-6.
  73. Horii T, Suma H. Semiskeletonization of internal thoracic artery: alternative harvest technique. *Ann Thorac Surg.* 1997;63(3):867-8.
  74. Kara KA. Bilateral semi-skeletonized IMA; Less thermal injury, easier to harvest, early post operative comparison with single IMA patients after CABG. *Am J Clin Exp Med.* 2018;6(5):107-12.
  75. Hrapkowicz T, Bisleri G. Endoscopic harvesting of the left internal mammary artery. *Ann Cardiothorac Surg.* 2013;2(4):565-9.
  76. Ishikawa N, Watanabe G. Ultra-minimally invasive cardiac surgery: robotic surgery and awake CABG. *Surg Today.* 2015;45(1):1-7.
  77. Bharadwaj P, Luthra M. Coronary artery revascularisation: Past, present and future. *Med J Armed Forces India.* 2008;64(2):154-7.
  78. Ohira S, Doi K, Numata S, Yamazaki S, Yamamoto T, Yaku H. Reskeletonization of patent graft using ultrasonic scalpel in redo surgery. *Ann Thorac Surg [Internet].* 2014 [cited 15 Jul 2019];98(6):e153-5. Available at: <https://doi.org/10.1016/j.athoracsur.2014.09.060>
  79. Bonatti J, Vento A, Bonaros N, Traina M, Lehr E. Robotic totally endoscopic coronary artery bypass grafting (TECAB)-placement of bilateral internal mammary arteries to the left ventricle. *Ann Cardiothorac Surg.* 2016;5(6):589-92.
  80. Gao C, Yang M. Robotic Coronary Bypass Graft on Beating Heart. In: Gao C, editor. *Robotic Cardiac Surgery.* Dordrecht: Springer; 2014. p. 111-33.
  81. Gao C. Overview of Robotic Cardiac Surgery. In: Gao C, editor. *Robotic Cardiac Surgery.* Dordrecht: Springer; 2014. p. 1-14.
  82. Nifong LW, Chitwood WR Jr. Building a Cardiac Surgical Robotic Program. In: Chitwood WR Jr., editor. *Atlas of Robotic Cardiac Surgery.* London: Springer-Verlag; 2014. p. 17-22.
  83. Casula RP, Athanasiou T. Robotic Coronary Revascularisation. In: Inderbitzi RGC, Schmid RA, Melfi FMA, Casula RP, editores. *Minimally Invasive Thoracic and Cardiac Surgery Textbook and Atlas.* Berlin: Springer; 2012. p. 485-97.
  84. Higami T, Kozawa S, Asada T, Shida T, Ogawa K. Skeletonization and harvest of the internal thoracic artery with an ultrasonic scalpel. *Ann Thorac Surg.* 2000;70(1):307-8.
  85. González Jiménez JN. Cirugía cardiovascular y trasplantología. Apuntes históricos. La Habana: ECIMED; 2012.
  86. Bejerano Gil NC, Abdo Cuza AA. Lic. Oralía González Castillero, pionera de la enfermería intensiva en Cuba. *Rev Cuban Med Int Emerg [Internet].* 2018 [cited 15 Jul 2019];17(3). Available at: [http://www.revmie.sld.cu/index.php/mie/artic le/view/494/pdf\\_99](http://www.revmie.sld.cu/index.php/mie/artic le/view/494/pdf_99)
  87. Nafeh Abi-Rezk M, Hernández Núñez R, Carballo Hidalgo N, Villar Inclan A, Guevara González L, Chaos González N, et al. Resultados de la revascularización coronaria en el Cardiocentro del Hospital «Hermanos Ameijeiras», en un período de 20 años. *Rev Cuba Cir [Internet].* 2011 [cited 15 Jul 2019];50(1):54-72. Available at: <http://scielo.sld.cu/pdf/cir/v50n1/cir05111.pdf>
  88. Rodríguez Oliva N, Apolinaire Pennini JJ, Alegret Rodríguez M, Moreno-Martínez FL. Sobrevida de pacientes sometidos a revascularización miocárdica quirúrgica. *CorSalud [Internet].* 2009 [cited 15 Jul 2019];1(1). Available at: <http://www.corsalud.sld.cu/sumario/2009/v1n1a09/sobrevida.htm>
  89. Departamento de Estadística. Registro de Intervenciones Quirúrgicas. Santa Clara: Cardiocentro Ernesto Che Guevara; 1988.
  90. Bernardo Fernández C, Martínez Núñez JO, Castillo Martínez JM, Machín Rodríguez JC, Mamani Huarachi VH. Caracterización clínicoquirúrgica de los pacientes operados de revascularización coronaria. *MEDISAN [Internet].* 2005 [cited 16 Jul 2019];9(1). Available at: <http://www.redalyc.org/articulo.oa?id=368445007008>

91. Rodulfo García M, Torralbas Reverón FE, Martín Torres RA. Revascularización coronaria quirúrgica en pacientes con angina inestable aguda. MEDISAN [Internet]. 2015 [cited 16 Jul 2019];19(1):41-8. Available at: [http://www.medisan.sld.cu/index.php/san/article/view/37/pdf\\_6](http://www.medisan.sld.cu/index.php/san/article/view/37/pdf_6)
92. Lagomasino Hidalgo A, Vázquez Roque J, Dueñas Fernández R, Vergara Hidalgo M. Injertos múltiples de arteria mamaria interna en la revascularización miocárdica. Medicentro [Internet]. 1997 [cited 16 Jul 2019];1(2). Available at: <http://www.medicentro.sld.cu/index.php/medicentro/article/view/11/11>
93. Nafeh Abi-Rezk M, González Jiménez N. Revascularización Miocárdica: Resultados de la aplicación de un protocolo asistencial en el Hospital Hermanos Ameijeiras. La Habana: Editorial Universitaria; 2015.
94. Vázquez-Roque FJ, Medrano-Plana Y, Chaljub Bravo E, Bermúdez-Yera R, Fuentes-Herrera L, Moré-Duartes A, *et al.* Alternativas para lograr la revascularización arterial total usando una o ambas arterias mamarias y el remanente distal de una de ellas como únicos injertos. Rev Colomb Cardiol. 2016;23(2):128-40.
95. Jayakumar S, Gasparini M, Treasure T, Burdett C; Cardiothoracic Trainees Research Collaborative. How do surgeons decide? Conduit choice in coronary artery bypass graft surgery in the UK. Interact Cardiovasc Thorac Surg. 2019;29(2):179-86.