

Emergency endovascular stent graft implantation for acute traumatic DeBakey type III aortic dissection

Ferhat Borulu^{ID}, Assist Prof, MD; and Bilgehan Erku^{✉ ID}, Prof, MD

Atatürk University, Medical Faculty, Department of Cardiovascular Surgery, Erzurum-Turkey.

Este artículo también está disponible en español

ARTICLE INFORMATION

Received: December 6, 2020
Accepted: January 18, 2021

Competing interests

The authors declare no competing interests.

Figures

Diagnostic and therapeutic images are shown with patient's consent.

ABSTRACT

The applications of thoracic aorta pathologies with a stent graft percutaneously have been performed for the first time since the beginning of the 20th century. Computed tomography was performed on a 79-year-old patient who was brought to the emergency room due to an in-vehicle traffic accident with severe back pain, and DeBakey type III aortic dissection was determined. An endovascular self-expanding nitinol stent (Talent Stent Graft, Medtronic) was implanted in the descending aorta where the dissected segment begins. Stent graft implantation is an effective method in preventing organ ischemia and rupture in traumatic aortic pathologies. This procedure is less invasive and has less complication than surgical approach. It is effective in providing blood flow quickly and safely.

Keywords: Aortic dissection, DeBakey type III aortic dissection, Traumatic aortic pathology, Diagnostic imaging, Self-expandable metallic stents

Implantación endovascular urgente de stent en disección aórtica aguda tipo III de DeBakey

RESUMEN

El tratamiento de las enfermedades de la aorta torácica con la implantación percutánea de stent se viene realizando desde su aplicación, por primera vez, a principios del siglo XX. Se presenta un paciente de 79 años de edad que fue llevado a urgencias con intenso dolor de espalda posterior a un accidente automovilístico, a quien se le realizó tomografía computarizada y se le diagnosticó una disección aórtica tipo III de DeBakey. Se le implantó un stent endovascular autoexpandible de nitinol (Talent Stent Graft, Medtronic) en la aorta descendente, donde comenzaba el segmento disecado. Este procedimiento es un método eficaz para prevenir la isquemia de órganos y la ruptura vascular en las enfermedades traumáticas de la aorta. Es menos invasivo, tiene menos complicaciones que el tratamiento quirúrgico, y es efectivo para restituir el flujo sanguíneo de forma rápida y segura.

Palabras clave: Disección aórtica, Disección aórtica tipo III de DeBakey, Lesiones traumáticas de la aorta, Diagnóstico por imagen, Stents metálicos autoexpandibles

INTRODUCTION

Thoracic aortic dissections are divided into Stanford type A (DeBakey Type I or II; arising from the ascending aorta) and Stanford type B (DeBakey Type III; originating distal to the left subclavian artery) according to their origin¹. Thirty to thirty five percent of acute dissections are seen in the

✉ B Erku, Prof, MD

Atatürk University Medical Faculty
Department of Cardiovascular
Surgery, Erzurum, Turkey.
E-mail address:
bilgehanerkut@yahoo.com

descending aorta. Hypertension, atherosclerosis, aortic connective tissue diseases and trauma are the most important causes for aortic dissections. Traumatic injuries of the thoracic aorta associated with traffic accidents can be seen frequently, and the rate of reaching the hospital alive with this pathology is between 10-20%^{1,2}.

Before the invention of percutaneous stent graft implantation technique, graft replacement with standard surgery was the treatment of choice. However, the morbidity and mortality rates were quite high with the standard open surgical method. In acute traumatic aortic dissections, the difficulties in protecting the heart, brain, kidney, lung and spinal cord during graft replacement and mortality rates between 15-60% have brought endovascular treatment into the agenda^{2,3}.

Endovascular treatment is often recommended in patients with DeBakey type III acute traumatic dissection, if there is a good general condition, limited antegrade dissection, and in cases that do not respond to medical treatment. It has been reported that this treatment is effective in preventing proximal and distal extension of dissection, rupture and aneurysm formation^{4,5}.

In this article, we present successful endovascular treatment in a patient who developed DeBakey type III aortic dissection due to blunt trauma following a traffic accident.

CASE REPORT

A 79-year-old male patient had severe back pain when he was brought to the emergency room due to a traffic accident. The patient was hemodynamically stable. Other system examinations and consultations were evaluated as normal. All extremity pulses were palpable.

The back pain of the patient—who was followed up in the emergency department—, started to get worse. It was decided to perform contrast-enhanced

computed tomography to rule out any pulmonary or vascular pathology. Computed tomography was performed after the patient was slightly sedated. On contrast-enhanced computed tomography, DeBakey type III aortic dissection was detected starting just distal to the left subclavian artery and including the iliac arteries (**Figure 1**). There was no rupture or aneurysm associated with dissection.

Due to the aggravation of back pain and the risk of rupture, it was decided to apply a percutaneous stent graft to the patient. The patient was admitted to the intensive care unit of our clinic. Then, he was urgently taken to the hybrid operating room. The procedure was performed in an hybrid operating room by a team of vascular surgeons and interventional radiologists, using general anesthesia administered by tracheal intubation and mechanical ventilation.

The patient was supine, and the thorax, abdomen, and pelvis were prepared in a sterile manner for femoral arteriotomy and also for possible conversion to a surgical emergency intervention, if nec-

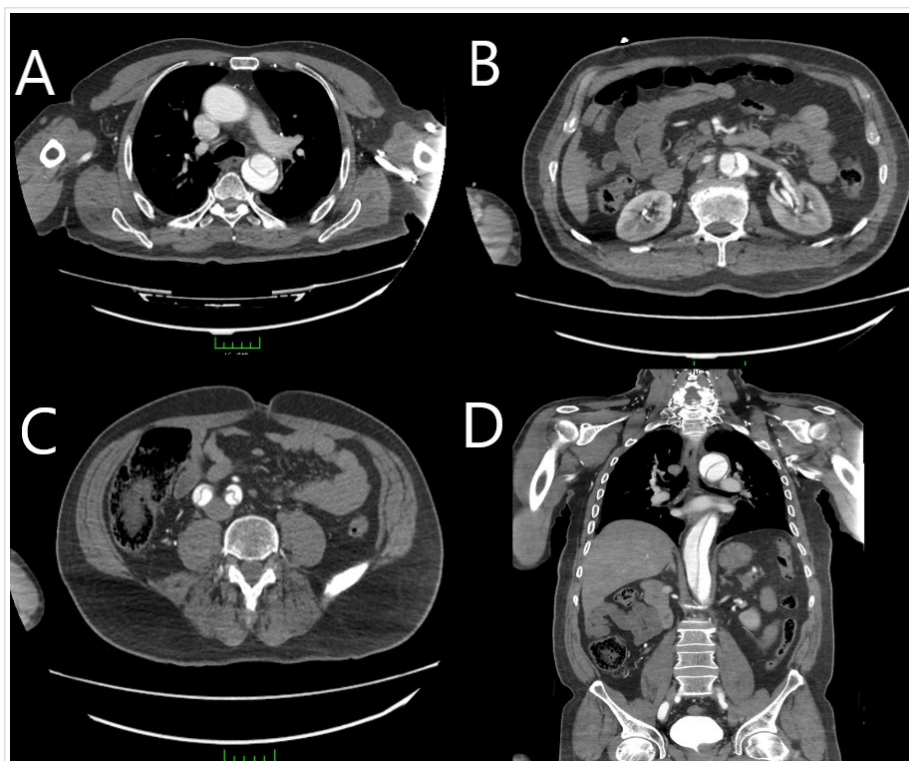


Figure 1. Image showing the descending aortic dissection (A), abdominal aortic dissection (B), and dissection in the bilateral iliac arteries (C), on transverse sections of thoracoabdominal contrast computed tomography. D. Preoperatively contrast-enhanced thoracoabdominal tomography shows dissection flap in descending aorta on sagittal sections.

essary. Heparin was administered with an activated clotting time of 250 seconds. Femoral artery was explored and returned with separate tape, which was followed by a transverse arteriotomy at the site in which the stent-graft was inserted. Aortography was performed and the location of the dissection, the location of the left subclavian artery and renal arteries were determined. During deployment, systolic blood pressure was titrated to less than 70 mm Hg by infusion of a glyceryl trinitrate solution to ensure precise positioning and prevent downward migration of the graft. The upper and lower ends of the region of stent-graft placement were marked with angiographic guidance. Next, the delivery system was introduced and positioned at the proximal end of the aortic abnormality.

A 120 × 38 (proximal) - 36 (distal) mm endoluminal stent-graft (Talent, Medtronic), consisting of a self-expanding nitinol exoskeleton lined with monofilament polyester on the inner surface, was placed on a stiff guidewire and placed in such a way that it

completely covers the origin of the left subclavian artery (**Figure 2A**). The stent graft was advanced up to the aortic arch (beginning of the left carotid artery). Although the stent graft occludes the origin of the subclavian artery, there was pulsation in the left arm after the procedure and there were no ischemic findings in the left arm. After insertion, the proximal entrance and tear were completely closed after the mid-level balloon was inflated to fully attach the stent graft to the wall. A repeat aortography was performed and no leakage was observed. The general condition of the patient was stable after the procedure. All extremity pulses were present and the patient's back pain was reduced. There were no paraplegic symptoms. The patient's postoperative period was uneventful. The patient was discharged on the 10th postoperative day with low molecular weight heparin and 100 mg aspirin therapy. Endovascular leakage and migration were not detected in the contrast-enhanced spiral tomography at the end of the first month (**Figure 2B-D**).

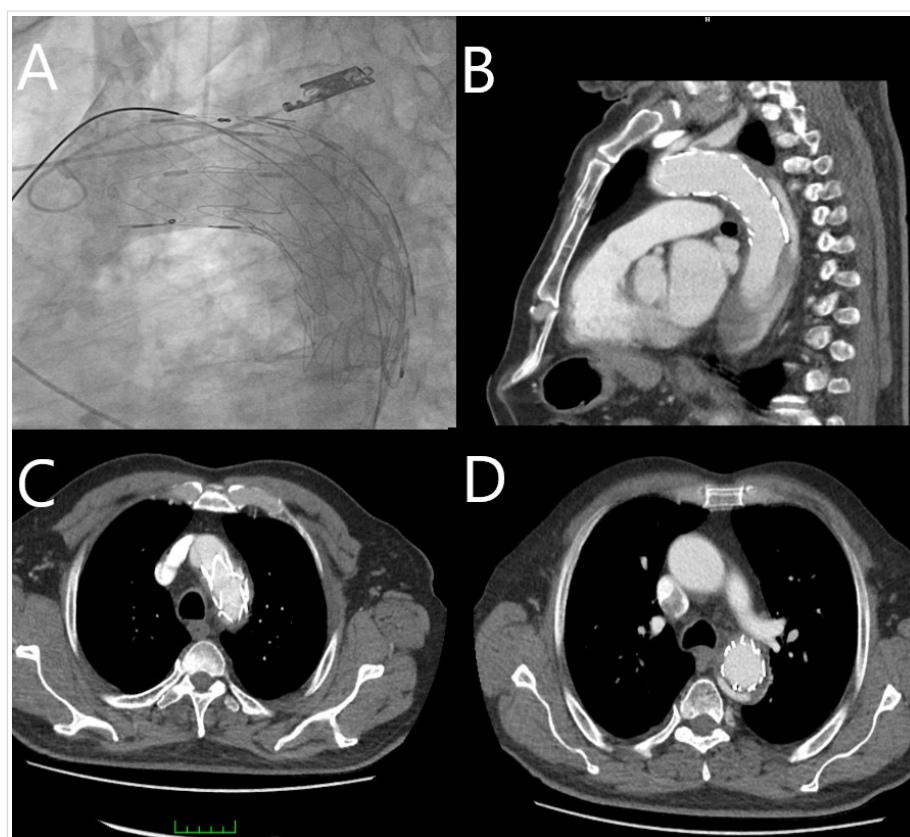


Figure 2. A. Angiographic picture shows stent graft placement in the patient with type III aortic dissection. B-D. Images showing the absence of dissection and leakage after endovascular stent graft in contrast-enhanced spiral thoracoabdominal tomography taken one month after implantation.

COMMENT

Acute aortic dissection is a catastrophic event and lethal condition. Mortality remains high with life threatened by tamponade, coronary or cerebral malperfusion, aortic rupture, and/or organ ischemia. Traditionally, emergency surgery is preferred for Stanford A or DeBakey Type I-II aortic dissections, and medical treatment is preferred for Stanford B or DeBakey Type III aortic dissections. In the past, the traditional treatment was conservative treatment which usually accompanied by a series of problems, and surgical repair, however, usually associated with high mortality and considerable postoperative morbidity.

Surgical or interventional repair in DeBakey type III dissection is advocated only for specific cases complicated by progression, formation of expansive aneurysms, critical

malperfusion syndrome, or impending rupture heralded by contained or profuse bleeding. In such patients, since the placement of covered stent for treatment of aortic injury was introduced, many studies have been published to demonstrate the safety and efficacy of endovascular procedure for acute aortic diseases, and some cases of traumatic aorta rupture have also been published.

Traumatic tears of the descending aorta are a typical injury that is often seen in high-speed motor vehicle accidents, especially in traffic accidents. The enormous forces created by the rapid deceleration cause overstressing of relatively mobile structures such as the descending aorta⁶. In more than 90% of cases, the aortic dissection is located distal to the origin of the left subclavian artery. Since the ligamentum arteriosum in this region fixes the aorta, it can be directly affected by any trauma⁷. Mortality rates in the first hours of these patients are over 90%. Only a rapid diagnosis and an immediate treatment can improve this poor prognosis. Even if they reach the hospital alive, their mortality rate remains high. Blood loss due to rupture in surviving patients is avoided due to adventitia, parietal pleura or other mediastinal tissues^{7,8}.

Until very recently, surgical treatment with open repair was the only possible treatment option for traumatic DeBakey type III aortic dissections. In addition to the complications associated with open surgery, the patient's existing spinal cord injuries, head trauma, internal organ damage and lung damage also increase surgical morbidity and mortality (9). In addition to the risks present in open surgery, the aortic cross clamp used not only reduces the perfusion of different end organs such as the spinal cord, bowel and kidneys, but also increases intracranial pressure. This situation may increase morbidity and mortality in patients with head trauma. This may increase the morbidity associated with open surgery. The surgical mortality of DeBakey type III aortic dissections has been reported to be 50-60%¹⁰. Despite the technical and medical developments in the surgical field, the risk of mortality still remains important. However, the developments in endovascular treatment in the last decade have started to give positive results in this regard. Basically, the neurological complication rate of endovascular therapy is very low compared to surgical treatment. Over the years, it has been observed that the rates of paraplegia resulting from stent graft implantations in aortic injuries and / or aortic aneurysms

vary between 3-9% in the Meta-analyzes and articles presented^{11,12}. In our case, there was no paraplegic condition in the patient before the procedure. In the examination performed after the procedure, there was no plegic condition showing neurological damage.

In addition to an experienced vascular surgery team, adequate radiology and anesthesia coordination is needed in hospitals where emergency endovascular treatment will be performed. The hybrid operating room to be operated should be equipped with surgical-interventional equipment and adequate devices for invasive imaging. Because during endovascular treatment, problems such as graft migration, endovascular leakage, iliac artery rupture, microembolization, torsion and obstruction in the graft leg may develop, which may require endovascular methods. In addition, adequate anesthetics and equipment should be available for complications that can be switched to emergency open surgery. Contrast agent nephrotoxicity, allergy, and mechanical problems (such as inability to graft, improper placement) can be seen during endovascular treatment. However, endovascular treatment is a short procedure time, short graft; low morbidity, mortality, and paraplegia rates; short intensive care period; It has advantages such as low cerebral, renal and respiratory complication rates.

CONCLUSIONS

Morbidity and mortality rates are quite high in all aortic dissections, especially acute forms. If trauma is the cause in these patients, the current morbidity and mortality rates increase even more. If DeBakey type III or descending aortic dissections occur on a traumatic ground, it has been observed that the patient morbidity (paraplegia risk) and mortality rates are quite high in open surgery applications in these patients because of hemodynamically unstable. Endovascular treatment is considered an effective treatment option in thoracic aortic dissections. Although there are debates about when to apply in more complicated injuries (in cases of hemodynamic instability), we believe that the application should be performed without delay in isolated aortic injuries like our case. Treatment of traumatic DeBakey type III aortic dissection by endovascular implantation of stent graft is technical possible, besides, it is remarkably safe and effective.

REFERENCES

1. Cornwell EE, Kennedy F, Berne TV, Asensio JA, Demetriades D. Gunshot wounds to the thoracic aorta in the '90s: only prevention will make a difference. *Am Surg.* 1995;61(8):721-3.
2. Soyer R, Bessou JP, Bouchart F, Tabley A, Mouton-Schleifer D, Arrignon J, *et al.* Acute traumatic isthmic aortic rupture. Long-term results in 49 patients. *Eur J Cardiothorac Surg.* 1992;6(8):431-6. [DOI]
3. Glock Y, Roux D, Soula P, Cerene A, Fournial G. Roturas traumáticas de la aorta torácica. *Rev Esp Cardiol.* 1996;49(Suppl 4):100-6.
4. Svensson LG, Crawford ES, Hess KR, Coselli JS, Safi HJ. Dissection of the aorta and dissecting aortic aneurysms. Improving early and long-term surgical results. *Circulation.* 1990;82(5 Suppl):24-38.
5. Islamoglu F. Torasik aort hastalıklarında endovasküler tedavi. En: Paç M, Akçevin A, Aka SA, Buket S, Sarioğlu T, editörler. *Kalp ve damar cerrahisi.* Cilt 1. Ankara: MN Medikal & Nobel; 2004. p. 1035-39.
6. Shkrum MJ, McClafferty KJ, Green RN, Nowak ES, Young JG. Mechanisms of aortic injury in fatalities occurring in motor vehicle collisions. *J Forensic Sci.* 1999;44(1):44-56.
7. Lorenzen HP, Geist V, Hartmann F, Sievers H, Richardt G. Endovascular stent-graft implantation in acute traumatic aortic dissection with contained rupture and hemorrhagic shock. *Z Kardiol.* 2004;93(4):317-21. [DOI]
8. Kalmár P, Püschel K, Stubbe HM, Gültekin E. Delayed surgical therapy of acute aortic rupture. *Zentralbl Chir.* 1996;121(9):750-5.
9. Orford VP, Atkinson NR, Thomson K, Milne PY, Campbell WA, Roberts A, *et al.* Blunt traumatic aortic transection: The endovascular experience. *Ann Thorac Surg.* 2003;75(1):106-12. [DOI]
10. Doss M, Balzer J, Martens S, Wood JP, Wimmer-Greinecker G, Fieguth HG, *et al.* Surgical versus endovascular treatment of acute thoracic aortic rupture: a single-center experience. *Ann Thorac Surg.* 2003;76(5):1465-9. [DOI]
11. von Oppell UO, Dunne TT, De Groot MK, Zilla P. Traumatic aortic rupture: twenty-year metaanalysis of mortality and risk of paraplegia. *Ann Thorac Surg.* 1994;58(2):585-93. [DOI]
12. Mitchell RS, Miller DC, Dake MD, Semba CP, Moore KA, Sakai T. Thoracic aortic aneurysm repair with an endovascular stent graft: the "first generation". *Ann Thorac Surg.* 1999;67(6):1971-4. [DOI]